九州大学学術情報リポジトリ
Kyushu University Institutional Repository

Sex determination based on a thoracic vertebra and ribs evaluation using clinical chest radiography

Tsubaki, Shun
Department of Health Sciences, Graduate School of Medical Sciences, Kyushu University

Morishita, Junji
Department of Health Sciences, Faculty of Medical Sciences, Kyushu University

Usumoto, Yosuke
Department of Legal Medicine, Yokohama City University Graduate School of Medicine

Sakaguchi, Kyoko
Department of Radiology, Kinki University Hospital

他

https://hdl.handle.net/2324/6791135

出版情報：Legal Medicine. 27, pp.19-24, 2017-07. Elsevier B.V.
バージョン：
権利関係：

KYUSHU UNIVERSITY

Title: Sex determination based on a thoracic vertebra and ribs evaluation using clinical chest radiography

Highlights

・Sex determination was conducted by combined features of a thoracic vertebra and ribs.
・Accuracies of sex determination were evaluated by stepwise discriminant analysis.
・The accuracy was 88.8% (533/600) by combining information obtained from these bones.
・A thoracic vertebra and ribs could help to determine sex in forensic medicine.

Abstract

Our aim was to investigate whether sex can be determined from a combination of geometric features obtained from the 10th thoracic vertebra, 6th rib, and 7th rib. Six hundred chest radiographs (300 males and 300 females) were randomly selected to include patients of six age groups (20s, 30s, 40s, 50s, 60s, and 70s). Each group included 100 images (50 males and 50 females). A total of 14 features, including 7 lengths, 5 indices for the vertebra, and 2 types of widths for ribs, were utilized and analyzed for sex determination. Dominant features contributing to sex determination were selected by stepwise discriminant analysis after checking the variance inflation factors for multicollinearity. The accuracy of sex determination using a combination of the vertebra and ribs was evaluated from the selected features by the stepwise discriminant analysis. The accuracies in each age group were also evaluated in this study. The accuracy of sex determination based on a combination of features of the vertebra and ribs was 88.8% (533/600). This performance was superior to that of the vertebra or ribs only. Moreover, sex determination of subjects in their 20s demonstrated the highest accuracy (96.0%, 96/100). The features selected in the stepwise discriminant analysis included some features in both the vertebra and ribs. These results indicate the usefulness of combined information obtained from the vertebra and ribs for sex determination. We conclude that a combination of geometric characteristics obtained from the vertebra and ribs could be useful for determining sex.

Keywords

Forensic anthropology; Sex determination; Thoracic vertebra; Rib; Clinical chest radiography

1. Introduction

Shape and size of the skull, pelvis, and humerus have often been used for sex determination in forensic medicine [1–8]. However, skeletal bones are not always complete in forensic cases due to conditions within the burial environment, and only parts of bones are found occasionally [9]. In such cases, it is desirable to discriminate personal information, such as age, height, and sex, from the bones available. Some reports have shown that features of vertebrae and ribs, including the 1st and 2nd cervical vertebrae, 12th thoracic vertebra, all lumbar vertebrae, and the 1st and 4th ribs, could be useful for sex determination [9–18]. On the other hand, no study has reported whether sex can be determined from a combination of anatomical information extracted from a thoracic vertebra and ribs.

Our study focuses on evaluation of chest radiography (hereafter referred to as chest image), the most common examination performed at many hospitals and medical centers. It is easy to collect a large number of clinical chest images. We attempted to determine sex in a Japanese population by using clinical chest images. The hypothesis of this study is that size and shape of a bone may not be changed by death. Although previous studies have used computed tomography (CT) images for sex determination [3–5, 12–14, 16, 17], chest images are thought to be potentially useful since they can be reconstructed from three-dimensional CT data. Our aim is to examine whether sex can be determined from geometric information obtained from large numbers of thoracic vertebrae and ribs in various age groups.

2. Materials and Methods

All chest images in our database were obtained using a computed radiographic system (FUJIFILM Medical Corporation, Tokyo, Japan) at the lung cancer screening program in Iwate Prefecture, Japan [19]. The matrix size and pixel size of the images were 512 × 512 and 0.69 mm, respectively. Six hundred normal chest images were randomly selected from our database and included images from patients of six age groups (20s, 30s, 40s, 50s, 60s, and 70s). Each group included 100 images (50 males and 50 females).

We used the 10th thoracic vertebra, 6th rib, and 7th rib for sex determination. Visual assessment of the 10th thoracic vertebra was easy due to the low overlap with the trachea or diaphragm compared to other vertebrae. In addition, the lower thoracic vertebrae are often preserved well in archaeological skeletal assemblages and forensic contexts due to their weight-bearing function and relative density [13]. Measurement of the rib widths was also easy due to the low overlap with the clavicle or diaphragm. Moreover, these anatomical structures were less affected by geometric distortion and magnification owing to their close proximity to the center of the X-rays during chest imaging.

Image processing was performed to facilitate visualization of the measurements of the vertebra lengths as shown in **Fig. 1**. A total of 14 indices were used in this study. Twelve among 14 indices were obtained from the 10th thoracic vertebra on a chest radiograph (**Fig. 2)**. Seven linear measurements of the vertebra were performed on chest images displayed on an electronic display device using an image processing software (ImageJ, National Institutes of Health, USA). Then, 4 ratios and an area were obtained from the 7 measurements. **Figure 3** shows a procedure to measure the widths of the 6th and 7th ribs on a chest image. The reproducibility of these measurements appears to be substantial (interclass correlation coefficient, r = 0.803) [20].

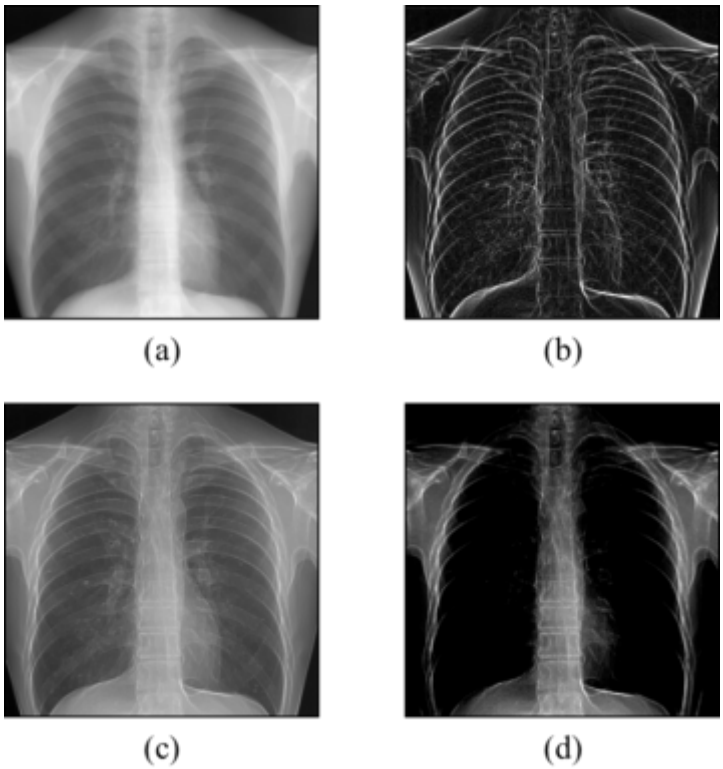

Fig. 1 Examples of image pre-processing for measurements of widths, heights, and diagonal lengths of the 10th thoracic vertebra on a chest radiograph. (a) original chest image; (b) edge-enhanced image using Sobel filter; (c) sharpened image by adding (b) to (a); (d) sharpened image after adjustment of the window width and level. On the other hand, no pre-processing has been done for measurement of the widths of the 6th and 7th ribs.



Fig. 2 Measurement sites and various indices of the 10th thoracic vertebra on a chest radiograph for sex determination. The average of two diagonal lengths was used for the diagonal (7).

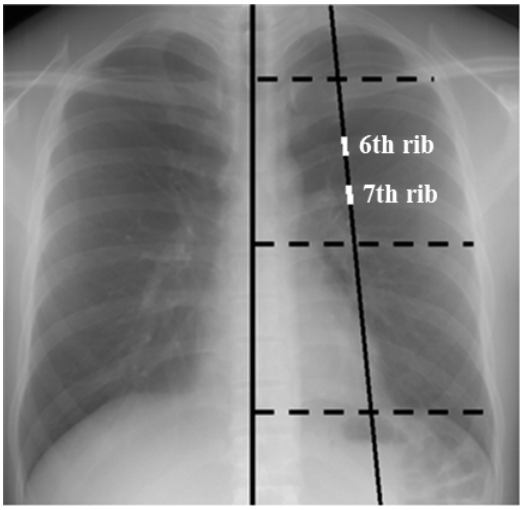

Fig. 3 Determination of location for measurements of the 6th and 7th ribs. Three dotted lines were horizontally set at the beginning of the clavicle, central region of the lung, and bottom of the lung, and a solid line was then drawn through each midpoint of the three dotted lines for determination of measurement criteria. The widths of the ribs on the solid line were measured.

Sex determination was performed as follows. First, a Student's t-test was applied for comparison of male and female at each index. Differences between the sexes were considered statistically significant when p values were less than 0.05. If the index showed statistically significant difference, accuracy of sex determination was evaluated by using a linear discriminant analysis (LDA). Second, the accuracies in all age groups were evaluated by using a stepwise discriminant analysis for (1) a thoracic vertebra, (2) ribs, and (3) the combination of both as shown in **Fig. 4**. A stepwise discriminant analysis is a statistical method to select effective variables

contributing to discrimination. We sought to distinguish male from female by means of discriminant equations obtained from the analysis. Multicollinearity of various features was checked by the variance inflation factor (VIF) before applying the stepwise discriminant analysis. The VIF indicates how a variable can be predicted by another one. A VIF value of 10 or more indicates multicollinearity in the data. Finally, the accuracies in each age group were also evaluated by applying the stepwise discriminant analysis. All statistical analyses were executed by using JMP® 11 (SAS Institute Inc., Cary, NC, USA) and R version 3.2.2 (R Foundation for Statistical Computing, Vienna, Austria).

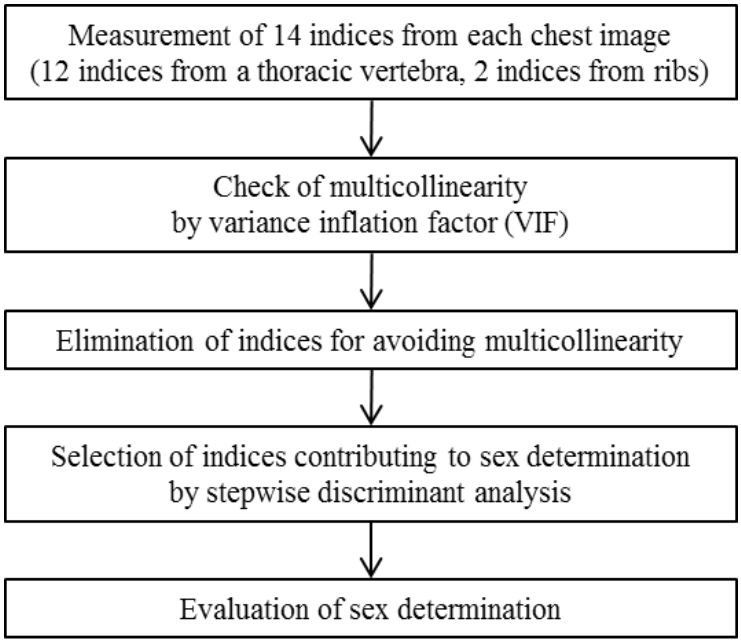

Fig. 4 Flowchart for sex determination based on a stepwise discriminant analysis.

3. Results

Table 1 shows the descriptive statistics for 14 indices and accuracies of sex determination by using the linear discriminant analysis (LDA) for the indices that demonstrated significant differences. Ten indices in males, except for X_{middle}/X_{upper}, X_{middle}/X_{lower}, Y_{center}/Y_{left}, and Y_{center}/Y_{right}, were significantly higher than those in females. If we use $X_{middle} \cdot Y_{center}$, an index corresponding to the area of the vertebra, the accuracy of sex determination was the highest, with 85.0% (510/600). In contrast, if we use Y_{center} or Y_{right}, the accuracy was the lowest, with 75.7% (454/600).

Table 1 The descriptive statistics of each index used in this study and the accuracies of sex determination by using a linear discriminant analysis (LDA) for the indices that demonstrated significant differences.

Indices	Male		Female		p	Accuracies of sex determination (%)		
	Mean	SD	Mean	SD		Male	Female	Total
X_{upper}	41.80	3.73	36.56	3.40	<0.001	75.0 (225/300)	80.7 (242/300)	77.8 (467/600)
X_{middle}	39.90	3.38	35.08	2.87	<0.001	77.7 (233/300)	83.3 (250/300)	80.5 (483/600)
X_{lower}	45.59	3.68	39.86	3.23	<0.001	79.3 (238/300)	81.7 (245/300)	80.5 (483/600)
Y_{left}	24.39	1.83	22.14	1.51	<0.001	74.7 (224/300)	78.0 (234/300)	76.3 (458/600)
Y_{center}	24.29	1.76	22.05	1.50	<0.001	72.3 (217/300)	79.0 (237/300)	75.7 (454/600)
Y_{right}	24.51	1.88	22.35	1.93	<0.001	74.7 (224/300)	76.7 (230/300)	75.7 (454/600)
diagonal	49.19	3.31	43.29	3.11	<0.001	81.7 (245/300)	85.7 (257/300)	83.7 (502/600)
X_{middle}/X_{upper}	0.96	0.05	0.96	0.04	0.163			
X_{middle}/X_{lower}	0.88	0.05	0.88	0.04	0.191			
Y_{center}/Y_{left}	1.00	0.03	1.00	0.03	0.963			
Y_{center}/Y_{right}	0.99	0.03	0.99	0.04	0.158			
$X_{middle} \cdot Y_{center}$	970.54	118.83	773.98	86.13	<0.001	81.7 (245/300)	88.3 (265/300)	85.0 (510/600)
6th rib	11.28	1.07	9.39	0.96	<0.001	81.7 (245/300)	82.0 (246/300)	81.8 (491/600)
7th rib	11.88	1.14	10.03	1.06	<0.001	76.7 (230/300)	82.0 (246/300)	79.3 (476/600)

$p < 0.05$ indicates a significant difference

Table 2 shows accuracies of sex determination for all chest images by using a stepwise discriminant analysis in the thoracic vertebra, ribs, and a combination of both. If we only use the thoracic vertebra, five indices (X_{lower}, Y_{left}, X_{middle}/X_{lower}, Y_{center}/Y_{left}, and Y_{center}/Y_{right}) were selected by the analysis. The accuracies of sex determination in males, females, and total subjects were 85.0% (255/300), 88.0% (264/300), and 86.5% (519/600), respectively. On the other hand, if we only use the ribs, the accuracies were lower than those in the vertebra. However, if we use a combination of the vertebra and ribs, six indices (X_{lower}, Y_{left}, Y_{center}/Y_{left}, Y_{center}/Y_{right}, 6th rib, and 7th rib) were selected by the analysis. Finally, the accuracies of sex determination in males, females, and total subjects slightly improved to 87.3% (262/300), 90.3% (271/300), and 88.8% (533/600),

respectively.

Table 2 Accuracies of sex determination using the thoracic vertebra, ribs, and the combination of both obtained from 600 chest images.

Region of interest for analysis	Indices selected by stepwise	Accuracies of sex determination (%)		
		Male	Female	Total
Thoracic vertebra	X_{lower} Y_{left} X_{middle}/X_{lower} Y_{center}/Y_{left} Y_{center}/Y_{right}	85.0 (255/300)	88.0 (264/300)	86.5 (519/600)
Rib	6th posterior rib 7th posterior rib	80.3 (241/300)	83.0 (249/300)	81.7 (490/600)
Combination of thoracic vertebra and ribs	X_{lower} Y_{left} Y_{center}/Y_{left} Y_{center}/Y_{right} 6th posterior rib 7th posterior rib	87.3 (262/300)	90.3 (271/300)	88.8 (533/600)

Table 3 shows the accuracies of sex determination in each age group. Sex determination of subjects in their 20s demonstrated the highest accuracy and 7 indices were selected by the analysis, including X_{upper}, Y_{left}, X_{middle}/X_{upper}, X_{middle}/X_{lower}, Y_{center}/Y_{right}, 6th rib, and 7th rib. The accuracies in male, and female participants, and in all participants were 96.0% (48/50), 96.0% (48/50), and 96.0% (96/100), respectively. These performances were better than those in all 600 chest images as previously described.

Table 3 Accuracies of sex determination in each age group by using a stepwise discriminant analysis.

Age groups	Indices selected by stepwise	Accuracies of sex determination (%)		
		Male	Female	Total
20s	X_{upper}, Y_{left}, X_{middle}/X_{upper}, X_{middle}/X_{lower}, Y_{center}/Y_{right}, 6th rib, 7th rib	96.0 (48/50)	96.0 (48/50)	96.0 (96/100)
30s	X_{upper}, Y_{right}, X_{middle}/X_{upper}, X_{middle}/X_{lower}, Y_{center}/Y_{left}, Y_{center}/Y_{right}, 7th rib	92.0 (46/50)	92.0 (46/50)	92.0 (92/100)
40s	X_{lower}, Y_{left}, 6th rib	88.0 (44/50)	94.0 (47/50)	91.0 (91/100)
50s	X_{lower}, X_{middle}/X_{lower}, Y_{center}/Y_{left}, Y_{center}/Y_{right}, 6th rib, 7th rib	90.0 (45/50)	96.0 (48/50)	93.0 (93/100)
60s	X_{lower}, Y_{left}, Y_{center}/Y_{left}, 6th rib	92.0 (46/50)	90.0 (45/50)	91.0 (91/100)
70s	Y_{center}, X_{middle}/X_{upper}, 6th rib, 7th rib	88.0 (44/50)	88.0 (44/50)	88.0 (88/100)

4. Discussion

Ten out of the 14 indices showed significantly higher values in males than those in females as we expected (**Table 1**). According to a study by Riggs *et.al.*, bone areas of lumbar vertebrae in males were approximately 35% larger than those in females [21]. In the present study, the areas of the thoracic vertebra in males and females were estimated to be 970.5 mm^2 and 774.0 mm^2, respectively. Thus, the areas in males were approximately 25% larger than those in females, which is consistent trend with the results of a previous study [21]. For 4 indices of ratios (X_{middle}/X_{upper}, X_{middle}/X_{lower}, Y_{center}/Y_{left}, and Y_{center}/Y_{right}), there were no significant differences between the sexes as shown in **Table 1**. According to a previous study by Hou *et.al.*, the size of the 12th thoracic vertebra contributes more than the shape in distinguishing the differences of the vertebra between males and females [12]. In this study, there were no significant differences in indices of ratios corresponding to the shape of the 10th thoracic vertebra between the sexes. On the other hand, there were significant differences in all indices of linear lengths related to the size of the vertebra between the sexes. Thus, our results were consistent with the results of the study by Hou *et.al.*

Although rib features showed a minimal contribution to sex determination, our results showed the usefulness of a combination of anatomical information obtained from the thoracic vertebra and ribs. Moreover, indices selected by a stepwise discriminant analysis included some indices of both the vertebra and ribs as shown in **Tables 2** and **3**. Thus, indices of the vertebra and

ribs may have different characteristics that would be useful for sex determination.

As a result of a stepwise discriminant analysis for each age group, the accuracy of sex determination for subjects in their 20s was the highest. Distributions of heights for each age group and percentages of overlapped histograms in Japanese male and female are shown in **Fig. 5**. We generated these figures based on data from The National Health and Nutrition Survey in Japan in 2014 [22]. The percentage for subjects in their 20s is lower than those for subjects in other age groups. A low percentage in overlapped histograms indicates that discrimination between the sexes is much easier, and hence our results would be reasonable.

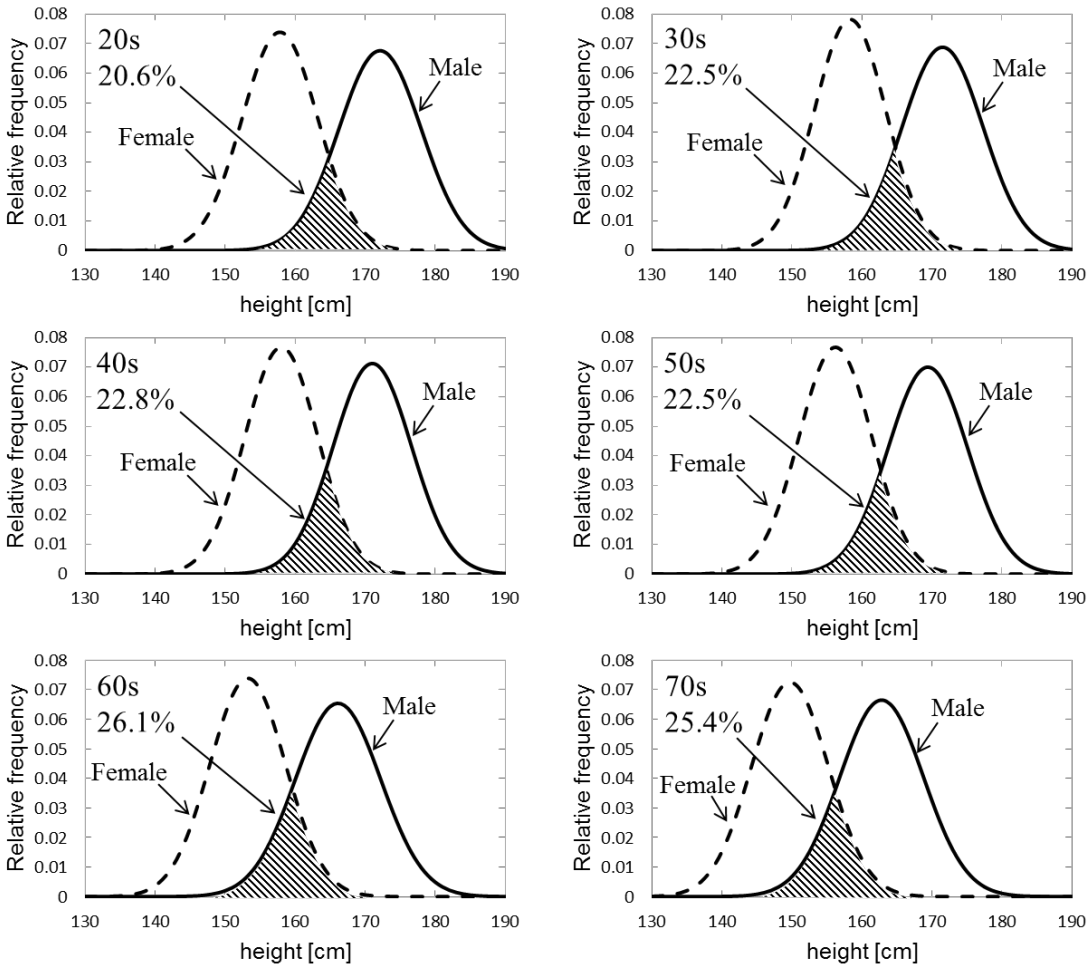

Fig. 5 Distributions of heights for each age group and percentages of overlapped histograms in Japanese male and female.

Our measured indices from the chest images will be influenced by a magnification factor dependent on geometry in chest imaging. Therefore, there may be a slight discrepancy between measurements obtained from chest images and actual lengths [23]. For instance, if the distances

between the focus of an X-ray tube to the vertebra and a detector to the vertebra are 135 cm and 15 cm, respectively, the vertebra is displayed 1.1 times bigger on a chest image due to magnification with radiography. Therefore, we need to consider the effect of magnification to apply our proposed method in practice situations.

We believe that the proposed method described in the study could be useful even if CT scanning is not available. Our method based on two-dimensional images has potential usefulness for sex determination of unknown deceased individuals in forensic medicine and mass disasters, especially in a developing country in which a CT scanner is less common.

Our study has some limitations. First, the chest images used in this study were antemortem and limited in number. Although it is difficult to collect postmortem images, future studies should include a large number of these images. Second, this study is based on only Japanese population. Some reports have shown that sexual dimorphism in bones varies among populations [15, 16, 24]. Thus, the results obtained by our proposed method would be different depending on ethnic group. Third, the widths of ribs may be affected by the measured angle across the rib even if we measure the indices from the same rib. In addition, it is difficult to identify the 6th or 7th rib. Therefore, it is desirable to develop methods for automated identification of number of vertebrae and/or ribs.

5. Conclusion

We conclude that a combination of the vertebra and ribs could be useful for determining sex in cases where only a portion of skeletal remains is found.

Acknowledgments

The authors thank Dr Yasuo Sasaki (Department of Radiology, Iwate Prefectural Central Hospital) for providing all chest images. We also thank faculty members of Department of Forensic Pathology and Sciences, Graduate School of Medical Sciences, Kyushu University and Masayuki Sasaki M.D, Ph.D for their valuable discussions.

Ethical Approval

All procedures in studies involving human participants were performed in accordance with the ethical standards of the institutional and/or national research committee and with the Declaration of Helsinki in 1964 and its later amendments or comparable ethical standards. Also, informed consent was waived for all images included in the database used in this study by the Institutional Review Board.

Conflict of Interest

We have nothing to declare for this study.

References

[1] E. Giles, O. Elliot, Sex Determination by Discriminant Function Analysis of Crania, Am. J. Phys. Anthropol. 21 (1963) 53–68.

[2] T.D. Holland, Sex determination of fragmentary crania by analysis of the cranial base, Am. J. Phys. Anthropol. 70 (1986) 203–8.

[3] T. Kano, S. Oritani, T. Michiue, T. Ishikawa, A.M. Hishmat, N. Sogawa, et al., Postmortem CT morphometry with a proposal of novel parameters for sex discrimination of the mandible using Japanese adult data, Leg. Med. (Tokyo) 17 (2014) 167–171.

[4] Y. Hayashizaki, A. Usui, Y. Hosokai, J. Sakai, M. Funayama, Sex determination of the pelvis using Fourier analysis of postmortem CT images, Forensic Sci. Int. 246 (2015) 122.e1–122.e9.

[5] H. Biwasaka, Y. Aoki, T. Tanijiri, K. Sato, S. Fujita, K. Yoshioka, et al., Analyses of sexual dimorphism of contemporary Japanese using reconstructed three-dimensional CT images - Curvature of the best-fit circle of the greater sciatic notch, Leg. Med. (Tokyo) 11 (2009) S260–S262.

[6] J. Bruzek, A method for visual determination of sex, using the human hip bone, Am. J. Phys. Anthropol. 117 (2002) 157–168.

[7] G. Mall, M. Hubig, a. Büttner, J. Kuznik, R. Penning, M. Graw, Sex determination and estimation of stature from the long bones of the arm, Forensic Sci. Int. 117 (2001) 23–30.

[8] M.Y. İşcan, S.R. Loth, C. a King, D. Shihai, M. Yoshino, Sexual dimorphism in the humerus: a comparative analysis of Chinese, Japanese and Thais., Forensic Sci. Int. 98 (1998) 17–29.

[9] E.J. Marlow, R.F. Pastor, Sex determination using the second cervical vertebra--A test of the method., J. Forensic Sci. 56 (2011) 165–9.

[10] E. a. Marino, Sex estimation using the first cervical vertebra, Am. J. Phys. Anthropol. 97 (1995) 127–133.

[11] I. Gama, D. Navega, E. Cunha, Sex estimation using the second cervical vertebra: a morphometric analysis in a documented Portuguese skeletal sample, Int. J. Legal Med. 129 (2015) 365–372.

[12] W. Bin Hou, K.L. Cheng, S.Y. Tian, Y.Q. Lu, Y.Y. Han, Y. Lai, et al., Metric method for sex determination based on the 12th thoracic vertebra in contemporary north-easterners in China., J. Forensic Leg. Med. 19 (2012) 137–43.

[13] S.B. Yu, U.Y. Lee, D.S. Kwak, Y.W. Ahn, C.Z. Jin, J. Zhao, et al., Determination of sex for the 12th thoracic vertebra by morphometry of three-dimensional reconstructed vertebral models, J. Forensic Sci. 53 (2008) 620–625.

[14] W.X. Zheng, F.B. Cheng, K.L. Cheng, Y. Tian, Y. Lai, W.S. Zhang, et al., Sex assessment using measurements of the first lumbar vertebra, Forensic Sci. Int. 219 (2012) 285.e1–285.e5.

[15] K.R. Ostrofsky, S.E. Churchill, Sex Determination by Discriminant Function Analysis of Lumbar Vertebrae, J. Forensic Sci. 60 (2015) 21–28.

[16] A.M. Kubicka, J. Piontek, Sex estimation from measurements of the first rib in a contemporary Polish population, Int. J. Legal Med. 130 (2016) 265–272.

[17] S. Ramadan Uysal, N. Türkmen, N.A. Dolgun, D. Gökharman, R.G. Menezes, M. Kacar, et al., Sex determination from measurements of the sternum and fourth rib using multislice computed tomography of the chest., Forensic Sci. Int. 197 (2010) 120.e1–5.

[18] P.J. Macaluso, A. Rico, M. Santos, J. Lucena, Osteometric sex discrimination from the sternal extremity of the fourth rib in a recent forensic sample from Southwestern Spain, Forensic Sci. Int. 223 (2012) 375.e1–375.e5.

[19] Y. Sasaki, K. Abe, M. Tabei, S. Katsuragawa, A. Kurosaki, S. Matsuoka, Clinical usefulness of temporal subtraction method in screening digital chest radiography with a mobile computed radiography system, Radiol. Phys. Technol. 4 (2011) 84–90.

[20] J.R. Landis, G.G. Koch, The Measurement of Observer Agreement for Categorical Data, Biometrics. 33 (1977) 159–174.

[21] B.L. Riggs, L.J. Melton Iii, R. a Robb, J.J. Camp, E.J. Atkinson, J.M. Peterson, et al., Population-based study of age and sex differences in bone volumetric density, size, geometry, and structure at different skeletal sites., J. Bone Miner. Res. 19 (2004) 1945–1954.

[22] The National Health and Nutrition Survey in Japan (Table 12), Minist. Heal. Labour Welf. Japan. (2014). http://www.e-stat.go.jp/SG1/estat/GL08020103.do?_toGL08020103_&listID=000001151595&requestSender=dsearch (accessed September 13, 2016).

[23] P.J. Macaluso, J. Lucena, Estimation of sex from sternal dimensions derived from chest plate radiographs in contemporary Spaniards, Int. J. Legal Med. 128 (2014) 389–395.

[24] W.D. Zech, G. Hatch, L. Siegenthaler, M.J. Thali, S. Lösch, Sex determination from os sacrum by postmortem CT, Forensic Sci. Int. 221 (2012) 39–43.

Tables

Table 1 The descriptive statistics of each index used in this study and the accuracies of sex determination by using a linear discriminant analysis (LDA) for the indices that demonstrated significant differences.

Indices	Male		Female		p	Accuracies of sex determination (%)		
	Mean	SD	Mean	SD		Male	Female	Total
X_{upper}	41.80	3.73	36.56	3.40	<0.001	75.0 (225/300)	80.7 (242/300)	77.8 (467/600)
X_{middle}	39.90	3.38	35.08	2.87	<0.001	77.7 (233/300)	83.3 (250/300)	80.5 (483/600)
X_{lower}	45.59	3.68	39.86	3.23	<0.001	79.3 (238/300)	81.7 (245/300)	80.5 (483/600)
Y_{left}	24.39	1.83	22.14	1.51	<0.001	74.7 (224/300)	78.0 (234/300)	76.3 (458/600)
Y_{center}	24.29	1.76	22.05	1.50	<0.001	72.3 (217/300)	79.0 (237/300)	75.7 (454/600)
Y_{right}	24.51	1.88	22.35	1.93	<0.001	74.7 (224/300)	76.7 (230/300)	75.7 (454/600)
diagonal	49.19	3.31	43.29	3.11	<0.001	81.7 (245/300)	85.7 (257/300)	83.7 (502/600)
X_{middle}/X_{upper}	0.96	0.05	0.96	0.04	0.163			
X_{middle}/X_{lower}	0.88	0.05	0.88	0.04	0.191			
Y_{center}/Y_{left}	1.00	0.03	1.00	0.03	0.963			
Y_{center}/Y_{right}	0.99	0.03	0.99	0.04	0.158			
$X_{middle} \cdot Y_{center}$	970.54	118.83	773.98	86.13	<0.001	81.7 (245/300)	88.3 (265/300)	85.0 (510/600)
6th rib	11.28	1.07	9.39	0.96	<0.001	81.7 (245/300)	82.0 (246/300)	81.8 (491/600)
7th rib	11.88	1.14	10.03	1.06	<0.001	76.7 (230/300)	82.0 (246/300)	79.3 (476/600)

$p < 0.05$ indicates a significant difference

Table 2 Accuracies of sex determination using the thoracic vertebra, ribs, and the combination of both obtained from 600 chest images.

Region of interest for analysis	Indices selected by stepwise	Accuracies of sex determination (%)		
		Male	Female	Total
Thoracic vertebra	X_{lower} Y_{left} X_{middle}/X_{lower} Y_{center}/Y_{left} Y_{center}/Y_{right}	85.0 (255/300)	88.0 (264/300)	86.5 (519/600)
Rib	6th posterior rib 7th posterior rib	80.3 (241/300)	83.0 (249/300)	81.7 (490/600)
Combination of thoracic vertebra and ribs	X_{lower} Y_{left} Y_{center}/Y_{left} Y_{center}/Y_{right} 6th posterior rib 7th posterior rib	87.3 (262/300)	90.3 (271/300)	88.8 (533/600)

Table 3 Accuracies of sex determination in each age group by using a stepwise discriminant analysis.

Age groups	Indices selected by stepwise	Accuracies of sex determination (%)		
		Male	Female	Total
20s	X_{upper}, Y_{left}, X_{middle}/X_{upper}, X_{middle}/X_{lower}, Y_{center}/Y_{right}, 6th rib, 7th rib	96.0 (48/50)	96.0 (48/50)	96.0 (96/100)
30s	X_{upper}, Y_{right}, X_{middle}/X_{upper}, X_{middle}/X_{lower}, Y_{center}/Y_{left}, Y_{center}/Y_{right}, 7th rib	92.0 (46/50)	92.0 (46/50)	92.0 (92/100)
40s	X_{lower}, Y_{left}, 6th rib	88.0 (44/50)	94.0 (47/50)	91.0 (91/100)
50s	X_{lower}, X_{middle}/X_{lower}, Y_{center}/Y_{left}, Y_{center}/Y_{right}, 6th rib, 7th rib	90.0 (45/50)	96.0 (48/50)	93.0 (93/100)
60s	X_{lower}, Y_{left}, Y_{center}/Y_{left}, 6th rib	92.0 (46/50)	90.0 (45/50)	91.0 (91/100)
70s	Y_{center}, X_{middle}/X_{upper}, 6th rib, 7th rib	88.0 (44/50)	88.0 (44/50)	88.0 (88/100)

Legends to Figures

Fig. 1 Examples of image pre-processing for measurements of widths, heights, and diagonal lengths of the 10th thoracic vertebra on a chest radiograph. (a) original chest image; (b) edge-enhanced image using Sobel filter; (c) sharpened image by adding (b) to (a); (d) sharpened image after adjustment of the window width and level. On the other hand, no pre-processing has been done for measurement of the widths of the 6th and 7th ribs.

Fig. 2 Measurement sites and various indices of the 10th thoracic vertebra on a chest radiograph for sex determination. The average of two diagonal lengths was used for the diagonal (7).

Fig. 3 Determination of location for measurements of the 6th and 7th ribs. Three dotted lines were horizontally set at the beginning of the clavicle, central region of the lung, and bottom of the lung, and a solid line was then drawn through each midpoint of the three dotted lines for determination of measurement criteria. The widths of the ribs on the solid line were measured.

Fig. 4 Flowchart for sex determination based on a stepwise discriminant analysis.

Fig. 5 Distributions of heights for each age group and percentages of overlapped histograms in Japanese male and female.