

Injection-site Granulomas Due to the Administration of Leuprorelin Acetate for the Treatment of Prostatic Cancer

Shiota, Masaki

Department of Urology, Saga Prefectural Hospital, Koseikan

Tokuda, Noriaki

Department of Urology, Saga Prefectural Hospital, Koseikan

Kanou, Takehiro

Department of Urology, Saga Prefectural Hospital, Koseikan

Yamasaki, Humio

Department of Pathology, Saga Prefectural Hospital, Koseikan

<https://doi.org/10.15017/6371>

出版情報：福岡醫學雜誌. 98 (7), pp.301-304, 2007-07-25. 福岡医学会

バージョン：

権利関係：

Case Report

Injection-site Granulomas Due to the Administration of Leuporelin Acetate for the Treatment of Prostatic Cancer

Masaki SHIOTA, Noriaki TOKUDA, Takehiro KANOU and Humio YAMASAKI

*Department of Urology and Pathology, Saga Prefectural
Hospital, Koseikan, Saga, Japan*

Abstract Luteinizing hormone-releasing hormone (LH-RH) analogues have become the main focus of androgen deprivation therapy for prostatic cancer. The occurrence of injection-site granulomas due to the administration of LH-RH analogues has been thought to be a rare reaction. We herein report a rare case presenting injection-site granuloma due to the administration of leuporelin acetate, mimicking metastatic nodule. A 90-year-old man presented with subcutaneous nodules at the injection-site of leuporelin acetate 11.25 mg (for 3-month use). Ultrasound examination and computed tomography (CT) revealed two nodules in the bilateral abdominal walls mimicking metastatic nodule. Although he was surgically treated because of the possibility of malignancy, in the end, no evidence of malignancy was found. We should keep in mind that LH-RH analogues may cause injection-site granulomas mimicking metastatic nodule, and therefore we must inform patients undergoing the administration of leuporelin acetate that it may cause injection-site granuloma and thus when a patient demonstrates a subcutaneous nodule it is essential to confirm whether or not he has received an injection of the LH-RH analogue at the site of nodule.

Key words : granulomas, leuporelin acetate, LH-RH analogues, prostatic neoplasms

Introduction

Luteinizing hormone-releasing hormone (LH-RH) analogues are widely used for the treatment of prostatic cancer, myoma of the uterus and central precocious puberty among other conditions. These drugs can cause adverse reactions, such as hot flush, loss of libido and osteoporosis. However, the occurrence of injection-site granulomas after the administration of LH-RH analogues has been thought to be a rare reaction. Although this type of reaction is not

frequent, it is very bothersome for both patients and physicians. Because these granulomas occur during the treatment of prostatic cancer, they are sometimes misdiagnosed as malignant metastatic tumors. We herein report a rare case presenting injection-site granuloma due to the administration of leuporelin acetate, mimicking a metastatic nodule.

Case report

A 90-year-old man visited local clinic complaining of difficulty with urinary voiding and he was thus referred to our hospital in December 2004. His PSA level was high (84.57 ng/ml) and his prostate was stony hard based on the findings of a digital rectal

Corresponding author : Masaki SHIOTA
Address : 1-12-9, Mizugae, Saga, 840-0054, Japan
Present address : 1-1, Iseigaoka, Yahatanishi-ku, Fukuoka, 807-8555, Japan
Telephone : 81-952 (24) 2171
FAX : 81-952 (29) 9390
E-mail : shiota1976@yahoo.co.jp

examination. As a result, he was diagnosed to have locally advanced prostatic cancer (clinical stage T3aN0M0). He started androgen deprivation therapy with leuporelin acetate 11.25 mg (for 3-month use) in January 2005. The first dose of leuporelin acetate was administered at his left abdominal wall. He received the last injection of second leuporelin acetate 11.25 mg at his right abdominal wall in April 2005. Sixteen days later, he visited the department of surgery at our hospital com-

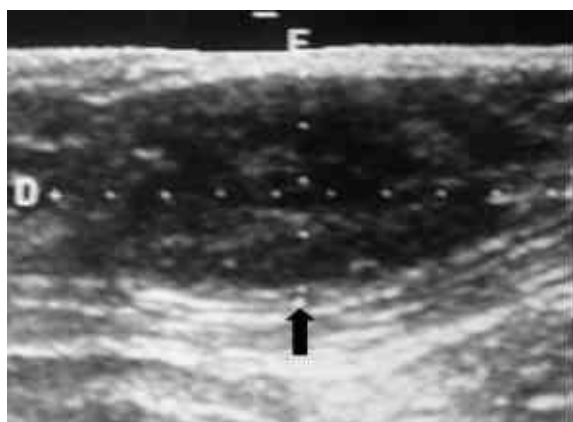


Fig. 1 An ultrasound examination showing subcutaneous hypo-echoic mass, 3.0 x 2.9 cm in size (black arrow) due to the administration of leuporelin acetate 11.25 mg.

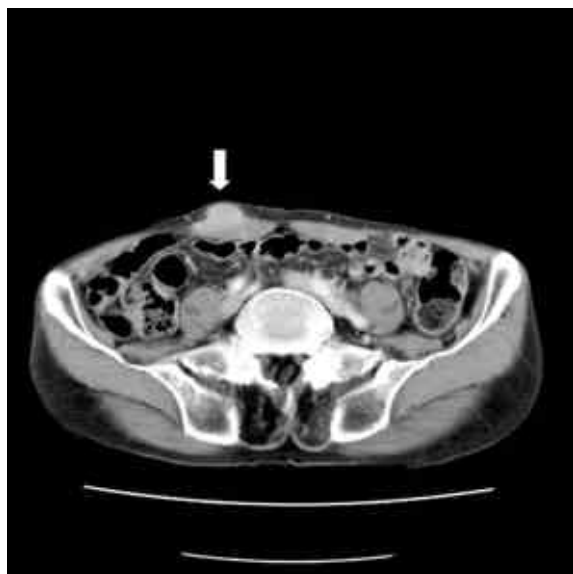

Fig. 2 Computed tomography showing a subcutaneous, relatively high density mass (white arrow) due to the administration of leuporelin acetate 11.25 mg, mimicking a metastatic nodule.

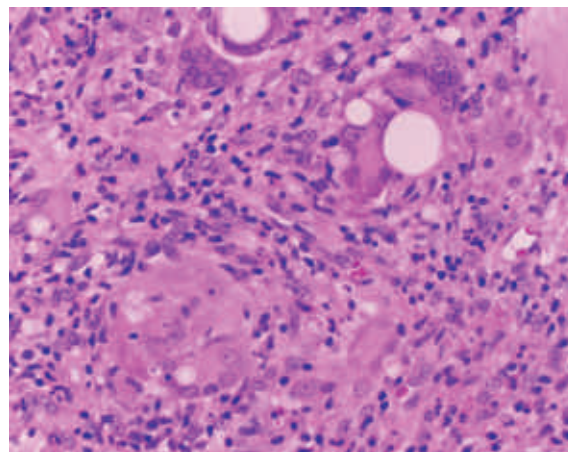


Fig. 3 A microscopic view of the nodule due to the administration of leuporelin acetate demonstrating giant cells associated with granulomatous changes. Haematoxylin and eosin $\times 200$.

plaining of subcutaneous nodules. At that time, his PSA level had decreased to 1.75 ng/ml. In May 2005, an ultrasound examination and computed tomography (CT) revealed two nodules in the bilateral abdominal walls mimicking metastatic nodule (Figs. 1, 2). Therefore, he was treated surgically. The histological findings indicated giant cells associated with granulomatous changes, which are consistent with injection-site granulomas (Fig. 3). There was no evidence of any malignancy. As a result, his treatment was changed to goserelin acetate, and no injection-site granuloma has since occurred.

Discussion

The morbidity rate of prostatic cancer is drastically increasing in Japan. Therefore, urologists now expect to increasingly treat more patients suffering from prostatic cancer. LH-RH analogues have become the main focus of androgen deprivation therapy for prostatic cancer. In Japan, two LH-RH analogues are available for the treatment of prostatic cancer. Leuporelin acetate (LEUPLIN[®], Takeda, Japan) is one of two LH-RH analogues on the market for 1-

month and 3-month use, 3.75 mg and 11.25 mg, respectively.

While injection-site disorders are not frequent, such reactions can cause a great deal of anxiety, particularly that the nodule might be a metastatic nodule during treatment for a malignant tumor. Until now, injection-site granulomas have normally been associated with insulin and aluminum-containing tetanus toxoid vaccines¹⁾. Injection-site granulomas due to the administration of LH-RH analogues have previously been considered rare. Until now, several reports of cases concerning injection-site granulomas caused by LH-RH analogues have been previously published^{2)~4)}. Saxby indicated that injection-site granulomas due to the administration of LH-RH analogues may be more common than previously thought³⁾. Furthermore, in our previous study⁵⁾, the incidence rate was unexpectedly as high as 4.2% when considering all of the LH-RH analogues, or as high as 9.6% when only considering the use of leuporelin acetate.

Leuporelin acetate is coupled with lactic acid/glycolic acid co-polymers or lactic acid polymers. The formation of granulomas could thus be related to such co-polymers or polymers with leuporelin acetate or the leuporelin acetate itself. It is likely that these granulomas have been caused by delayed-type hypersensitivity to LH-RH analogues injection⁴⁾⁵⁾. It is also possible that leuporelin acetate is a higher immunogenic agent⁵⁾. Furthermore, the long-acting type (leuporelin acetate 11.25 mg) of leuporelin acetate for 3-month use may easily induce delayed-type hypersensitivity rather than the short-acting type for 1-month use (leuporelin acetate 3.75mg)⁴⁾⁵⁾.

Injection-site granuloma due to the administration of LH-RH analogues thus

seems to be a serious problem because patients with this adverse reaction have to modify their therapy, such as changing to other LH-RH analogues or undergoing surgical castration. There are also no predictable or preventative measures against this problem. We should therefore keep in mind that LH-RH analogues may cause injection-site granulomas mimicking metastatic nodules, in cases of androgen refractory prostatic cancer with multiple metastases. In addition, in order to reduce patients' anxiety and our misdiagnoses, we should inform patients undergoing the administration of leuporelin acetate that it may cause injection-site granulomas. On the other hand, we should confirm whether or not the patient presenting with subcutaneous nodules has received an injection of a LH-RH analogue at the site of the nodule.

References

- 1) Fawcett HA and Smith NP: Injection-site granuloma due to aluminum. *Arch Dermatol* 120: 1318-1322, 1984.
- 2) Whitaker IS, Fazel MZ, Joshi HB and Moseley RP: Leuporelin acetate granulomas: recurrent subcutaneous nodules mimicking metastatic deposits at injection sites. *BJU Int* 90: 350, 2002.
- 3) Saxby M: Leuporelin acetate granulomas: recurrent subcutaneous nodules mimicking metastatic deposits at injection sites.; letters to editor. *BJU Int* 91: 125, 2003.
- 4) Yasukawa K, Sawamura D, Sugawara H and Kato N: Leuporelin acetate granulomas: case report and review of literature. *Br J Dermatol* 152: 1045-1047, 2005.
- 5) Shiota M, Tokuda N, Kanou T and Yamasaki H: Incidence rate of injection-site granulomas resulting from the administration of luteinizing hormone-releasing hormone analogues for the treatment of prostatic cancer. *Yonsei Med J* in press.

(Received for publication March 19, 2007)

(和文抄録)

前立腺癌治療中の酢酸リュープロレリンによる肉芽腫

¹⁾ 佐賀県立病院好生館 泌尿器科

²⁾ 佐賀県立病院好生館 病理検査科

塩田真己¹⁾, 徳田倫章¹⁾, 狩野武洋¹⁾, 山崎文朗²⁾

黄体化ホルモン放出ホルモン(LH-RH)アナログは、前立腺癌のホルモン療法において重要な役割を担っている。これまで、LH-RHアナログによる注射部位肉芽腫は、稀な副作用と考えられてきた。われわれは、このたび、転移性腫瘍と紛らわしい腫瘤を呈した酢酸リュープロレリンによる肉芽腫を経験したので報告する。症例は、90歳男性。酢酸リュープロレリン11.25 mg(3ヶ月製剤)の注射部位に硬結を認めた。超音波検査、CTにて転移性腫瘍が疑われ、腫瘤摘除術が行われたが、悪性所見はなかった。われわれは、LH-RHアナログにより転移と紛らわしい注射部位肉芽腫を生じる可能性があることを知っておくべきである。また、LH-RHアナログによる治療を受ける患者に対しそのことを周知し、皮下腫瘤を呈した患者を診察した際には、その部位にLH-RHアナログの注射を受けていないか確認すべきである。