九州大学学術情報リポジトリ
Kyushu University Institutional Repository

Frequent Expression of p53 Protein without Mutation in the Atypical Epithelium of Human Bronchus

若松, 謙太郎

https://doi.org/10.11501/3166936

出版情報：九州大学, 1999, 博士（医学）, 論文博士
バージョン：
権利関係：

KYUSHU UNIVERSITY

Frequent Expression of p53 Protein without Mutation in the Atypical Epithelium of Human Bronchus

Kentaro Wakamatsu, Yoichi Nakanishi, Koichi Takayama, Hiroyuki Miyazaki, Kenshi Hayashi, and Nobuyuki Hara

Research Institute for Diseases of the Chest; and Division of Genome Analysis, Institute of Genetic Information, Faculty of Medicine, Kyushu University, Fukuoka, Japan

We investigated the correlation between p53 protein levels and mutations in the *p53* gene of atypical bronchial epithelium (ABE). Protein levels were analyzed by immunohistochemistry, whereas mutations were assessed by polymerase chain reaction–single-strand conformational polymorphism (PCR-SSCP) and direct sequencing. A total of 78 formalin-fixed, paraffin-embedded bronchial biopsy specimens that had been diagnosed to be ABE were retrieved from the archives and examined. p53 protein was expressed in 44 of the 78 (56%) specimens overall. However, when pathologically classified, 38% of hyperplasias, 58% of metaplasias, and 73% of dysplasias were positive, indicating that an increased frequency of p53 expression correlated with the severity of ABE ($P = 0.042$). Among the 44 specimens that expressed p53 protein, 40 (91%) did not reveal mutations by PCR-SSCP. In the four specimens with abnormal PCR-SSCP bands, *p53* gene mutation was identified by direct sequencing and revealed the same point mutation at codon 248 (CGG-to-CTG transversion) of exon 7 in all four specimens. These four specimens were dysplasias derived from patients with lung cancer. p53 protein expression in ABE was associated with the wild-type gene in most cases; therefore, wild-type p53 protein expressed in ABE might have a protective function from lung carcinogenesis, and mutation of *p53* gene may be a late event in the sequential steps of lung carcinogenesis. **Wakamatsu, K., Y. Nakanishi, K. Takayama, H. Miyazaki, K. Hayashi, and N. Hara. 1999. Frequent expression of p53 protein without mutation in the atypical epithelium of human bronchus. Am. J. Respir. Cell Mol. Biol. 21:209–215.**

Human carcinomas of the lung are thought to develop from a series of consecutive independent molecular events. These involve activation of oncogenes such as K-ras, myc, or her2/neu, or loss of recessive oncogenes such as p53 and probably one or more tumor suppressor genes on chromosome 3p (1). The most commonly identified genetic change in human cancers is mutation of the *p53* gene, located at band 13 on the short arm of chromosome 17 (2). This gene is a tumor-suppressor gene and encodes a 53-kD nuclear phosphoprotein capable of binding to DNA and acting as a transcriptional factor (3, 4). The wild-type p53 protein inhibits cell proliferation, and loss of this activity is important in neoplastic transformation (3). The inactivation of tumor-suppressor genes is thought to be important in the development of many human malignancies (5, 6). Inactivation of these genes, through deletion or mutation, presumably allows a cell to escape normal growth controls.

Recent studies have elucidated a model of colorectal tumorigenesis in which the steps required for the development of cancer often involve the mutational activation of an oncogene coupled with the loss of several genes that normally suppress tumorigenesis (7). The sequence of morphologic change is consistent with a multistage model of carcinogenesis, and it is thought that the genetic changes found in advanced lung cancers also occur in a stepwise fashion accompanied by morphologic changes (8–11). In studies of human atypical bronchial epithelium (ABE) adjacent to lung carcinoma in resection specimens, concomitant mutations in *p53* and other genetic abnormalities have been noted in areas of ABE (12, 13). However, sample numbers in these reports have been small, and no associations between immunohistochemical findings and p53 mutations have been reported in ABE found in benign diseases or in tissues separated from the lung carcinomas.

In this study we have investigated the correlation between p53 protein expression and gene mutations in ABE biopsy specimens derived from patients with or without lung cancer, using immunohistochemical detection and poly-

(*Received in original form August 13, 1998 and in revised form March 22, 1999*)

Address correspondence to: Yoichi Nakanishi, Research Institute for Diseases of the Chest, Faculty of Medicine, Kyushu University, 3-1-1 Maidashi, Higashiku, Fukuoka 812-8582, Japan. E-mail: yoichi@kokyu.med.kyushu-u.ac.jp

Abbreviations: atypical bronchial epithelium, ABE; hematoxylin and eosin, H&E; polymerase chain reaction, PCR; PCR–single-strand conformational polymorphism, PCR-SSCP.

Am. J. Respir. Cell Mol. Biol. Vol. 21, pp. 209–215, 1999
Internet address: www.atsjournals.org

TABLE 1

Clinical diagnoses of patients whose transbronchial biopsy specimens revealed atypical bronchial epithelium

Clinical Diagnosis	Cases
Lung cancer	35
Benign diseases	19
Pneumonia	7
Chronic bronchitis	4
Interstitial pneumonia	4
Pulmonary tuberculosis	3
Bronchial asthma	1
Total number	54

merase chain reaction–single-strand conformational polymorphism (PCR-SSCP) followed by direct sequencing.

Materials and Methods

Materials

Seventy-eight formalin-fixed, paraffin-embedded, bronchial biopsy specimens from 54 patients treated at the National Omuta Hospital, Fukuoka, Japan, between 1984 and 1995 were studied (Table 1). There were 35 patients with lung cancer and 19 patients with nonmalignant diseases, including seven patients with pneumonia, four with chronic bronchitis, four with interstitial pneumonia, three with pulmonary tuberculosis, and one with bronchial asthma. ABE was graded independently by two pathologists as hyperplasia, metaplasia, or dysplasia as described by Mackay and colleagues (14). Briefly, each premalignant lesion was diagnosed as follows. In hyperplasia, the deepest stratum of the epithelium becomes several layers thick; an occasional slightly enlarged polyhedral or oval cell with slight irregularity of the nuclear membrane and a recognizable nucleolus, but with little change in the nuclear chromatin, is noted (Figure 1, *left panel*). In metaplasia, the columnar cells are converted into a stratified squamous type of epithelium; the epithelium is not ciliated, nuclei are central and round to oval, and the chromatin has a ground-glass appearance (Figure 1, *center panel*). In dysplasia, the epithelium is thickened; nuclei with increases in the nuclear/cytoplasmic ratio and some loss of polarity can be seen (Figure 1, *right panel*). As shown in Table 2, there were 26 specimens with hyperplasia, 26 with metaplasia, and 26 with dysplasia.

Immunohistochemistry

The method of Shin and associates was used for immunostaining to enhance immunoreactivity in formalin-fixed TBB samples (15). Tissue sections of 4-μm thickness were cut, placed on slides, and dried overnight at 60°C. The specimens were then deparaffinized in xylene and dehydrated in ethanol series. Subsequently, the slides were autoclaved for 20 min at 120°C to increase the reactivity of the p53 protein with the antibody. After cooling, nonspecific binding of the primary antibody was blocked by 10% rabbit serum placed on the slides for 20 min. The avidin-biotin complex method was used for immunostaining. The primary anti-p53 monoclonal antibody was DO-1 (Ab-6; Oncogene Science, Uniondale, NY), which recognizes both wild-type and mutant forms of p53. The slides were incubated overnight at 4°C with DO-1 at a dilution of 1:200 (0.5 μg/ml), followed by secondary biotinylated anti-mouse immunoglobulin G (Nichirei, Tokyo, Japan) and peroxidase-conjugated avidin (Nichirei). Careful rinses were done with several changes of phosphate-buffered saline (PBS) between all stages of the procedure. The antigen-antibody complex was visualized using a 0.05% solution of diaminobenzidine tetrahydrochloride in PBS for 5 min. Subsequently, the slides were dehydrated and cleared in xylene.

Immunoreactivity in the epithelia was evaluated by three pathologists. The number of p53-immunoreactive nuclei was counted and expressed as a percentage of all nuclei of the entire ABE. Tissues that expressed p53 immunoreactivity in the nuclei of more than 90% of ABE cells were considered to be 2+; those with 10 to 90% reactivity were 1+; those with 5 to 10% reactivity were ±; and those with fewer than 5% positive cells were considered −.

Figure 1. H&E staining in atypical bronchial epithelium from a transbronchial biopsy specimen. In hyperplasia, the deepest stratum of the epithelium becomes several layers thick. An occasional slightly enlarged polyhedral or oval cell with slight irregularity of the nuclear membrane and a recognizable nucleolus, but with little change in the nuclear chromatin, is noted (*left panel*). In metaplasia, the columnar cells are converted into a stratified squamous type of epithelium. The epithelium is not ciliated, nuclei are central and round to oval, and the chromatin has a ground-glass appearance (*center panel*). In dysplasia, the epithelium is thickened. Nuclei with increase in the nuclear/cytoplasmic ratio and some loss of polarity can be seen (*right panel*). Original magnifications: *left*, ×170; *center*, ×220; *right*, ×200.

TABLE 2

Classification of cellular atypia and presence/absence of lung cancer

	Lung Cancer		
	(+)	(−)	Total
Hyperplasia	13	13	26
Metaplasia	17	9	26
Dysplasia	22	4	26
Total	52	26	78

Microdissection of Materials and DNA Extraction

We used a modification of a previously described precise microdissection technique (16) to collect atypical epithelial cells under direct microscopic observation from hematoxylin and eosin (H&E)–stained sections. Microdissection was performed with an inverted microscope using a microcapillary tube that was pulled to a fine tip by a micropipette puller and with a joystick-operated hydraulic micromanipulator. The dissected cells were allowed to adhere to the microcapillary tip and collected in 0.5-ml microcentrifuge tubes. The materials from approximately 100 cells were digested in 5 μl of buffer consisting of 20 mM Tris (pH 8.0), 1 mM ethylenediaminetetraacetic acid (EDTA), 0.5% Tween 20, and 200 μg/ml proteinase K for 48 h at 37°C, and then incubated for 15 min at 95°C to inactivate the proteinase K. A total of 1 μl of the digested sample extract was used for each PCR.

PCR-SSCP Analysis

Screening of DNA samples by SSCP to detect point mutations in the *p53* gene was performed as we have described previously (17), with slight modifications.

The nucleotide sequences of the primers were as follows: exon 5: 5′-CTCTTCCTGCAGTACTCCCCTGC-3′ (sense), and 5′-GCCCCAGCTGCTCACCATCGCTA-3′ (antisense); exon 6: 5′-GATTGCTCTTAGGTCTGGCCCCTC-3′ (sense), and 5′-GGCCACTGACAACCACCCTTAACC-3′(antisense); exon 7: 5′-GTGTTGTCTCCTAGGTTGGCTCTG-3′ (sense), and 5′-CAAGTGGCTCCTGACCTGGAGTC-3′ (antisense); and exon 8: 5′-ACCTGATTTCCTTACTGCCTCTGGC-3′ (sense), and 5′-GTCCTGCTTGCTTACCTCGCTTAGT-3′(antisense).

For each sample, the four primer pairs described above were used in individual PCRs to amplify *p53*-coding sequences in extract from ABE as templates. PCR was performed in a thermal cycler. The PCR mixture (5 μl) contained extract (1 μl), 125 μm of each deoxynucleotide triphosphate, primers (1 μm), 2.5 mM $MgCl_2$, 50 mM KCl, 10 μm Tris-HCl, 0.25 U of Taq polymerase (Perkin-Elmer, Norwalk, CT), and 0.5 μCi of [α-^{32}P]deoxycytidine triphosphate (Amersham International, Little Chalfont, UK). A total of 35 cycles were performed, each cycle consisting of 30 s at 94°C, 2 min at 65°C, and 2 min at 72°C. The PCR products were diluted in 50 μl of formamide-dye solution (95% formamide, 20 mM EDTA, 0.05% bromophenol blue, and 0.05% xylene cyanol) and denatured at 80°C for 5 min, and then 1 μl of each product was applied to 5% polyacrylamide gel with 5% glycerol. Electrophoresis was performed at 40 W for 2 h at 25°C. The gel was dried on filter paper and exposed to an X-ray film for 12 h.

To confirm the accuracy of the results, another set of primer pairs, described later (18), was used in individual PCRs to amplify *p53*-coding sequences in ABE extracts. All procedures for PCR-SSCP were identical to those described previously (17).

Nucleotide sequences for this second set of primer pairs were: exon 5: 5′-GCAGTACTCCCCTGCCCTCAACAA-3′ (sense), and 5′-TCACCATCGCTATCTGAGCAGCGC-3′ (antisense); exon 6: 5′-TCTTAGGTCTGGCCCCTCCTCAGC-3′ (sense), and 5′-CAGACCTCAGGCGGCTCATA-3′ (antisense); exon 7: 5′-CTCCTAGGTTGGCTCTGACTGTAC-3′ (sense), and 5′-TGGCTCCTGACCTGGAGTCTTCCA-3′(antisense); and exon 8: 5′-AGTGGTAATCTACTGGGACGG-3′ (sense), and 5′-TTGCTTACCTCGCTTAGTGCTCCC-3′ (antisense).

Direct Sequencing

Mutant fragments were excised from the polyacrylamide gels, and the gel slices were immersed in 20 μl of H_2O and heated to 80°C for 5 min. After brief centrifugation, 1 μl of the supernatant was subjected to PCR reamplification for 25 cycles. Before sequencing, the amplified PCR products were purified by Microcon 100 and a portion was subjected to electrophoresis on a 2% agarose gel to confirm the size of the PCR product. Sequencing was done by the AmpliCycle system (Perkin-Elmer), with the same primers as used in the first PCR. Electrophoresis was performed on a 6% polyacrylamide gel containing 7 M urea.

Statistical Analysis

The significance of associations was determined by a χ^2 test. Values of $P < 0.05$ were considered significant.

Results

Nuclear staining of cells with an anti-p53 antibody was assessed by immunohistochemical analysis, as shown in Figure 2. Although we have classified the degree of immunostaining according to the percentage of p53-immunopositive cells as described in Materials and Methods, all the ABE specimens that were considered to be positive expressed p53 protein in more than 90% of atypical cells, and negative samples expressed p53 in fewer than 1% of cells. By these classifications, 44 of the 78 ABE cases were positive for p53 protein, representing 38% of hyperplasias, 58% of metaplasias, and 73% of dysplasias (Figure 3). In contrast, expression of p53 was not seen in normal bronchial epithelium. The association between p53 expression and the ABE grade was statistically significant ($P = 0.0416$). There was no significant relationship between p53 expression and the patients' backgrounds, including clinical diagnosis, sex, age, or smoking status (Table 3).

To assess the possibility that the *p53* gene was mutated in ABE, a microdissection technique was used to extract DNA from 44 lesions that showed p53 immunoreactivity. A total of 50 to 500 cells was microdissected from each area,

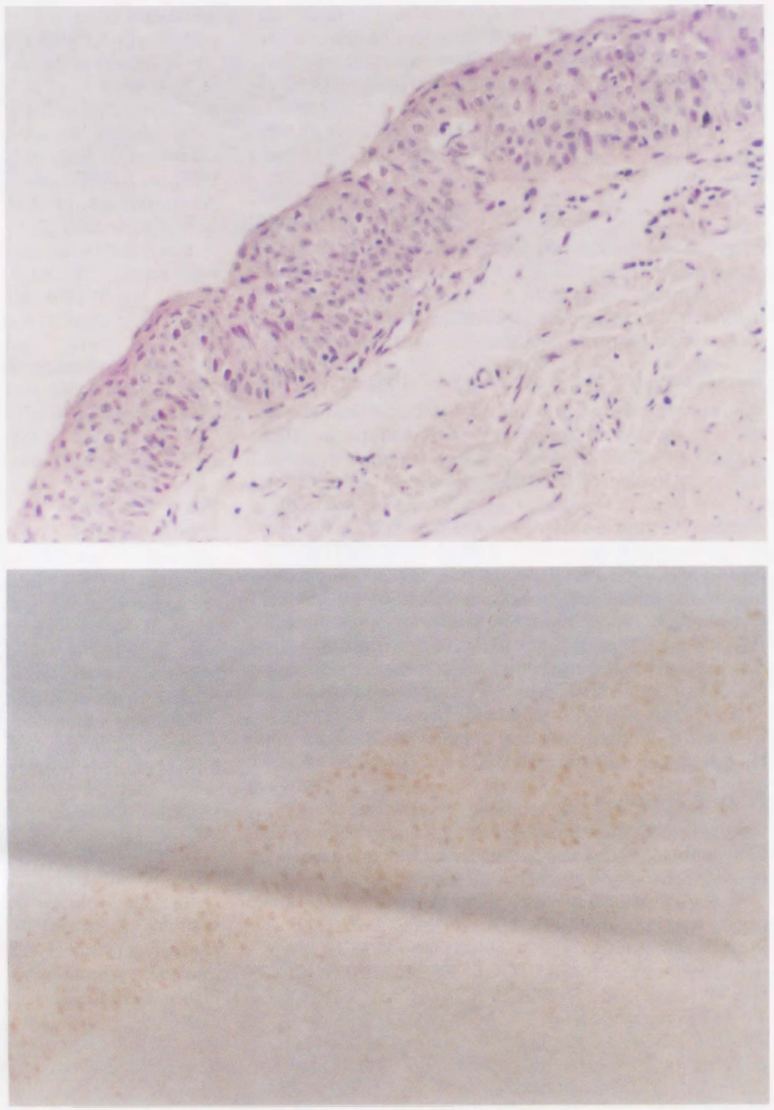

Figure 2. H&E staining (*upper panel*) and immunostaining (*lower panel*) of bronchial epithelium with dysplasia. Original magnification: ×250.

and at least 50 cells were used for each PCR. As described previously, more than 90% of the cells microdissected were positively stained for p53.

We screened for the presence of mutations in exons 5, 6, 7, and 8 in the microdissected materials, because more than 80% of *p53* gene mutations occur in these exons (19, 20). A single specific amplification product was detected in all cases, including that all microdissected materials provided suitable template DNA for use in PCRs. Forty of the 44 (91%) ABE did not reveal mobility shifts by PCR-SSCP. In the four specimens with mobility shifts, the *p53* gene mutation was identified by direct sequencing (Figure 4, *upper panel*). The DNA sequencing reaction of the PCR-amplified exon 7 showed the same point mutation at codon 248 (CGG-to-CTG transversion) in all four specimens (Figure 4, *lower panel*). The pathologic diagnosis of these four specimens was dysplasia, and all of them were derived from the patients with lung cancer. *p53* gene mutation was not detected in any specimens with ABE derived from benign diseases. One case, in which biopsies from areas with both ABE and cancer were available, revealed the same point mutation in both samples (data not shown).

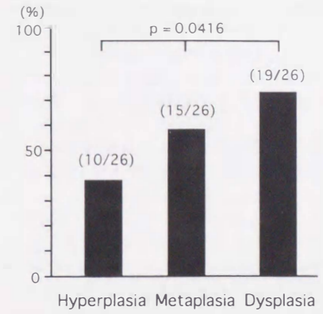

Figure 3. Data show p53 immunoreactivity in each grade of ABE. The ratios shown at the top of each bar are the number of positive samples/total number of lesions of a specific histologic grade.

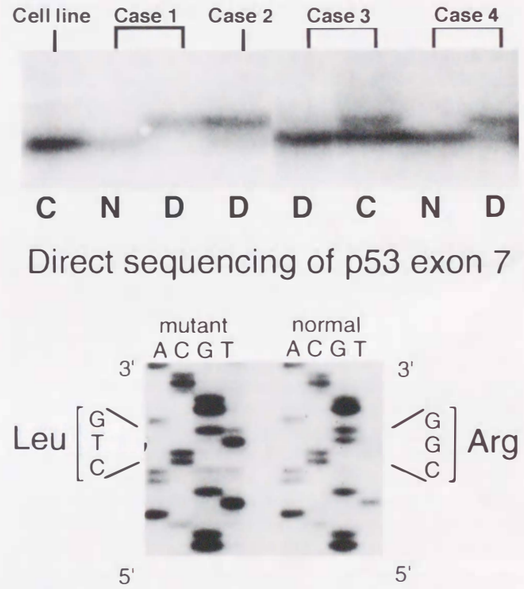

Figure 4. SSCP analysis of p53 exon 7 from normal (N), dysplastic (D), and carcinoma (C) tissues from four cases (*upper panel*). Mobility shifts were observed in dysplasia and carcinoma samples. DNA sequencing by PCR of amplified exon 7 fragments from normal and dysplastic tissue in case 1 is shown (*lower panel*). The codon at which the mutation occurs is indicated.

Discussion

Of the known tumor-suppressor genes, *p53* is the gene most frequently mutated in human malignancies (21). This gene is mutated in many common tumors, including breast, ovarian, and colon cancers. In lung cancer, approximately 90% of small-cell lung cancers (22) and 50% of non–small-cell lung cancers have mutated *p53* (23), with the highest incidence found in squamous-cell carcinomas (60%) and the lowest incidence in adenocarcinomas (30%) (19, 24, 25). It has been reported that the expression of p53 protein in cancer cells is generally associated with mutations in the *p53* gene (20, 26). However, it is not clear whether this tendency exists in premalignant lesions as well.

In the present study we have shown that expression of p53 protein was found in 56% of the specimens with ABE and that increased p53 expression correlated with the severity of cellular atypia, consistent with data reported by other investigators using both surgically resected specimens (8, 9) and transbronchial biopsy specimens (10, 11, 27). Nuorva and coworkers (8) found a significant concurrence between p53 expression in bronchial dysplasias and their related squamous-cell carcinomas, suggesting that the p53 expression could be an early event in the development of a squamous-cell carcinoma of the lung. Bennett and colleagues (9) reported an increased frequency of p53 protein accumulation in dysplasia, and that suggested p53 alterations (but not mutations) occur before invasion. Investigators Boers and associates (11) and Walker and coworkers (10) have shown that the proportion of p53-positive cells was correlated with the existence or development of lung cancer (11). However, Walker and colleagues (10) also found that expressions of p53 protein in the normal epithelium of resection margins in five of 10 were cancer specimens, despite negative expression of p53 protein in the tumors themselves (10). These results indicate that the biologic characteristics of p53 protein detected in ABE may, at least in part, be different from those in cancer cells.

The antibodies used in the previously reported studies as well as in our study recognize wild-type and mutant p53 protein. Thus, it is impossible to distinguish wild-type and mutant p53 protein by immunohistochemical analysis. Because the functions of wild-type and mutant p53 proteins are generally distinct, it is important to assess the status of p53 protein expression in ABE in the context of *p53* gene

TABLE 3

Relationship between p53 expression and patients' clinical backgrounds

	p53 Expression		
	(+)	(−)	*P* Value
Total number of patients	31	23	
Sex			
Male	29	17	0.11
Female	2	6	
Age			
Median	67	69	
Range	50–89	18–89	
Smoking status			
Smoker	18	12	0.88
Nonsmoker	13	11	
Clinical diagnosis			
Lung cancer	22	13	0.42
Benign diseases	9	10	

mutations. There are only a few studies reporting that *p53* gene mutations existed in the dysplastic tissues adjacent to the carcinoma tissue and that the gene alterations were concordant with those found in the carcinoma. Sozzi and associates (12) reported that the same *p53* gene mutation was found in both the tissue of lung cancer and the tissue of severe dysplasia taken at the resection margin. In that report, investigators analyzed a detailed *p53* gene status using a PCR-SSCP method followed by a direct sequencing method in only one case. Sundaresan and coworkers (13) reported that allelic loss at the p53 locus in bronchial dysplasia was found in one of three cases with lung cancer and one of two cases without lung cancer. Franklin and associates (28) reported that a single identical point mutation in the *p53* gene was identified in ABE tissues derived from an individual with widespread dysplastic changes of respiratory epithelium, suggesting a mechanism for field carcinogenesis. However, it was still unclear whether alterations of *p53* are commonly found in ABE because only a small number of samples had been analyzed. To investgate the biologic meanings of p53 protein overexpression in ABE, gene analysis of *p53* would be essential. Therefore, we investigated *p53* gene alteration in ABE samples that expressed p53 protein. To avoid contamination with normal cells, we adopted a microdissection method for the collection of atypical cells. In addition, in p53-positive samples with ABE, more than 90% of atypical cells were positive for p53 protein, suggesting that these atypical cells were relatively homogenous with regard to p53 expression. By PCR-SSCP, mutations in the *p53* gene were detected in only four of 44 (9%) ABE. It is difficult to be certain that the other 40 cases express wild-type p53 because mutations in the primer region would not be detected by PCR-SSCP. However, to circumvent this problem we used two different sets of primers to detect the mutation of *p53* in independently microdissected DNA samples; the results were identical. Therefore, it appears that in most ABE samples, wild-type p53 was expressed. In addition, it is noteworthy that *p53* mutations were found only in the ABE samples derived from the patients with lung cancer (but not benign diseases) because the result implies that *p53* mutation is a late event of lung carcinogenesis.

The accumulation of nonmutant p53 protein may occur through several mechanisms: inactivation of an enzymatic pathway responsible for p53 degeneration (29), stabilization of normal p53 protein through complex formation with a cellular oncoprotein such as mdm2 (30, 31) or a DNA tumor virus protein (32), DNA damage-induced post-transcriptional modification conferring an extended p53 protein half-life (33), altered expression of the *p53* gene by cellular transcriptional regulators (34), and physiologic accumulation during the late G_1 and S phases of the cell cycle (35). Rämet and colleagues have reported that wild-type p53 protein accumulated in cells following treatment with benzo(a)pyrene, a major chemical carcinogen related to tobacco smoking (36). They suggested that p53 may have a crucial role in preventing the initiation of carcinogenesis induced by polycyclic aromatic hydrocarbons. The mechanism accounting for accumulation of wild-type p53 protein (but not mutant p53 protein) in premalignant lesions is unclear. However, expression of p53 protein in ABE might act as a protector against carcinogenesis of the premalignant lesion because wild-type p53 protein is generally believed to inhibit carcinogenesis.

Interestingly, the *p53* mutation in all four cases of ABE occurred at codon 248, CGG to CTG. This is consistent with a hot point of mutations found in lung cancer cases (19). In addition, the same mutation was found in the dysplastic tissue and cancer tissue from the same patient.

In summary, the p53 protein was expressed in more than half of the specimens with ABE, although nearly 90% of the ABE specimens expressed wild-type p53 protein. This result suggests that mutation of the *p53* gene in human ABE is not a common event and that *p53* may act to inhibit the carcinogenesis of precancerous ABE lesions.

References

1. Jacobson, D. R., C. L. Fishman, and N. E. Mills. 1995. Molecular genetic markers in the early diagnosis and screening of non-small-cell lung cancer. *Ann. Oncol.* 6(Suppl. 3):S3–S8.
2. Isobe, M., B. S. Emanuel, D. Givol, M. Oren, and C. M. Croce. 1986. Localization of gene for human p53 tumor antigen to band 17p13. *Nature* 320: 84–85.
3. Finlay, C. A., P. W. Hinds, and A. J. Levine. 1989. The p53 proto-oncogene can act as a suppressor of transformation. *Cell* 57:1083–1093.
4. Minna, J. D. 1993. The molecular biology of lung cancer pathogenesis. *Chest* 103:449S–456S.
5. Nowell, P. C. 1986. Mechanisms of tumor progression. *Cancer Res.* 46:2203–2207.
6. Marshall, C. J. 1991. Tumor suppressor genes. *Cell* 64:313–326.
7. Vogelstein, B., E. R. Fearon, S. R. Hamilton, S. E. Kern, A. C. Preisinger, M. Leppert, Y. Nakamura, R. White, A. M. M. Smits, and J. L. Bos. 1988. Genetic alterations during colorectal tumor development. *N. Engl. J. Med.* 319:525–532.
8. Nuorva, K., Y. Soini, D. Kamel, D. Kamel, H. Autio-Harmainen, L. Risteli, J. Risteli, K. Vahakangas, and P. Paakko. 1993. Concurrent p53 expression in bronchial dysplasias and squamous cell lung carcinomas. *Am. J. Pathol.* 142:725–732.
9. Bennett, W. P., T. V. Colby, W. D. Travis, A. Borkowski, R. T. Jones, D. P. Lane, R. A. Metcalf, J. M. Samet, Y. Takeshima, J. R. Gu, K. H. Vahakangas, Y. Soini, P. Paakko, J. A. Welsh, B. F. Trump, and C. C. Harris. 1993. p53 protein accumulates frequently in early bronchial neoplasia. *Cancer Res.* 53:4817–4822.
10. Walker, C., L. J. Robertson, M. W. Myskow, N. Pendleton, and G. R. Dixon. 1994. p53 expression in normal and dysplastic bronchial epithelium and in lung carcinomas. *Br. J. Cancer* 70:297–303.
11. Boers, J. E., G. P. M. Ten Velde, and F. B. J. M. Thunnissen. 1996. p53 in squamous metaplasia: a marker for risk of respiratory tract carcinoma. *Am. J. Respir. Crit. Care Med.* 153:411–416.
12. Sozzi, G., M. Miozzo, R. Donghi, S. Pilotti, C. T. Cariani, U. Pastorino, G. Della Porta, and M. A. Pierotti. 1992. Deletions of 17p and p53 mutations in preneoplastic lesions of the lung. *Cancer Res.* 52:6079–6082.
13. Sundaresan, V., P. Ganly, P. Hasleton, R. Rudd, G. Sinha, N. M. Bleehen, and P. Rabbitts. 1992. p53 and chromosome 3 abnormalities, characteristic of malignant lung tumours, are detectable in preinvasive lesions of the bronchus. *Oncogene* 7:1989–1997.
14. Mackay, B., J. M. Lukeman, and N. G. Ordonez. 1991. Premalignant lesions. *In* Tumors of the Lung. J. Mitchell, editor. W. B. Saunders Company, Philadelphia. 90–99.
15. Shin, R. W., T. Iwaki, T. Kitamoto, and J. Tateishi. 1991. Hydrated autoclave pretreatment enhances TAU immunoreactivity in formalin-fixed normal and Alzheimer's disease brain tissues. *Lab. Invest.* 64:693–702.
16. Whetsell, L., G. Maw, N. Nadon, D. P. Ringer, and F. V. Schaefer. 1992. Polymerase chain reaction microanalysis of tumors from stained histological slides. *Oncogene* 7:2355–2361.
17. Mashiyama, S., Y. Murakami, T. Yoshimoto, T. Sekiya, and K. Hayashi. 1991. Detection of *p53* gene mutations in human brain tumors by single-strand conformation polymorphism analysis of polymerase chain reaction products. *Oncogene* 6:1313–1318.
18. Umekita, Y., K. Kobayashi, T. Saheki, and H. Yoshida. 1994. Nuclear accumulation of p53 protein correlates with mutations in the p53 gene on archival paraffin-embedded tissues of human breast cancer. *Jpn. J. Cancer Res.* 85:825–830.
19. Greenblatt, M. S., W. P. Bennett, M. Hollstein, and C. C. Harris. 1994. Mutations in the p53 tumor suppressor gene: clues to cancer etiology and molecular pathogenesis. *Cancer Res.* 54:4855–4878.

20. Harris, C. C., and M. Hollstein. 1993. Clinical implications of the p53 tumor-suppressor gene. *N. Engl. J. Med.* 329:1318–1327.
21. Giaccone, G. 1996. Oncogenes and antioncogenes in lung tumorigenesis. *Chest* 109:130S–134S.
22. D'Amico, D., D. Carbone, T. Mitsudomi, M. Nau, J. Fedorko, E. Russel, B. Johnson, D. Buchhagen, S. Border, and R. Phelps. 1992. High frequency of somatically acquired *p53* mutations in small-cell lung cancer cell lines and tumors. *Oncogene* 7:339–346.
23. Chiba, I., T. Takahashi, M. M. Nau, D. D'Amico, D. T. Curiel, T. Mitsudomi, D. L. Buchhagen, D. Carbone, S. Piantadosi, H. Koga, P. T. Reissman, D. J. Slamon, E. C. Holmes, and J. D. Minna. 1990. Mutations of *p53* gene are frequent in primary, resected non-small cell lung cancer. *Oncogene* 5:1603–1610.
24. Takahashi, T., M. M. Nau, I. Chiba, M. J. Birrer, R. K. Rosenberg, M. Vinocour, M. Levitt, H. Pass, A. F. Gazdar, and J. D. Minna. 1989. *p53*: a frequent target for genetic abnormalities in lung cancer. *Science* 246:491–494.
25. Kishimoto, Y., Y. Murakami, M. Shiraishi, K. Hayashi, and T. Sekiya. 1992. Aberrations of *p53* tumor suppressor gene in human non-small cell carcinomas of the lung. *Cancer Res.* 52:4799–4804.
26. Hollstein, M., D. Sidransky, B. Vogelstein, and C. C. Harris. 1991. p53 mutations in human cancers. *Science* 253:49–53.
27. Hirano, T., B. Franzen, H. Kato, Y. Ebihara, and G. Auer. 1994. Genesis of squamous cell lung carcinoma: sequential changes of proliferation, DNA ploidy, and p53 expression. *Am. J. Pathol.* 144:296–302.
28. Franklin, W. A., A. F. Gazdar, J. Haney, I. I. Wistuba, F. G. La Rosa, T. Kennedy, D. M. Ritchey, and Y. E. Miller. 1997. Widely dispersed *p53* mutation in respiratory epithelium: a novel mechanism for field carcinogenesis. *J. Clin. Invest.* 100:2133–2137.
29. Ciechanover, A., J. A. Digiusepe, B. Bercovich, A. Orian, J. D. Richter, A. L. Schwartz, and G. M. Brodeur. 1991. Degradation of nuclear oncoproteins by the ubiquitin system in vitro. *Proc. Natl. Acad. Sci. USA* 88:139–143.
30. Oliner, J. D., J. A. Pietenpol, S. Thiagalingam, J. Gyuris, K. W. Kinzler, and B. Vogelstein. 1993. Oncoprotein mdm-2 conceals the activation domain of suppressor p53. *Nature* 362:857–860.
31. Momand, J., G. P. Zambetti, D. C. Olson, D. L. George, and A. J. Levine. 1992. The mdm-2 oncogene product forms a complex with the p53 protein and inhibits p53-mediated transactivation. *Cell* 69:1237–1245.
32. van den Heuvel, S. J., T. van Laar, W. M. Kast, C. J. Melief, A. Zantema, and A. J. van der Eb. 1990. Association between the cellular p53 and the adenovirus 5 E1B-55kd proteins reduces the oncogenicity of Ad-transformed cells. *EMBO J.* 9:2621–2629.
33. Hall, P. A., P. H. Mckee, H. P. Menage, R. Dover, and D. P. Lane. 1993. High levels of p53 protein in UV-irradiated normal human skin. *Oncogene* 8:203–207.
34. Ronen, D., V. Rotter, and D. Reisman. 1991. Expression from the murine p53 promoter is mediated by factor binding to a downstream helix-loop-helix recognition motif. *Proc. Natl. Acad. Sci. USA* 88:4128–4132.
35. Shaulsky, G., A. Ben-Ze'ev, and V. Rotter. 1990. Subcellular distribution of the p53 protein during the cell cycle of Balb/c 3T3 cells. *Oncogene* 5:1707–1711.
36. Rämet, M., K. Castren, K. Jarvinen, K. Pekkala, T. Turpeenniemi-Hujanen, Y. Soini, P. Paakko, and K. Vahakangas. 1995. p53 protein expression is correlated with benzo(*a*)pyrene-DNA adducts in carcinoma cell lines. *Carcinogenesis* 16:2117–2124.