九州大学学術情報リポジトリ
Kyushu University Institutional Repository

A Case of Atrial Tachycardia Originating from Giant Coronary Sinus Connected to Persistent Left Superior Vena Cava: Successful Catheter Ablation Guided by Noncontact Mapping

Nakamura, Hirofumi
Department of Medicine and Biosystemic Science, Kyushu University

Fujiwara, Masahiko
Department of Medicine and Biosystemic Science, Kyushu University

Nakaji, Gen
Department of Medicine and Biosystemic Science, Kyushu University

Yasuda, Shioto
Department of Medicine and Biosystemic Science, Kyushu University

他

https://doi.org/10.15017/15516

出版情報：福岡醫學雜誌. 100 (7), pp.258-264, 2009-07-25. 福岡医学会
バージョン：
権利関係：

Fukuoka Acta Med. 100(7) : 258—264, 2009

Case Report

A Case of Atrial Tachycardia Originating from Giant Coronary Sinus Connected to Persistent Left Superior Vena Cava: Successful Catheter Ablation Guided by Noncontact Mapping

Hirofumi NAKAMURA[1)], Masahiko FUJIWARA[1)], Gen NAKAJI[1)], Shioto YASUDA[1)], Eiji KARASHIMA[1)], Shin-ichi HIRAMATSU[1)], Keita ODASHIRO[1)], Toru MARUYAMA[2)] and Koichi AKASHI[1)]

[1)] *Department of Medicine and Biosystemic Science, Kyushu University, Fukuoka, 812-8582, Japan*
[2)] *Institute of Health Science, Kyushu University, Kasuga, 816-8580, Japan*

Abstract Radiofrequency (RF) catheter ablation is widely applied to tachyarrhythmia associated not only with structurally normal hearts but also with relatively mild cardiac anomalies. We present a case of 35 year-old female complaining of exercise-induced frequent palpitations caused by atrial tachycardia (AT) originating from giant coronary sinus (CS) connected to persistent left superior vena cava. AT was sensitive to intravenous ATP administration. Electrophysiological study partly using noncontact balloon of EnSite system clarified that two foci of AT were located at the orifice and the distal inner lumen of giant CS. After repetitive applications of RF energy to these origins, AT was not induced by drip infusion of isoproterenol. AT was not evoked by exercise without antiarrhythmic drugs 15 months after the RF ablation. This case indicates that RF ablation guided by noncontact mapping technique should be considered as a therapeutic regimen for AT associated with mild cardiac malformations.

Key words : Atrial tachycardia, Coronary sinus, Left superior vena cava, Noncontact mapping, Radiofrequency ablation

Introduction

Most of radiofrequency (RF) catheter ablation strategies have concerned patients with tachyarrhythmias associated with structurally normal hearts. However, indication of RF ablation is going to be expanded to the cases of arrhythmias associated with mild cardiac anomalies. With emerging sophisticated electroanatomical mapping techniques, RF ablation is considered as a safe and effective therapeutic strategy for ventricular and supraventricular arrhythmias in patients with various congenital heart diseases[1)~4)]. In this article, we report a case of atrial tachycardia (AT) originating from the foci within the giant coronary sinus (CS) connected to the persistent left superior vena cava (LSVC).

Case Report

A 35-year-old woman complained of frequent palpitations due to persistent AT, which had been treated with mexiletin (150 mg) and metoprolol (60 mg). However, AT became refractory to these drugs and was evoked easily by exercise. She demonstrated gradual cardiomegaly, which was treated with enalapril (5 mg). Thereafter, she was referred to our hospital for the treatment of frequent AT and consequent cardiomegaly. Ambulatory electrocardiographic (ECG) monitoring demonstrated frequent premature supraventricular contractions (PSVCs) and paroxysms of AT. In the standard ECG, P wave morphology of the PSVCs was biphasic polarities, i.e., negative followed by positive deflections (Fig.

Address reprint requests to : Toru MARUYAMA, MD.,
Institute of Health Science, Kyushu University, Kasuga, 816-8580, Japan
Tel : + 81-92-642-5235 (direct call) ; Fax : + 81-92-642-5247 ;
E-mail : maruyama@ihs.kyushu-u.ac.jp

1A, arrows). In transthoracic echocardiography, CS was enlarged with a diameter of 16 mm and left ventricular ejection fraction was 44%. Computerized tomography (CT) demonstrated no structural abnormalities except for CS-LSVC complex forming a single 'conduit' (Fig. 1B). After obtaining the written informed consent, cardiac electrophysiological study (EPS) and RF catheter ablation of AT were performed.

In the EPS laboratory, sinus node function test was impossible because of frequent PSVCs forming bigeminy. Multielectrode catheters were placed at high right atrium (HRA), His bundle, CS and also pulmonary veins (PV) after Brockenbrough's procedure. Baseline EPS showed PA, AH and HV intervals of 35, 175 and 51 msec, respectively (Fig. 2A), i.e., significant delay was noted in the atrioventricular conduction alone. AT was spontaneously evoked during EPS and was sensitive to intravenous bolus administration of ATP (20 mg), which is currently used in EPS to suppress atrioventricular nodal conduction or ectopic automaticity. The earliest activation of PSVCs was observed not in the right atrium (RA) or PV but in the giant CS. EnSite system (EnSite 3000 with Precision Software, Endocardial Solutions, Inc, St Paul, MN, USA) was applied to identify and ablate the possible origin of AT under reconstructing CS geometry by single PSVC analysis. The 64-electrode array noncontact balloon (7.5 ml) mounted on a 9Fr catheter electrode was carefully introduced into the giant CS lumen (Fig. 3A). Color-coded isopotential mapping of CS activation demonstrated that PSVCs arose from ectopic focus located in the vicinity of CS ostium (Fig. 2B). Conventional EPS did not indicate left-sided atrioventricular accessory pathways bridging the CS. After confirming that the earliest activation site was recorded by ablation catheter (Ablaze, Fantasista, 7Fr., Japan Lifeline Co., Ltd., Tokyo, Japan) positioned at CS ostium (Fig. 2C), RF energy was applied to this site and AT disappeared by the first energy application.

Soon after the first RF ablation, another AT emerged. Because ablation catheter manipulation was difficult due to the large noncontact balloon electrode within the CS, EnSite system was replaced with Lasso catheter (20-mm diameter) to monitor the CS-RA conduction (Fig. 3B)[3]. The second origin of AT was identified at the most distal site of inner lumen of the CS. Ablation catheter was positioned to the earliest activation site. Corresponding unipolar recording showed a completely negative deflection (Fig. 4A), suggesting that the tip of the ablation catheter was located just on the focus of the second AT. RF energy was then applied repeti-

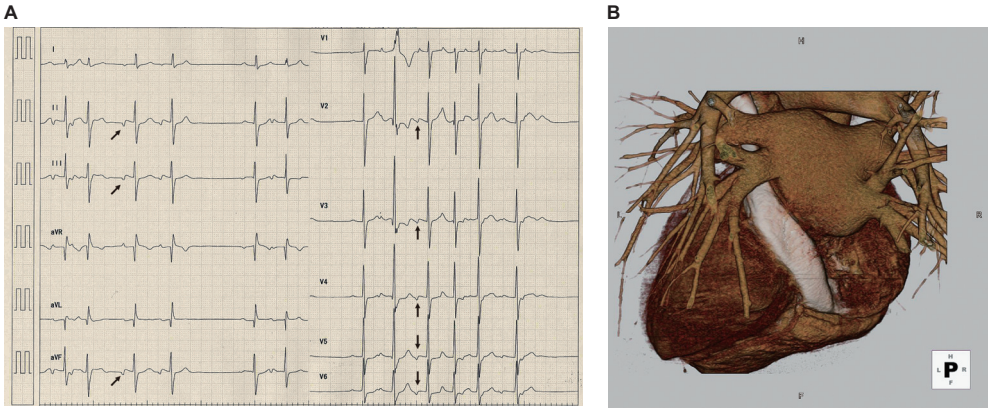

Fig. 1 A. Standard 12-lead electrocardiogram recorded after admission. P wave morphology of the premature supraventricular contractions was biphasic polarities showing sharp negative followed by positive deflections in the inferior (II, III, aV_F) and the precordial (V_2 to V_6) leads (arrows) associated with prolonged PR interval (0.24 sec). B. Three-dimensional computerized tomography conducted prior to the electrophysiological study (EPS) and radiofrequency (RF) ablation. This image showed a complex of giant coronary sinus (CS) and persistent left superior vena cava (LSVC) running on the left posterior atrioventricular groove.

Fig. 2 A. Conventional EPS demonstrated that the earliest activation of the first beat of atrial tachycardia (AT) originates from the interior of CS lumen. B. EnSite system revealed virtual electrogram (right) and left posterolateral view of the reconstructed CS (left) showing focal activation arising from the vicinity of CS ostium. C. The earliest activation was recorded by ablation catheter positioned at the CS orifice.

tively and the second focus was ablated successfully. Repetitive firing was observed immediately before the restoration of sinus rhythm (Fig. 4B), which empirically reflects the reliable ablative effects on the ectopic foci. Although ablation catheter could be advanced from CS to LSVC, the earliest potential was not observed any more at the more distal LSVC. HRA fixed pacing (S_1S_1 = 600 msec) or extrastimuli (S_1S_2 ranging from 500 to 310 msec) could not induce AT or atrial fibrillation (AF) under continuous infusion of isoproterenol. Sinoatrial conduction time was 154 to 170 msec and sinus node recovery time was 1092 msec, suggesting intact sinus node automaticity and mildly delayed sinoatrial conduction. After confirming no inducibility of arrhythmias,

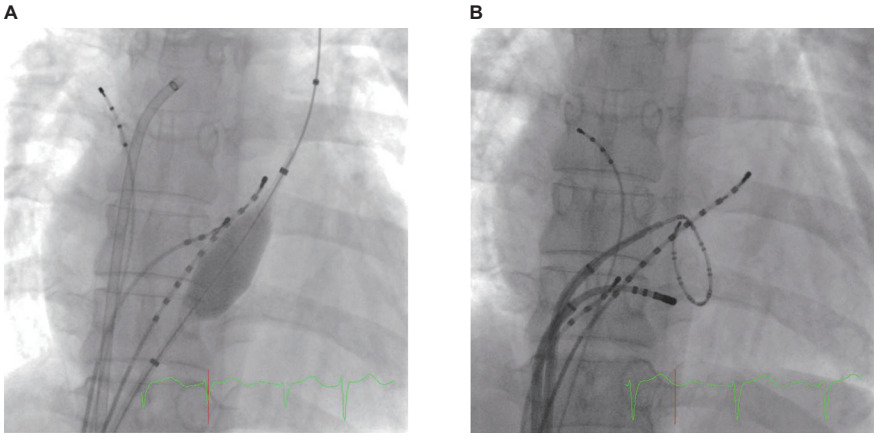

Fig. 3 Fluoroscopic images under the use of EnSite balloon (A) or Lasso catheter (B). Note that the catheter mounting EnSite balloon is positioned within the persistent LSVC.

Fig. 4 A. Ablation catheter positioned at distal CS recorded the earliest activation of the second AT, while the unipolar recording showed completely negative deflection corresponding to the earliest activation. B. RF energy was applied and repetitive CS firing was observed immediately before the restoration of sinus rhythm.

all the session was terminated. AT was not evoked by exercise without antiarrhythmic drugs and cardiomegaly was gradually restored 15 months after the RF ablation.

Discussion

RF ablation is recognized as a safe and effective treatment of tachyarrhythmias associated not only with structurally normal hearts but also with relatively simple congenital heart diseases[1)~4)]. However, RF ablation of supraventricular tachycardias in cardiac anomalies as in this case requires longer time of procedure and radiation exposure than that in structurally normal hearts[5)]. EnSite system is a promising noncontact mapping tool to navigate the ablation catheter especially for arrhythmias with hemodynamic intolerance, multiple autonomic foci, or poor inducibility, by single beat analysis[6)]. This system is helpful especially to map the inside of the diseased, structurally complicated or anomalous cardiac chambers. EnSite mapping is considered to be feasible in this case of multifocal AT, i. e., preablative CT had indicated that CS was large enough to introduce the noncontact balloon to the inside (Fig. 1B). Application of navigation system such as CARTO[1)2)] and EnSite/NavX[7)] to the inside of giant CS is extremely rare. Although EnSite-guided RF ablation was possible in this case of AT originating from the vicinity of CS orifice, another technique may be required to ablate the origin of AT arising from the distal CS lumen.

Persistent LSVC, mostly bilateral superior vena cavae, is found in 0.5% of general community, and in 3.0 to 4.3% of patients with associated cardiac malformations[8)9)]. CS anomaly such as CS atresia[4)] and connection to LSVC[3)] is found in 2.9% of patients with supraventricular tachyarrhythmias[10)]. CS wall shows vascular structure lined by several layers of cardiac cells, which demonstrate action potentials resembling that of atrial cells. In basic EPS, canine CS orifice is reported to show pronounced autonomic activity triggered by catecholaminergic agonists[11)]. In the case of bilateral superior vena cavae as reported here, persistent LSVC drains into RA through a dilated CS. CS musculature is so developed functionally and structurally that a high degree of CS rhythmicity is speculated as a remnant of primitive pacemaking tissue. In this case, exercise-induced AT was so frequent and persistent that it caused cardiac enlargement. These properties of AT and sensitivity to ATP are compatible with autonomic firing. EPS has revealed so far two foci of AT in this case (Figs. 2 and 4). This suggests structural complexity of CS architecture allowing multiple ectopic origins including actively firing foci and other dormant foci leading to possible future AT development. Moreover, reported anomalous PV-LSVC connection could not be ruled out[2)] and bilateral superior vena cavae *per se* is arrhythmogenic[7)]. Therefore, it is necessary to follow this case carefully with respect to the recurrence of AT or development of AF originating from the CS-LSVC complex.

Acknowledgement

We thank Dr. Eimei Shimoike for critical reading of the manuscript.

References

1) Dong J, Zrenner B and Schmitt C : Existence of muscles surrounding the persistent left superior vena cava demonstrated by electroanatomical mapping. Heart 88 : 4, 2002.
2) Hsu LF, Jaïs P, Keane D, Wharton JM, Deisenhofer I, Hocini M, Shah DC, Sanders P, Scavée C, Weerasooriya R, Clémenty J and Haïssaguerre M : Atrial fibrillation originating from persistent left superior vena cava. Circulation 109 : 828-832, 2004.
3) Pak HN, Lim HE and Kim YH : Atrial tachycardia originating from the coronary sinus ostium dissociated with fibrillatory activity inside persistent left superior vena cava. Heart Rhythm 2 : 333, 2005.
4) Luik A, Deisenhofer I, Estner H, Ndrepepa G, Pflaumer A, Zrenner B and Schmitt C : Atresia of the coronary sinus in patients with sup-

raventricular tachycardia. PACE 29 : 171–174, 2006.

5) Chiou CW, Chen SA, Chiang CE, Wu TJ, Tai CT, Lee SH, Cheng CC, Ueng KC, Chen CY, Wang SP, Chiang BN and Chang MS : Radiofrequency catheter ablation of paroxysmal supraventricular tachycardia in patients with congenital heart disease. Int J Cardiol 50 : 143–151, 1995.

6) Okishige K, Kawabata M, Umayahara S, Yamashiro K, Gotoh M, Isobe M and Strickberger A : Radiofrequency catheter ablation of various kinds of arrhythmias guided by virtual electrograms using a noncontact, computerized mapping system. Circ J 67 : 455–460, 2003.

7) Ratnasamy C, Idriss SF, Carboni MP and Katner RJ : Arrhythmias in children having a single left superior vena cava and minimal structural heart disease. J Cardiovasc Electrophysiol 20 : 182–186, 2009.

8) Steinberg I, Dubilier W and Lucas D : Persistence of left superior vena cava. Dis Chest 24 : 479–488, 1953.

9) Fraser RS, Dvorkin J, Rossall RE and Eidem R : Left superior vena cava: a review of associated congenital heart lesions, catheterization data, and roentgenologic findings. Am J Med 31 : 711–716, 1961.

10) Chiang CE, Chen SA, Yang CR, Cheng CC, Wu TR, Tsai DS, Chiou CW, Chen CY, Wang SP, Chiang BN and Chang MS : Major coronary sinus abnormalities: Identification of occurrence and significance in radiofrequency ablation of supraventricular tachycardia. Am Heart J 127 : 1279–1289, 1994.

11) Johnson N, Danilo P Jr, Wit AL and Rosen MR : Characteristics of initiation and termination of catecholamine-induced triggered activity in atrial fibers of the coronary sinus. Circulation 74 : 1168–1179, 1986.

(Received for publication May 8, 2009)

（和文抄録）

左上大静脈遺残に連続する巨大冠静脈洞内に起源を有した心房頻拍の一例：ノンコンタクトマッピングのガイド下でのカテーテルアブレーション

[1] 九州大学大学院医学研究院病態修復内科学
[2] 九州大学健康科学センター

中村洋文[1]，藤原昌彦[1]，中司　元[1]，安田潮人[1]，辛島詠士[1]，
平松伸一[1]，小田代敬太[1]，丸山　徹[2]，赤司浩一[1]

症例は35歳の女性で，頻回に持続する心房頻拍に対する非薬物治療のために当院に入院した．心房頻拍は薬剤抵抗性で心拡大と心機能低下を認めた．心電図では心房性期外収縮が頻発し，胸部CT検査で右房に開口する巨大冠静脈洞とこれに連続する左上大静脈遺残を認めた．臨床心臓電気生理学検査中に自然に心房頻拍が生じたがATP（20 mg）で停止した．心房性期外収縮の最早期興奮部位は肺静脈にはなく冠静脈洞起源が疑われたため，EnSiteバルーンで冠静脈洞内を慎重にマッピングした．冠静脈洞開口部に最早期興奮部位を認め初回高周波通電で心房頻拍は消失したが，その後冠静脈洞遠位部に起源を有する別の心房頻拍が出現した．EnSiteバルーン留置下での通電が手技上困難であったためEnSiteバルーンを抜去し，Lassoカテーテルで冠静脈洞開口部をマッピングして高周波通電に成功した．本例の心房頻拍は臨床電気生理学的性質やATP感受性，運動誘発性から巨大冠静脈洞内の複数起源の異所性自動能が原因と考えられた．EnSiteシステムは本例のような巨大冠静脈洞内に複数起源を有する心房頻拍のカテーテルアブレーションにおいても有用であると考えられた．