九州大学学術情報リポジトリ
Kyushu University Institutional Repository

FDG uptake heterogeneity evaluated by fractal analysis improves the differential diagnosis of pulmonary nodules

三輪, 建太

https://doi.org/10.15017/1500540

出版情報：九州大学, 2014, 博士（保健学）, 課程博士
バージョン：
権利関係：全文ファイル公表済

European Journal of Radiology 83 (2014) 715–719

Contents lists available at ScienceDirect

European Journal of Radiology

journal homepage: www.elsevier.com/locate/ejrad

FDG uptake heterogeneity evaluated by fractal analysis improves the differential diagnosis of pulmonary nodules☆

Kenta Miwa[a,b,1], Masayuki Inubushi[c,2], Kei Wagatsuma[a,3], Michinobu Nagao[d,4], Taisuke Murata[a,3], Masamichi Koyama[a,3], Mitsuru Koizumi[a,3], Masayuki Sasaki[b,*]

[a] Department of Nuclear Medicine, Cancer Institute Hospital of Japanese Foundation for Cancer Research, 3-8-31 Ariake, Koto-ku, Tokyo 135-8550, Japan
[b] Division of Medical Quantum Science, Department of Health Sciences, Graduate School of Medical Sciences, Kyushu University, 3-1-1 Maidashi, Higashi-ku, Fukuoka 812-8582, Japan
[c] Department of Nuclear Medicine, Kawasaki Medical School, 577 Matsushima Kurashiki, Okayama 701-0192, Japan
[d] Department of Molecular Imaging and Diagnosis, Graduate School of Medical Sciences, Kyushu University, 3-1-1 Maidashi, Higashi-ku, Fukuoka 812-8582, Japan

ARTICLE INFO

Article history:
Received 15 November 2013
Received in revised form
11 December 2013
Accepted 16 December 2013

Keywords:
Non-small cell lung cancer
Texture analysis
Diagnostic accuracy
^{18}F-FDG PET/CT

ABSTRACT

Purpose: The present study aimed to determine whether fractal analysis of morphological complexity and intratumoral heterogeneity of FDG uptake can help to differentiate malignant from benign pulmonary nodules.

Materials and methods: We retrospectively analyzed data from 54 patients with suspected non-small cell lung cancer (NSCLC) who were examined by FDG PET/CT. Pathological assessments of biopsy specimens confirmed 35 and 19 nodules as NSCLC and inflammatory lesions, respectively. The morphological fractal dimension (m-FD), maximum standardized uptake value (SUV_{max}) and density fractal dimension (d-FD) of target nodules were calculated from CT and PET images. Fractal dimension is a quantitative index of morphological complexity and tracer uptake heterogeneity; higher values indicate increased complexity and heterogeneity.

Results: The m-FD, SUV_{max} and d-FD significantly differed between malignant and benign pulmonary nodules ($p < 0.05$). Although the diagnostic ability was better for d-FD than m-FD and SUV_{max}, the difference did not reach statistical significance. Tumor size correlated significantly with SUV_{max} ($r = 0.51$, $p < 0.05$), but not with either m-FD or d-FD. Furthermore, m-FD combined with either SUV_{max} or d-FD improved diagnostic accuracy to 92.6% and 94.4%, respectively.

Conclusion: The d-FD of intratumoral heterogeneity of FDG uptake can help to differentially diagnose malignant and benign pulmonary nodules. The SUV_{max} and d-FD obtained from FDG-PET images provide different types of information that are equally useful for differential diagnoses. Furthermore, the morphological complexity determined by CT combined with heterogeneous FDG uptake determined by PET improved diagnostic accuracy.

© 2013 Elsevier Ireland Ltd. All rights reserved.

1. Introduction

Pulmonary nodules have recently been differentiated using F-18 fluorodeoxyglucose (FDG) positron emission tomography (PET) [1]. The maximum standardized uptake value (SUV_{max}) is a popular clinical method of evaluating the degree of FDG uptake in tumors. The SUV_{max} reflects the highest amount of FDG uptake, but not its distribution throughout tumors. The uptake of FDG is heterogeneous in some types of tumor [2]. Factors that might contribute to heterogeneous intratumoral FDG uptake such as necrosis, cellular proliferative activity, blood flow, microvessel density and hypoxia are also regarded as features of tumors [3]. Thus, characterization based on FDG uptake heterogeneity might help to distinguish benign from malignant pulmonary nodules.

☆ This study was supported in part by a Grant-in-Aid from the Clinical Research Center at the Cancer Institute Hospital of JFCR.

* Corresponding author. Tel.: +81 92 642 6746; fax: +81 92 642 6723.
E-mail addresses: kenta5710@gmail.com (K. Miwa), inubushi@med.kawasaki-m.ac.jp (M. Inubushi), kei1192@hotmail.co.jp (K. Wagatsuma), minagao@radiol.med.kyushu-u.ac.jp (M. Nagao), taisuke113@gmail.com (T. Murata), masamichi.koyama@jfcr.or.jp (M. Koyama), mitsuru@jfcr.or.jp (M. Koizumi), msasaki@hs.med.kyushu-u.ac.jp (M. Sasaki).
[1] Tel.: +81 3 3570 0204/92 642 6746; fax: +81 3 3570 0204/92 642 6674.
[2] Tel.: +81 86 461 1111; fax: +81 86 462 1199.
[3] Tel: +81 3 3570 0204; fax: +81 3 3570 0204.
[4] Tel.: +81 92 641 1151; fax: +81 92 641 1151.

0720-048X/$ – see front matter © 2013 Elsevier Ireland Ltd. All rights reserved.
http://dx.doi.org/10.1016/j.ejrad.2013.12.020

Table 1
Characteristics of pulmonary nodules.

	Histological type	Lesions (n)	Tumor diameter (mm)		SUV_{max}	
			Means ± SD	Range	Means ± SD	Range
Malignant	Adenocarcinoma	23	17.7 ± 7.7	7.8–38.2	5.2 ± 3.7	1.2–14.6
	Squamous cell carcinoma	9	23.4 ± 8.4	12.8–36.6	10.0 ± 5.5	4.5–19.1
	Large cell carcinoma	2	30.0 ± 21.4	14.9–45.1	10.8 ± 9.1	4.4–17.3
	Adenosquamous carcinoma	1	15.9	15.9	7.6	7.6
Benign	Pneumonia	12	20.8 ± 11.6	6.5–40.2	3.4 ± 1.5	1.1–6.9
	Tuberculosis	4	18.5 ± 10.8	9.3–33.6	4.7 ± 2.8	1.1–7.5
	Radiation pneumonia	3	24.5 ± 7.3	18.7–32.7	3.2 ± 1.3	2.2–4.7

Fractal analysis is one method of quantifying tumor complexity and heterogeneity on various types of images [4–8]. Nagao et al. developed a method of quantifying the heterogeneity of nuclear medicine images using density fractal dimension and found it useful for evaluating cerebral blood flow distribution on SPECT [9] and the heterogeneity of ^{99m}Tc-technegas distribution in the lung [10]. Here, we applied fractal analysis to FDG-PET images to determine the fractal dimension of pulmonary tumor heterogeneity. To our knowledge, this is the first effort to determine whether fractal analysis applied to FDG-PET/CT can differentiate malignant and benign pulmonary nodules.

2. Materials and methods

2.1. Patients

We retrospectively analyzed FDG PET/CT data from 54 patients (37 men, and 17 women; mean age, 70 ± 9 years; age range, 31–88 y) with suspected non-small cell lung cancer (NSCLC). Thirty-five and 19 biopsy specimens of nodules were confirmed as NSCLC and inflammatory lesions, respectively (Table 1). This clinical study was approved by the ethics committee of our institution (no. 25-54). This study was retrospective, and its results did not influence further therapeutic decision-making.

2.2. FDG PET/CT

Patients fasted for at least 6 h before being injected with 4 MBq/kg FDG and then whole body image acquisition started at a mean of 60 min later from the top of the skull to the mid-thigh using an Aquiduo PET/CT scanner (Toshiba, Japan). Emission data were acquired for 2–3 min per bed position. The PET images were reconstructed using an iterative algorithm (attenuation-weighted ordered-subsets expectation maximization: 4 iterations, 14 subsets) with an 8-mm Gaussian filter, a 128 × 128 matrix (3.9 mm/pixel) and 81 slices (2 mm/slice). Whole-body CT scanning proceeded under the following parameters: 120 kV; auto exposure control system (noise level: SD 10); 512 × 512 matrix; beam pitch, 0.94; 2 mm × 16-row mode.

2.3. Fractal analysis

Fractal geometry is characterized by the relationship between a measure (M) and a scale (ε), expressed as:

$$M(\varepsilon) = k \cdot \varepsilon^{-D},$$

where k is a scaling constant and D is the fractal dimension that that is used to detect self-affinity. The morphological fractal dimension (m-FD) is a quantitative index of morphological complexity derived from CT on PET/CT, with higher values corresponding to increasing degrees of complexity. The heterogeneity of FDG distribution is expressed as the density fractal dimension (d-FD), of which higher values correspond to increasing degrees of heterogeneity. In d-FD, the chosen cut-offs were used as the ruler scale ε in the above equation. The number of voxels containing with radioactivity higher than the corresponding cut-offs are expressed as $M(\varepsilon)$, in which M decreases as ε increases and the magnitude of the slope of linear regression between the logarithms of the cut-offs and the numbers of pixels is equal to the fractal dimension.

2.4. Quantitative analysis

We evaluated transaxial PET images of maximal cross-sectional diameters of nodules. A circular region of interest (ROI) with the minimal diameter required to cover the entire nodule was created. The highest pixel value was determined as the SUV_{max} of the nodule. To calculate the d-FD, the cut-offs for maximal image intensity in the nodule were set at 30 levels ranging from 40% to 100% at intervals of 2% and then the number of pixels exceeding the cut-off was calculated. The m-FD was calculated from the extracted boundary of the lesion derived from CT images using the box-counting method [11].

2.5. Statistical analysis

We compared m-FD, SUV_{max} and d-FD between malignant and benign pulmonary nodules using an unpaired t test. Relationships between tumor size and m-FD, SUV_{max} and d-FD were evaluated using Pearson's correlation coefficients. Values plotted nearest the upper left corner from receiver operating characteristics analyses (ROC) were considered to indicate the best diagnostic accuracy. Sensitivity, specificity and accuracy were calculated using appropriate cut-offs. Diagnostic accuracy was also compared using areas under ROC curves (AUC) and ROC curves were compared using critical z testing. All data were statistically analyzed using software (SPSS Inc., USA) and $p < 0.05$ was considered to indicate statistical significance.

3. Results

Fig. 1 compares the m-FD, SUV_{max} and d-FD between malignant and benign pulmonary nodules. The m-FD and d-FD were significantly lower and the SUV_{max} was significantly higher in malignant, than in benign nodules (all $p < 0.05$). Fig. 2 shows relationships between tumor size and m-FD, SUV_{max} and d-FD. Tumor size significantly correlated with SUV_{max} ($p < 0.05$), but not with either m-FD or d-FD.

The optimal cut-off values for differentiating malignant from benign pulmonary nodules were 1.183, 4.24 and 0.0267 for m-FD, SUV_{max} and d-FD, respectively. The diagnostic accuracy of SUV_{max} (68.5%) and d-FD (77.8%) on PET was better that that of m-FD on CT (64.8%). The diagnostic accuracy tended to be higher for d-FD than for SUV_{max}, but the difference did not reach statistical significance. Fig. 3 shows the outcomes of the ROC analyses for each index. The AUCs of m-FD, SUV_{max} and d-FD were 0.597, 0.79 and 0.827, respectively, and did not significantly differ (Table 2). The

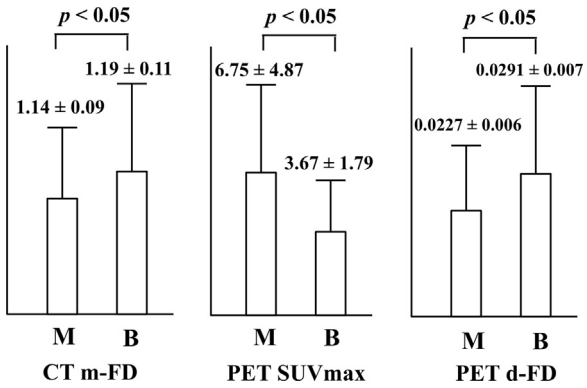

Fig. 1. Comparison of values for m-FD, SUV_{max} and d-FD between malignant and benign pulmonary nodules. Values for m-FD and d-FD are significantly lower, whereas that of SUV_{max} is significantly higher in malignant, than benign nodules (all $p < 0.05$). B, benign; M, malignant.

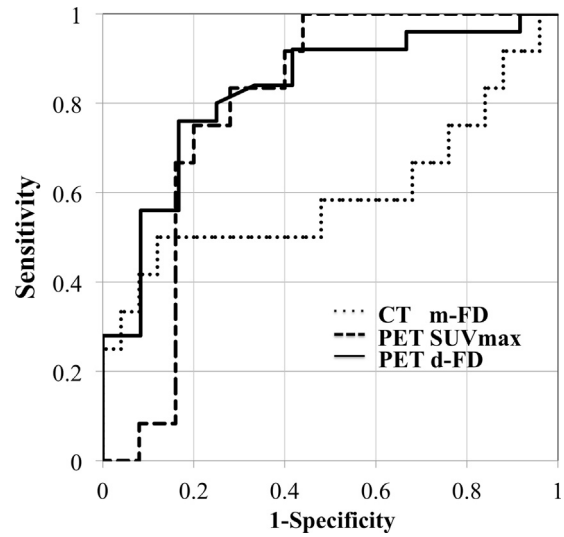

Fig. 3. Receiver-operating-characteristic curves of ability of m-FD, SUV_{max} and d-FD to distinguish malignant from benign pulmonary nodules. Areas under curves for m-FD, SUV_{max} and d-FD are 0.597, 0.79 and 0.827, respectively (NS). Cutoff values for m-FD, SUV_{max} and d-FD are 1.183, 4.24 and 0.0267, respectively.

combined use of m-FD and either SUV_{max} or d-FD for the differential diagnosis between benign and malignant was also examined. We adopted criteria that malignancy should be suspected if either diagnosis was positive. Table 2 shows that combining m-FD with either SUV_{max} or d-FD improved accuracy to 92.6% and, 94.4%. Representative images are shown in Fig. 4. The m-FD and d-FD were significantly higher in benign, than in malignant nodules although the SUV_{max} values of both nodules were similar (Fig. 4).

4. Discussion

Fractal analysis evaluates the spatial pattern of irregular objects so that the morphological complexity and spatial heterogeneity can

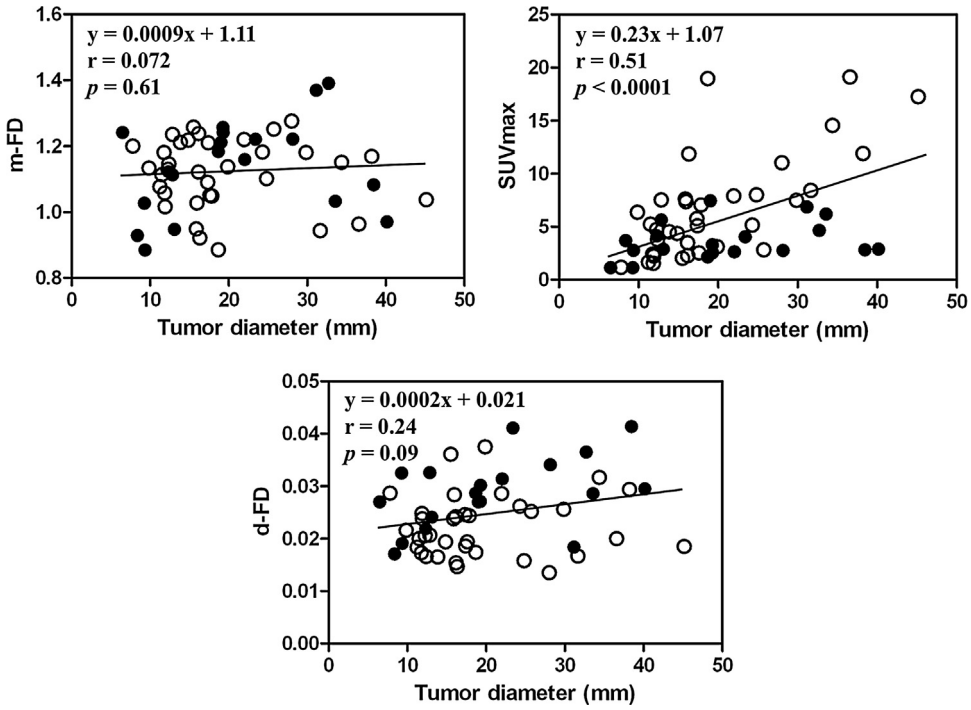

Fig. 2. Relationship between pulmonary nodule size and m-FD, SUV_{max} and d-FD. Tumor size significantly correlates with SUV_{max} ($r = 0.51$, $p < 0.05$), whereas m-FD and d-FD do not. ○, lung cancer; ●, benign lesions.

Table 2
Comparison of diagnostic ability.

	CT m-FD	PET SUV_{max}	PET d-FD	CT + PET m-FD + SUV_{max}	CT + PET m-FD + d-FD
AUC	0.597	0.790	0.825	–	–
Cutoff	1.183	4.240	0.0267	–	–
Sensitivity	71.4%	65.7%	80.0%	94.3%	94.2%
Specificity	47.4%	72.7%	73.7%	89.5%	94.7%
Accuracy	62.9%	68.5%	77.8%	92.6%	94.4%

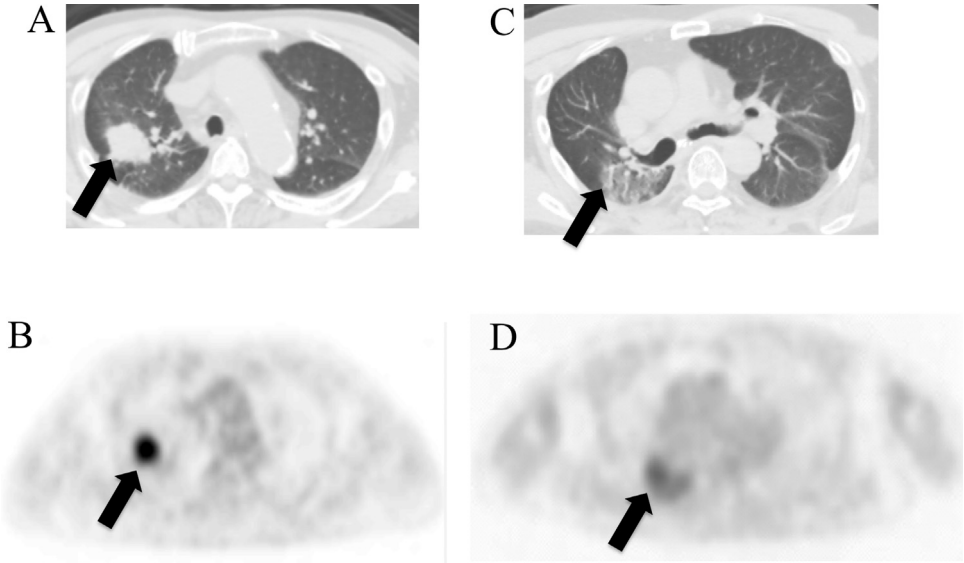

Fig. 4. Representative CT and axial PET images of adenocarcinoma and pneumonia. (A) CT scan shows mass in right upper lobe of 68-year-old male with adenocarcinoma (m-FD, 1.162). (B) Axial PET image shows high FDG uptake (SUV_{max}, 5.767) and homogeneous FDG distribution (d-FD, 0.0158). (C) CT image of 79-year-old male with pneumonia shows mass-like attenuation in right middle lobe (m-FD, 1.325). (D) Axial PET image shows high FDG uptake in lesion (SUV_{max}, 5.824) and heterogeneous FDG distribution (d-FD, 0.0413).

be quantified and assigned numerical values [12,13]. Intratumoral heterogeneity in FDG-PET images has been evaluated using textural analysis [14–16], the coefficient of variance (COV) [2], cumulative SUV-volume histograms (CSH) [17] and the area under the CSH (AUC–CSH) [2,18]. The advantage of fractal analysis is the accurate quantitation of highly sensitive, reproducible values that can be used to evaluate the specific characteristics of tumors [7,19]. Repeated fractal analysis of the same image can theoretically result in assigning an agreement value [7].

Although the m-FD, SUV_{max} and d-FD could differentiate between malignant and benign, the diagnostic ability was higher for both SUV_{max} and d-FD than for m-FD. Metabolic information obtained from FDG-PET imaging is generally superior to morphological information obtained from CT for differential diagnoses of pulmonary nodules [20]. We found that the diagnostic ability of d-FD was better than that of the SUV_{max}, but not significantly. The SUV_{max} is considered to reflect the most biologically aggressive area, but this value is influenced by the spatial resolution of the images [21]. We identified a positive correlation between tumor size and the SUV_{max}. On the other hand, d-FD did not correlate with tumor size. These results indicate that the SUV_{max} and d-FD obtained from FDG-PET images provide different information and are equally useful for differential diagnosis [22].

The d-FD was lower for malignant, than benign pulmonary nodules. Yu et al. performed a textural analysis of head and neck cancer and found lower heterogeneity in tumors and nodes than in normal tissue [23]. Higher FDG uptake heterogeneity in benign pulmonary nodules is thought to reflect metabolically diverse components including inflammatory tissues and surrounding normal tissues such as vessels, bronchi and pleura. In the same context, van Velden et al. [18] proposed a quantitative index of intratumoral FDG uptake heterogeneity with which to evaluate NSCLC responses to treatment, whereas Tixier et al. [14] showed that the intratumoral heterogeneity of FDG uptake could predict responses of esophageal cancer to radio-chemotherapy.

The usefulness of the combination morphological complexity and heterogeneity of FDG uptake has not been reported. The combination of m-FD and d-FD significantly improved diagnostic accuracy associated with a significant reduction in false-positive findings. Yu et al. also reported that co-registered FDG-PET/CT-based analysis was useful for the differential diagnosis of head and neck cancer [23]. These findings suggest a complementary relationship between morphological complexity and the heterogeneity of FDG uptake. Thus, the combination of m-FD and d-FD might improve the accuracy of diagnosing pulmonary nodules.

This study had some limitations. The FD may be influenced by various histological types of tumors and inflammatory conditions. Further studies of more patients with various types of tumors are required. Image noise and a partial volume effect due to the limited spatial resolution of PET might have influenced the results [18]. Therefore, the FD should be calculated from PET/CT images acquired under identical conditions using the same equipment.

5. Conclusions

The intratumoral heterogeneity of FDG uptake evaluated by fractal analysis was useful for discriminating benign, from malignant pulmonary nodules. The SUV_{max} and intratumoral heterogeneity determined from PET images provided different types of information that are equally useful for differential diagnosis. Furthermore, combining the morphological complexity of tumors on CT images with the heterogeneity of FDG uptake on PET images improved diagnostic accuracy.

Conflicts of interest

The authors declare that they have no conflict of interest.

Acknowledgements

The authors thank the staff of the Department of Radiology and Nuclear Medicine at Cancer Institute Hospital of Japanese Foundation for Cancer Research (JFCR) for providing valuable clinical support.

References

[1] Kim SK, Allen-Auerbach M, Goldin J, et al. Accuracy of PET/CT in characterization of solitary pulmonary lesions. J Nucl Med 2007;48:214–20.
[2] Watabe T, Tatsumi M, Watabe H, et al. Intratumoral heterogeneity of F-18 FDG uptake differentiates between gastrointestinal stromal tumors and abdominal malignant lymphomas on PET/CT. Ann Nucl Med 2012;26:222–7.
[3] Sugama C, Vicky G, Musib S, et al. Quantifying tumour heterogeneity in 18F-FDG PET/CT imaging by texture analysis. Eur J Nucl Med Mol Imaging 2013;40:133–40.
[4] Mandelbrot B. How long is the coast of Britain? Statistical self-similarity and fractal dimension. Science 1967;156:636–8.
[5] Smith Jr TG, Lange GD, Marks EB. Fractal methods and results in cellular morphology: dimensions, lacunarity and multifractals. J Neurosci Methods 1996;69:123–36.
[6] Kamiya A, Takahashi T. Quantitative assessments of morphological and functional properties of biological trees based on their fractal nature. J Appl Physiol 2007;102:2315–23.
[7] Sanghera B, Banerjee D, Khan A, et al. Reproducibility of 2D and 3D fractal analysis techniques for the assessment of spatial heterogeneity of regional blood flow in rectal cancer. Radiology 2012;263:865–73.
[8] Kido S, Sasaki S. Fractal analysis for the assessment of pulmonary blood flow on chest radiographs. J Thorac Imaging 2003;18:80–6.
[9] Nagao M, Sugawara Y, Ikeda M, et al. Heterogeneity of posterior limbic perfusion in very early Alzheimer's disease. Neurosci Res 2006;55:285–91.
[10] Nagao M, Murase K, Ichiki T, et al. Quantitative analysis of Technegas SPECT: Evaluation of regional severity of emphysema. J Nucl Med 2000;41:590–5.
[11] Russel U, Hanson JD, Ott E. Dimension of strange attractors. Phys Rev Lett 1980;45:1175–8.
[12] Lopes R, Betrouni N. Fractal and multifractal analysis: a review. Med Image Anal 2009;13:634–49.
[13] Haitao S, Ning L, Lijun G, et al. Fractal dimension analysis of MDCT images for quantifying the morphological changes of the pulmonary artery tree in patients with pulmonary hypertension. Korean J Radiol 2011;12:289–96.
[14] Tixier F, Cheze Le Rest C, Hatt M, et al. Intratumor heterogeneity characterized by textural features on baseline ^{18}F-FDG PET images predicts response to concomitant radiochemotherapy in esophageal cancer. J Nucl Med 2011;52:369–78.
[15] Cook GJ, Yip C, Siddique M, et al. Are pretreatment ^{18}F-FDG PET tumor textural features in non-small cell lung cancer associated with response and survival after chemoradiotherapy? J Nucl Med 2013;54:19–26.
[16] Vaidya M, Creach KM, Frye J, et al. Combined PET/CT image characteristics for radiotherapy tumor response in lung cancer. Radiother Oncol 2012;102:239–45.
[17] El Naqa I, Grigsby P, Apte A, et al. Exploring feature-based approaches in PET images for predicting cancer treatment outcomes. Pattern Recognit 2009;42:1162–71.
[18] van Velden FH, Cheebsumon P, Yaqub M, et al. Evaluation of a cumulative SUV-volume histogram method for parameterizing heterogeneous intratumoural FDG uptake in non-small cell lung cancer PET studies. Eur J Nucl Med Mol Imaging 2011;38:1636–47.
[19] Dimitrakopoulou-Strauss A, Strauss G, Heichel L, et al. The role of quantitative ^{18}F-FDG PET studies for the differentiation of malignant and benign bone lesions. J Nucl Med 2002;43:510–8.
[20] Kubota K, Murakami K, Inoue T, et al. Additional effects of FDG-PET to thin-section CT for the differential diagnosis of lung nodules: a Japanese multicenter clinical study. Ann Nucl Med 2011;25:787–95.
[21] Srinivas SM, Dhurairaj T, Basu S, et al. A recovery coefficient method for partial volume correction of PET images. Ann Nucl Med 2009;34:341–8.
[22] Henriksson E, Kjellen E, Wahlberg P, et al. 2-Deoxy-2-[18F] fluoro-D-glucose uptake and correlation to intratumoral heterogeneity. Anticancer Res 2007;27:2155–9.
[23] Yu H, Caldwell C, Mah K, et al. Coregistered FDG PET/CT-based textural characterization of head and neck cancer for radiation treatment planning. IEEE Trans Med Imaging 2009;28:374–83.