Activation of the Akt/mTOR pathway in myxofibrosarcomas

髙橋，祐介

https://doi.org/10.15017/1456002

出版情報：九州大学，2014，博士（医学），課程博士
バージョン：

Elsevier Editorial System(tm) for Human Pathology
Manuscript Draft

Manuscript Number: YHUPA-D-13-00789R1

Title: Activation of the Akt/mTOR pathway in myxofibrosarcomas

Article Type: Original Article

Keywords: myxofibrosarcoma, Akt, mTOR, MAPK

Corresponding Author: Dr. Yoshinao Oda, MD, PhD

Corresponding Author's Institution: Kyushu University, Graduate School of Med. Sciences

First Author: Yoshinao Oda, MD, PhD

Order of Authors: Yoshinao Oda, MD, PhD; Yusuke Takahashi, MD; Kenichi Kohashi, MD, PhD; Yuichi Yamada, MD; Makoto Endo, MD, PhD; Nokitaka Setsu, MD, PhD; Takeaki Ishii, MD; Hidetaka Yamamoto, MD, PhD; Yukihide Iwamoto, MD, PhD

Abstract: The Akt/mammalian target of rapamycin (mTOR) pathway plays important roles in modulating cellular function in response to extracellular signals such as growth factors and cytokines. The Akt/mTOR signaling pathway is activated in certain kinds of sarcomas. Myxofibrosarcoma is a soft tissue sarcoma, characterized by abundant myxoid stroma and frequent local recurrence. Here, we conducted a large-scale examination of the clinicopathologic and activation statuses of the Akt/mTOR pathways in myxofibrosarcoma. The phosphorylation status of Akt, mTOR, S6RP, and the eukaryotic translation initiation factor 4E-binding protein (4E-BP1) and MEK were assessed by immunohistochemistry in 101 formalin-fixed paraffin-embedded samples, including 68 primary tumors in myxofibrosarcoma. Immunohistochemical expressions were confirmed by Western blotting with 20 frozen samples, which were paired with normal tissue samples. PIK3CA and AKT1 gene mutation were also analyzed using 12 primary tumor frozen samples. Immunohistochemically, phosphorylations of Akt, mTOR, S6RP, 4E-BP1 and MEK1/2 were observed in 64.7%, 45.6%, 42.6%, 63.2% and 64.7% of samples. Phosphorylated Akt/mTOR pathway proteins were correlated with one another and were also correlated with the phosphorylation of these protiens in the concordant recurrent tumors. Immunoblotting showed a high degree of phosphorylation in tumor samples, compared with that in normal tissue samples. Activation of the Akt/mTOR pathway was correlated with histological grade and tumor progression. Mutational analysis failed to reveal any PIK3CA or AKT1 mutations around the hot spots. Activation of the Akt/mTOR pathway was associated with histological malignancy and tumor progression in primary and recurrent myxofibrosarcoma.

Activation of the Akt/mTOR pathway in myxofibrosarcomas

Yusuke Takahashi MD[a], Kenichi Kohashi MD, PhD[a], Yuichi Yamada MD[a], Makoto Endo MD, PhD[a], Nokitaka Setsu MD, PhD[a], Takeaki Ishii MD[a], Hidetaka Yamamoto MD, PhD[a], Yukihide Iwamoto MD, PhD[b], Yoshinao Oda MD, PhD[a].

[a]*Department of Anatomic Pathology, Graduate School of Medical Sciences, Kyushu University, Maidashi 3-1-1, Higashi-ku, Fukuoka 812-8582, Japan*

[b]*Department of Orthopedic Surgery, Graduate School of Medical Sciences, Kyushu University, Maidashi 3-1-1, Higashi-ku, Fukuoka 812-8582, Japan*

Corresponding author: Yoshinao Oda, Department of Anatomic Pathology, Pathological Sciences, Graduate School of Medical Sciences, Kyushu University, Maidashi 3-1-1, Higashi-ku, Fukuoka 812-8582, Japan

E-mail: oda@surgpath.med.kyushu-u.ac.jp

Tel: +81-92-642-6061; FAX: +81-92-642-5968

Address reprint requests to Yoshinao Oda, Department of Anatomic Pathology, Pathological Sciences, Graduate School of Medical Sciences, Kyushu University, Maidashi 3-1-1, Higashi-ku, Fukuoka 812-8582, Japan

E-mail: oda@surgpath.med.kyushu-u.ac.jp

Tel: +81-92-642-6061; FAX: +81-92-642-5968

Running title: Akt/mTOR pathway in myxofibrosarcoma

Abstract

The Akt/mammalian target of rapamycin (mTOR) pathway plays important roles in modulating cellular function in response to extracellular signals such as growth factors and cytokines. The Akt/mTOR signaling pathway is activated in certain kinds of sarcomas. Myxofibrosarcoma is a soft tissue sarcoma, characterized by abundant myxoid stroma and frequent local recurrence. Here, we conducted a large-scale examination of the clinicopathologic and activation statuses of the Akt/mTOR pathways in myxofibrosarcoma. The phosphorylation status of Akt, mTOR, S6RP, and the eukaryotic translation initiation factor 4E-binding protein (4E-BP1) and MEK were assessed by immunohistochemistry in 101 formalin-fixed paraffin-embedded samples, including 68 primary tumors in myxofibrosarcoma. Immunohistochemical expressions were confirmed by Western blotting with 20 frozen samples, which were paired with normal tissue samples. *PIK3CA* and *AKT1* gene mutation were also analyzed using 12 primary tumor frozen samples. Immunohistochemically, phosphorylations of Akt, mTOR, S6RP, 4E-BP1 and MEK1/2 were observed in 64.7%, 45.6%, 42.6%, 63.2% and 64.7% of samples. Phosphorylated Akt/mTOR pathway proteins were correlated with one another and were also correlated with the phosphorylation of these protiens in the concordant recurrent tumors. Immunoblotting showed a high degree of phosphorylation in tumor samples, compared with that in normal tissue samples. Activation of the Akt/mTOR pathway was correlated with histological grade and tumor progression. Mutational analysis failed to reveal any *PIK3CA* or *AKT1* mutations around the hot spots. Activation of the Akt/mTOR pathway was associated with histological malignancy and tumor progression in primary and recurrent myxofibrosarcoma.

Key words: myxofibrosarcoma, Akt, mTOR, MAPK

1. Introduction

Myxofibrosarcoma is a soft tissue sarcoma with fibroblastic/myofibroblastic differentiation, characterized by abundant myxoid stroma and frequent local recurrence. With respect to the genetic characteristics of myxofibrosarcoma, progression in grade is accompanied by an increased cytogenetic aberration, and also associated with more distinct cytomorphologic features in the recurrent tumors [1]. Surgical resection is a curative treatment chosen for myxofibrosarcoma cases, while no effective systemic therapy is currently available for primary unresectable or recurrent tumors.

The Akt/mTOR pathway plays important roles in modulating cellular function in response to extracellular signals such as growth factors and cytokines [2]. Akt is a serine/threonine kinase that is activated (phosphorylated) by phosphoinositide 3-kinase (PI3K) and that activates (phosphorylates) the downstream molecules in turn. Mammalian target of rapamycin (mTOR) is one of the downstream targets of Akt and is a key factor in the Akt/mTOR pathway. mTOR activates p70S6 kinase (p70S6K) and S6 ribosomal protein (S6RP), and inhibits the 4E binding protein 1 (4E-BP1). mTOR activation causes protein synthesis, which induces cellular proliferation, survival, motility, invasion, and differentiation, and can ultimately lead to tumor initiation and progression [3].

The Ras/Raf/mitogen-activated protein kinase (MEK)/extracellular signal-regulated kinase (ERK) pathway, also known as the MAPK pathway, also regulates a variety of cell functions, including proliferation, growth, and survival [4]. There is known to be cross-talk between the Akt/mTOR and MAPK pathways; for example, Ras can activate the PI3K/Akt/mTOR pathway

in addition to the Raf/MEK/ERK pathway; indeed, ERK can activate mTOR. The Akt/mTOR and MAPK pathways are activated in certain kinds of sarcomas [5-8].

Here, we conducted a large-scale examination of the clinicopathologic and activation statuses of the Akt/mTOR and MAPK pathways, such as phosphorylated Akt, mTOR, S6RP, 4E-BP1 and MEK, and also analyzed the Akt1 and PIK3CA gene mutations by direct gene sequencing, in 101 clinical specimens from patients with myxofibrosarcoma.

2. Materials and Methods

2.1. Patients

One hundred and -one paraffin-embedded specimens consisting of 68 primary and 33 recurrent patients were retrieved from the registry of the Department of Anatomic Pathology, Kyushu University, Japan between 1976 and 2010. The diagnosis of myxofibrosarcoma was made according to the latest edition of the World Health Organization classification [1]. Clinical details and follow-up information were obtained by medical charts.

All the primary tumors were treated surgically, followed by adjuvant irradiation in only one case. Histopathologically, the grades of tumor malignancy were judged as low-, intermediate- or high-grade, according to the WHO classification: high-grade tumors showed a great number of pleomorphic cells, and mitoses, and necrosis; intermediate-grade tumors lacked necrosis and nuclear pleomorphism, but had higher cellularity than low-grade tumors; low-grade tumors were composed of spindle-shaped cells with hypocellular and myxoid areas [1]. In addition, the

histological grading of the Federation Nationale des Centres de Lutte Contre le Cancer (FNCLCC) grading system was also adopted [1], which classifies myxofibrosarcomas in FNCLCC differentiation score 2. Tumor necrosis and mitotic figures are divided into three groups according to the FNCLCC grading system: tumor necrosis: none, <50%, ≧50%; mitotic figures: 0-9 mitoses per 10 HPF, 10-19 mitoses per 10HPF, >19 mitoses per 10HPF. For the staging of the primary tumors, we used the latest 4-tier staging system from the American Joint Committee on Cancer (AJCC) (6th and 7th edition of the AJCC staging) [10]. Follow-up information was available in 57 out of the 68 primary cases. The median follow-up period after surgery was 49 months (range: 1-153 months). Immunohistochemical expression of phosphorylated Akt/mTOR and MAPK pathway was compared between the periphery and the central portion of individual samples from 21 primary tumors. The institutional review board at Kyushu University approved this study (permission code 25-143).

2.2. Immunohistochemistry

Immunohistochemical staining was performed for 68 primary tumors and 33 recurrent tumors in the same way as described previously [16]. In 12 cases, both primary and concordant recurrent tumors were analyzed. The sections were pretreated with Target Retrieval Solution (Dako, Glostrup, Denmark) in a microwave oven at 100ºC for 20 minutes before being incubated with monoclonal antibodies of p-Akt (Ser473, 1:50 dilution), p-mTOR (Ser2448, 1:50), p-S6RP(Ser235/236, 1:50), p-4E-BP1 (Thr37/46, 1:50), or p-MEK1/2 (Ser221, 1:50) at 4ºC overnight. All the above antibodies were supplied by Cell Signaling Technology (Danvers, MA).

The immune complex was detected with a DAKO EnVision Detection System (Dako, Glostrup, Denmark).

Immunohistochemical positivity was evaluated in the area of greatest expression, irrespective of the location, at the periphery or the central portion of the tumor. Coexistent endothelial cells were evaluated as a positive internal control. As a negative control, the primary antibody was omitted. The percentage of immunoreactive cells and staining intensity compared with those of the endothelial cells adjacent to the tumor cells were evaluated in the most representative areas, with reference to the evaluation method of Dobashi and a previous report [5,6]. The proportion of significantly immunoreactive cells was scored from 0 to 2: 0, <10%; 1, 10% to 50%; 2, >50%; and the intensity of immunoreactive cells was scored from 1 to 3: 1, weak staining; 2, intermediate staining; 3, strong staining.

The tumors were judged as positive for the phosphorylation antibodies if more than 10% of tumor cells were positively-stained in primary and recurrent tumors, according to the method used in previous reports [8,11]. In addition, intensity was assessed in the comparison between primary and recurrent tumors, and was also compared between the periphery and central portion of individual tumors.

Immunohistochemical results were judged by three investigators (Y.T., K.K. and Y.O.), who were blinded to the clinical status of the patients. If the independent assessments did not agree, the slides were reviewed together in order to achieve consensus. The consensus judgments were adopted as the final immunohistochemical results.

2.3. Western blotting analysis

Western blotting (WB) analysis was performed in 20 frozen samples (8 primary tumors and 12 recurrent tumors) as previously described [16,30]. Comparative analysis between a primary and its concordant recurrent tumor was available in 4 cases. Monoclonal antibodies of phospho-Akt (p-Akt) (Ser473, 1:500 dilution), p-mTOR (Ser2448,1:500), p-S6RP (Ser235/236, 1:500), p-4E-BP1 (Thr37/46, 1:500), and p-MEK1/2 (Ser221, 1:500) were applied. All the above antibodies were provided by Cell Signaling Technology. The obtained data were standardized by using data on the Actin expression level. The final numerical ratio in each sample was calculated as follows: p-score. (p-Akt normal soft tissue (N) expression level/Actin expression level (N)) x100, (p-Akt tumor (T) expression level/Actin expression level (T)) x100. Immunohistochemical positivity for each antibody showing positivity by western blotting was estimated as the ratio of the tumor (T) to the normal soft tissue (N); T/N>1.

2.4. Mutational Analysis

DNA was extracted by using a Qiagen DNA Mini Kit (QIAGEN, Valencia, Calif). The primer sequences are summarized in Table 1. They were synthesized by the Genenet Co. (Fukuoka, Japan), with partial reference to the primers of Dunlap et al [24]. *PIK3CA* exons 9 and 20 and *Akt1* exon 2 were amplified by polymerase chain reaction (PCR) in 12 primary cases with frozen materials at an annealing temperature of 57-ºC. Bidirectional sequencing was performed on an ABI 3130 sequencer by the Big-Dye terminator method using the same primers as used for PCR (Table 1).

2.5. Statistical analysis

The Chi-square test was used to evaluate the association between the variables. Overall survival was adopted as the end point for survival analyses. Survival curves were calculated by the Kaplan-Meier method, and the statistical significance of the numerical differences was assessed by the log-rank test. Cox proportional-hazards regression analysis was performed to estimate the hazard ratios for positive risk factors for death. Statistical significance was defined as $p < 0.05$. Data analysis was performed with the JMP statistical software package (version 9.0.2; SAS Institute Inc., Cary, NC).

3. Results

3.1. Clinical and pathologic features

The clinicopathological features of the 68 primary tumors are summarized in Table 2. The tumor samples were taken from 38 males and 30 females, whose ages ranged from 29 to 91 years (mean: 66.9 years). The tumors were 10 to 200 mm in maximum diameter (median: 76 mm). The tumors from 43 cases (63%) were located in superficial sites, and the other tumors were located in deep soft tissue (subfascial or even deeper). In 47 cases the tumors were in the extremities (thigh 22, upper arm 7, lower leg 13, forearm 5), in 18 cases they were in the trunk wall or limb girdles (back 3, buttock 6, shoulder 4, chest wall 5), in 3 cases they were in the head and neck. Microscopically, all the tumors were composed of oval- to spindle-shaped cells arranged in a sparse, fascicular or solid pattern, accompanied by focal-to diffuse abundant myxoid stroma and

fine slit-like vessels. Pleomorphic tumor cells with bizarre nuclei were observed with varying frequency.

According to the WHO grading system, there were 18 low-grade tumors (26%) (Fig. 1A), 14 intermediate-grade tumors (21%) (Fig. 1B) and 36 high-grade tumors (53%) (Fig. 1C). By FNCLCC grade, 18 cases (26%) were categorized in FNCLCC grade 1, 33 cases (49%) were in grade 2, and 17 cases (25%) were in grade 3.

Statistical analysis of the clinicopathological features revealed that tumor depth (superficial vs deep: p=0.0053**), histological grade (p=0.0079**; Fig. 2(a)), FNCLCC grading system (p=0.0307**; Fig. 2(b)), and AJCC staging (6th edition) (p=0.0309**; Fig. 2(c)) were significant prognostic factors for overall survival, based on univariate analysis with the log rank test. Mitotic activity seemed to be poor prognostic factors; however, no statistical significance was confirmed by univariate analysis with the log rank test. No clinicopathologic factors were significantly associated with event free survival. Multivariate analysis was performed, but the statistical significance was not obtained.

3.2. Immunohistochemical findings

Myxofibrosarcoma cells in the primary tumors showed cytoplasmic and/or nuclear staining for p-Akt (44/68 cases, 64.7%; Fig. 3A), p-mTOR (31/68 cases, 45.6%; Fig. 3B), p-S6RP (29/68 cases, 42.6%; Fig. 3C), p-4E-BP1 (43/68 cases, 63.2%; Fig. 3D), and p-MEK1/2 (44/68 cases, 64.7%). Phosphorylation of S6RP and 4E-BP1 phosphorylation, presumably mediated by phosphorylated-Akt and phosphorylated-mTOR was in 19.1% for S6RP and in 25% for 4E-BP1.

Phosphorylation three or all of the Akt/mTOR pathway proteins was observed in 16% of the cases. The statistical correlation of the immunohistochemical results with the clinicopathological variables is summarized in Table 3.

Immunohistochemical positivity for p-mTOR and p-4E-BP1 was correlated with FNCLCC high-grade tumors (grade 1 and grade 2 vs grade 3: p=0.0161**, p=0.0085**), and also advanced stages in the AJCC 7th edition staging (I vs III: p=0.0291**, p=0.0179**; I and II vs III: p=0.0176**, p=0.0030**). p-4E-BP1 was also correlated with mitotic activity (0-9 vs ≧10: p=0.0086**; 0-9 vs ≧20: p=0.025**). Positive staining for p-MEK was correlated with the higher WHO histological grading: high-grade vs intermediate- and low-grade (H vs I+L; p=0.0048**), high- and intermediate-grade vs low grade (H+I vs L; p=0.0213**). FNCLCC grading system (grade 1 vs grade 2 and grade 3; p=0.0213**) and AJCC staging (6th edition: I vs III, p=0.0062**; I vs II and III, p=0.0121**) (7th edition: I vs II and III, p=0.0121**) (Table 2).

Significant correlations were obtained between the immunohistochemical phosphorylation of the Akt/mTOR pathway: p-Akt vs p-mTOR or p-MEK (p=0.0421**, p=0.0186**), p-mTOR vs p-4E-BP1 (p=0.0245*) and p-S6RP vs p-4E-BP1 (p=0.0031**), as shown in Table 3. Recurrent tumors also showed positive staining for p-Akt (22/33 cases, 66.7%), p-mTOR (23/33 cases, 69.7%), p-S6RP (17/33 cases, 51.5%), and p-4E-BP1 (20/33 cases, 60.6%). In the comparative analysis of immunoreactivity between primary and recurrent tumors, no significant difference in intensity or proportion of immunoreactive cells was observed between 12 recurrent tumors and their concordant primary tumor. Immunoreactivity seemed to be higher scores in the primary tumor rather than recurrent tumor, but there was no statistical significance (p-Akt:

primary/recurrent = 2.7±0.6/2.5±0.6; p-mTOR: primary/recurrent = 2.4±0.6/2.0±0.6; p-4E-BP1: primary/recurrent = 3.0±0.7/2.0±0.7; p-S6RP: primary/recurrent = 2.4±0.7/2.2±0.7).

Immunohistochemical positivity in the periphery of the tumor was also assessed (p-Akt (76%), p-mTOR (62%), p-S6RP (48%), p-4E-BP1 (76%)) and immunoreactivity was also compared with the central portion of the same tumor. There was no difference in the activation or expression of each protein between the periphery and central portion of the same tumor.

In both univariate and multivariate analysis revealed no statistical significant difference in the prognosis among the different protein phosphorylations. Immunohistochemical results of survival analysis are summarized in Table 3.

3.3. Western blotting analysis

Immunoreactivity for each antibody was confirmed by WB (Fig. 4A, 4B). The protein scores of p-Akt, p-mTOR, p-4E-BP1 and p-S6RP were higher in the tumor samples than in the corresponding normal tissue, although there was no statistical significance: p-Akt, tumor/normal = 2.3±0.9/1.2±2.4; p-mTOR, tumor/normal = 2.8±0.7/0.6±0.6; p-4E-BP1, tumor/normal = 2.4±0.5/1.2±0.9; p-S6RP, tumor/normal = 4.1±0.6/3.1±1.0. In the comparative analysis between primary and concordant recurrent tumors, p-Akt and p-mTOR showed higher scores in the recurrent tumor than the primary tumor, but there was no statistical significace (p-Akt: primary/recurrent = 2.2±1.3/3.3±1.3; p-mTOR: primary/recurrent = 0.5±1.1/1.9±1.1). p-4E-BP1 and p-S6RP showed lower scores in the recurrent tumor than primary tumor, but the

difference was not significant (p-4E-BP1: primary/recurrent = 5.9±3.3/3.1±3.3; p-S6RP: primary/recurrent = 2.5±1.1/1.0±1.1).

The phosphorylation levels in the WB analysis closely corresponded to the positivity in the immunohistochemical (IHC) staining analysis of the primary tumor (p-mTOR, p-4E-BP1, p-S6RP) and recurrent tumor (p-Akt, p-mTOR, p-4E-BP1, p-S6RP), but there was no statistical significance; primary tumor; (p-mTOR: IHC (+)/IHC (-): 1.9±0.8/0.6±0.9; p-4E-BP1: IHC (+)/IHC (-): 2.2±0.6/1.7±1.1; p-S6RP: IHC (+)/IHC (-): 3.4±1.1/4.0±0.6), recurrent tumor; (p-Akt: IHC(+)/IHC(-) : 1.2±0.6/1.6±1.3; p-mTOR: IHC (+)/IHC (-): 4.3±1.2/0.4±2.7; p-4E-BP1: IHC(+)/IHC(-): 4.3±2.6/2.8±2.2; p-S6RP: IHC(+)/IHC(-): 0.7±0.3/0.6±0.4). p-Akt was immunohistochemically positive in all eight primary tumors.

3.4. Mutation analysis

We found no gene mutation around the hot spots in *Akt1* (E17) or *PIK3CA* (E542, E545, and H1047) by direct DNA sequencing analyses in the 12 analyzed cases.

4. Discussion

Myxofibrosarcoma has a propensity for local recurrence as a result of its infiltrative growth pattern, and the incidence of local recurrence is not influenced by the depth of the primary lesion [12]. However, in the current study, in deep-seated neoplasms, the incidence of metastases was higher and the deep-seated lesions tended to be higher-grade and larger tumors [12]. In our study,

overall survival was influenced by depth as in the previous study, and was also influenced by histological grade (WHO classification and FNCLCC grade) and AJCC staging, supporting the usefulness of the histological grading systems according to the WHO classification, FNCLCC grades and AJCC staging system. These factors were proposed to be a prognostic factor in myxofibrosarcoma.

The Akt/mTOR signaling pathway appeared to play a central role in the development of the different cancers, such as hepatocellular carcinoma, lung adenocarcinoma and breast carcinoma [13,15,21]. In small numbers of various bone and soft tissue tumors, Dobashi et al. also found that Akt was frequently activated and may have some role in metastasis [6]. In addition, our group revealed that the Akt/mTOR signaling pathway was activated and was correlated with worse clinical course and pathological features in a large series of leiomyosarcomas and malignant peripheral nerve sheath tumors, and in the same series we also reported that the Akt/mTOR pathway was activated in leiomyosarcomas and malignant peripheral nerve sheath tumors in about 70% and 50% of the cases, respectively [5,16]. Activation and association of the Akt/mTOR pathway were also represented some kind of sarcoma in vitro, proved its validity of the clinical specimens [16,31,32]. In the present study, 42.6% to 64.7% of the primary tumors showed phosphorylation of Akt/mTOR pathway proteins (p-Akt (64.7%), p-mTOR (45.6%), p-S6RP (42.6%), p-4E-BP1 (63.2%)) and the phosphorylated proteins were correlated with one another, which indicates activation of the Akt/mTOR pathway in myxofibrosarcomas. Immunohistochemical phosphorylation and expression of the Akt/mTOR pathway in the recurrent tumor was nearly stable, compared with those in the primary tumors. As for the

relationship of the Akt/mTOR pathway with the clinicopathological features, significant correlations were demonstrated between Akt/mTOR pathway activation and either histological grade or tumor progression, as assessed by FNCLCC grading or AJCC staging.

Activation of MAP kinase in colon and breast cancers [27], point mutation of *Akt1* or *PIK3CA* in breast cancer and hepatocellular carcinoma [21,24], or point mutation of IGF-1 [17] and K-ras [18] was reported in the past. However, no gene mutations of *Akt1* or *PIK3CA* were detected in myxofibrosarcoma, as previously demonstrated in leiomyosarcomas [5]. We demonstrated a significant correlation of p-MEK with p-Akt, suggesting that the MAPK pathway might be an alternative pathway to activate the Akt/mTOR pathway proteins. Further comprehensive analysis of the upstream factors such as receptor tyrosin kinases or another signaling pathway is required.

The mTOR inhibitor, RAD001 (everolimus) has been proven to be effective in several human neoplasms [19,20], and the clinical trial of this agent was performed in soft tissue sarcoma cases [26]. Ridaforolimus, as an mTOR inhibitor, demonstrated significantly prolonged progression-free survival in a clinical trial targeting advanced soft tissue sarcomas including leiomyosarcomas [26]. Myxofibrosarcoma and malignant peripheral nerve sheath tumor were not described in the report [26]. Our group also revealed the clinical and therapeutic implications of the mTOR inhibitor in leiomyosarcomas and malignant peripheral nerve sheath tumors [5,16]. In the present study, activation of the Akt/mTOR pathway was correlated with histological grade and tumor progression, and p-Akt and p-mTOR phosphorylation also appeared not only in the primary but also in recurrent tumors. Thus, mTOR inhibitors may be potential therapeutic agents

in myxofibrosarcomas.

In conclusion, we revealed the activation of the Akt/mTOR pathway in myxofibrosarcomas, and the MAPK pathway as an alternative activator of the Akt/mTOR pathway, and the activation of Akt/mTOR pathway was associated with the histological malignancy and tumor progression. The Akt/mTOR pathway has the potential to be a therapeutic target of primary and recurrent myxofibrosarcomas.

Acknowledgments

Y.O. is supported by a Grant-in-Aid for Scientific Research (B) (No. 25293088) from the Japan Society for the Promotion of Science/ KAKENHI

The English language in this paper was revised by KN International (http://www.kninter.com/).

Disclosure/conflict of interest

The authors declare no conflict of interest.

References

[1] Christopher D.M. Fletcher, Julia A. Bridge, Pancras C.W. Hogendoorn, et al. World Health Organization Classification Tumours WHO Classification of Tumours of Soft Tissue and Bone. Lyon: IARC Press, 2013.

[2] Altomare DA, Testa JR. Perturbations of the AKT signaling pathway in human cancer. Oncogene. 2005;24:7455-64.

[3] Hsieh AC, Liu Y, Edlind MP, et al. The translational landscape of mTOR signalling steers cancer initiation and metastasis. Nature. 2012;485(7396):55-61.

[4] Dasari A, Messersmith WA. New strategies in colorectal cancer: biomarkers of response to epidermal growth factor receptor monoclonal antibodies and potential therapeutic targets in phosphoinositide 3-kinase and mitogen-activated protein kinase pathways. Clin Cancer Res. 2010;16:3811-8.

[5] Setsu N, Yamamoto H, Kohashi K, et al. The Akt/mammalian target of rapamycin pathway is activated and associated with adverse prognosis in soft tissue leiomyosarcomas. Cancer. 2012;118:1637-48.

[6] Dobashi Y, Suzuki S, Sato E, et al. EGFR-dependent and independent activation of Akt/mTOR cascade in bone and soft tissue tumors. Mod Pathol. 2009;22:1328-40.

[7] Dobashi Y, Suzuki S, Sugawara H, et al. Involvement of epidermal growth factor receptor and downstream molecules in bone and soft tissue tumors. Hum Pathol. 2007;38:914-25.

[8] Tomita Y, Morooka T, Hoshida Y, et al. Prognostic significance of activated AKT

expression in soft-tissue sarcoma. Clin Cancer Res. 2006;12:3070-7.

[9] Weiss SW, Goldblum JR, editors. Enzinger and Weiss's Soft Tissue Tumors. 5th ed. St. Louis: Mosby; 2008.

[10] Edge SB, Byrd DR, Compton CC, editors. AJCC Cancer Staging Manual. 7th ed. New York: Springer; 2010.

[11] Generali D, Fox SB, Brizzi MP, Allevi G, et al. Down-regulation of phosphatidylinositol 3'-kinase/AKT/molecular target of rapamycin metabolic pathway by primary letrozole-based therapy in human breast cancer. Clin Cancer Res.2011;17:5901-12.

[12] Mentzel T, Calonje E, Fletcher CD, et al. Myxofibrosarcoma. Clinicopathologic analysis of 75 cases with emphasis on the low-grade variant. Am J Surg Pathol. 1996 Apr;20(4):391-405.

[13] Balsara BR, Pei J, Mitsuuchi Y, et al. Frequent activation of AKT in non-small cell lung carcinomas and preneoplastic bronchial lesions. Carcinogenesis. 2004;25:2053-2059.

[14] Nathan CO, Amirghahari N, Abreo F, et al. Overexpressed eIF4E is functionally active in surgical margins of head and neck cancer patients via activation of the Akt/mammalian target of rapamycin pathway. Clin Cancer Res. 2004;10:5820-5827.

[15] Lin HJ, Hsieh FC, Song H, Lin J. Elevated phosphorylation and activation of PDK-1/AKT pathway in human breast cancer. Br J Cancer. 2005;93:1372-1381.

[16] Endo M, Yamamoto H, Kohashi K, et al. Prognostic significance of AKT/mTOR and MAPK pathways and antitumor effect of mTOR inhibitor in NF1-related and sporadic malignant peripheral nerve sheath tumors. Clin Cancer Res. 2013 Jan 15;19(2):450-61.

[17] Rikhof B, de Jong S, Suurmeijer AJ, et al. The insulin-like growth factor system and

sarcomas. J Pathol. 2009;217:469-482.

[18] Uchida A, Hirano S, Kitao H, et al. Activation of downstream epidermal growth factor receptor (EGFR) signaling provides gefitinib-resistance in cells carrying EGFR mutation. Cancer Sci. 2007;98:357-363.

[19] Motzer RJ, Escudier B, Oudard S, et al. Efficacy of everolimus in advanced renal cell carcinoma: a double-blind, randomised, placebo-controlled phase III trial. Lancet. 2008;372:449-456.

[20] Soria JC, Shepherd FA, Douillard JY, et al. Efficacy of everolimus (RAD001) in patients with advanced NSCLC previously reated with chemotherapy alone or with chemotherapy and EGFR inhibitors. Ann Oncol. 2009;20:1674-1681.

[21] Lee JW, Soung YH, Lee SH et al. PIK3CA gene is frequently mutated in breast carcinomas and hepatocellular carcinomas. Oncogene, 2005: 24: 1477–1480.

[22] Whittaker S, Marais R, Zhu AX et al. The role of signaling pathways in the development and treatment of hepatocellular carcinoma. Oncogene. 2010; 29:4989-5005.

[23] Friedrichs N, Trautmann M, Czerwitzki J, et al. Phosphatidylinositol-3'-kinase/AKT signaling is essential in synovial sarcoma. Int J Cancer. 2011;129:1564-75.

[24] Dunlap J, Le C, Shukla A, et al. Phosphatidylinositol-3-kinase and AKT1 mutations occur early in breast carcinoma. Breast Cancer Res Treat. 2010;120:409-418.

[25] Rikhof B, de Jong S, van der Graaf WT, et al. The insulin-like growth factor system and sarcomas. J Pathol. 2009;217:469-482.

[26] Chawla SP, Staddon AP, Tolcher et al. Phase II study of the mammalian target of rapamycin

inhibitor ridaforolimus in patients with advanced bone and soft tissue sarcomas. J Clin Oncol. 2012;30:78-84.

[27] Carracedo A, Ma L, Teruya-Feldstein J, et al. Inhibition of mTORC1 leads to MAPK pathway activation through a PI3K-dependent feedback loop in human cancer. J Clin Invest. 2008;118:3065-74.

[28] Oda Y, Takahira T, Kawaguchi K, Tsuneyoshi M, et al. Low-grade fibromyxoid sarcoma versus low-grade myxofibrosarcoma in the extremities and trunk. A comparison of clinicopathological and immunohistochemical features. Histopathology. 2004;45:29-38.

[29] Oda Y, Takahira T, Tsuneyoshi M, et al. Altered expression of cell cycle regulators in myxofibrosarcoma, with special emphasis on their prognostic implications. Hum Pathol. 2003;34:1035-42.

[30] Endo M, Kobayashi C, Setsu N, et al. Prognostic significance of p14ARF, p15INK4b, and p16INK4a inactivation in malignant peripheral nerve sheath tumors. Clin Cancer Res. 2011;17:3771-82.

[31] Friedrichs N, Trautmann M, Endl E, et al. Phosphatidylinositol-3'-kinase/AKT signaling is essential in synovial sarcoma. Int J Cancer. 2011;129:1564-75.

[32] Gazitt Y, Kolaparthi V, Moncada K, et al. Targeted therapy of human osteosarcoma with 17AAG or rapamycin: characterization of induced apoptosis and inhibition of mTOR and Akt/MAPK/Wnt pathways. Int J Oncol.2009 ;34:551-61.

Figure legends

Figure 1

Microscopic histological features and each histological grade of myxofibrosarcoma are shown: (A) low grade, (B) intermediate grade, (C) high grade.

Figure 2

Analysis of clinicopathological parameters. Overall survival was analyzed with the following: (a) Histological grade in WHO (low-grade, intermediate-grade, high-grade), (b) FNCLCC grading system (grade 1, grade 2, grade 3), (c) AJCC staging (6th edition) (I, II, III, IV), Analysis of the groups and statistically significant results are showen in the figure.

Figure 3

The results of immunohistochemical study are shown: (A) p-Akt, (B) p-mTOR, (C) p-S6RP, and (D) p-4E-BP1. Immunostaining for each antibody was recognized mainly in the cytoplasm and immunostaining of endothelial cells. These figures were prepared from a high grade resected myxofibrosarcoma specimen of the thigh from same patient (A-D).

Figure 4

Phosphorylated (p) Akt was detected in all the tumor samples. The obtained data were standardized by using data on the Actin expression level. The final numerical ratio in each sample was calculated as follows: p-score (pAkt normal soft tissue (N) expression level/Actin

expression level (N)) x100, (pAkt tumor (T) expression level/Actin expression level (T)) x100.

Table 1

Primer Sequences Used in the Polymerase Chain Reaction for Mutation Screening

Table 2

Clinicopathological Parameters and Survival Analysis in 68 Primary Tumors

Table 3

Immunohistochemical Results and Statistical Analysis

Figure(s)
Click here to download high resolution image

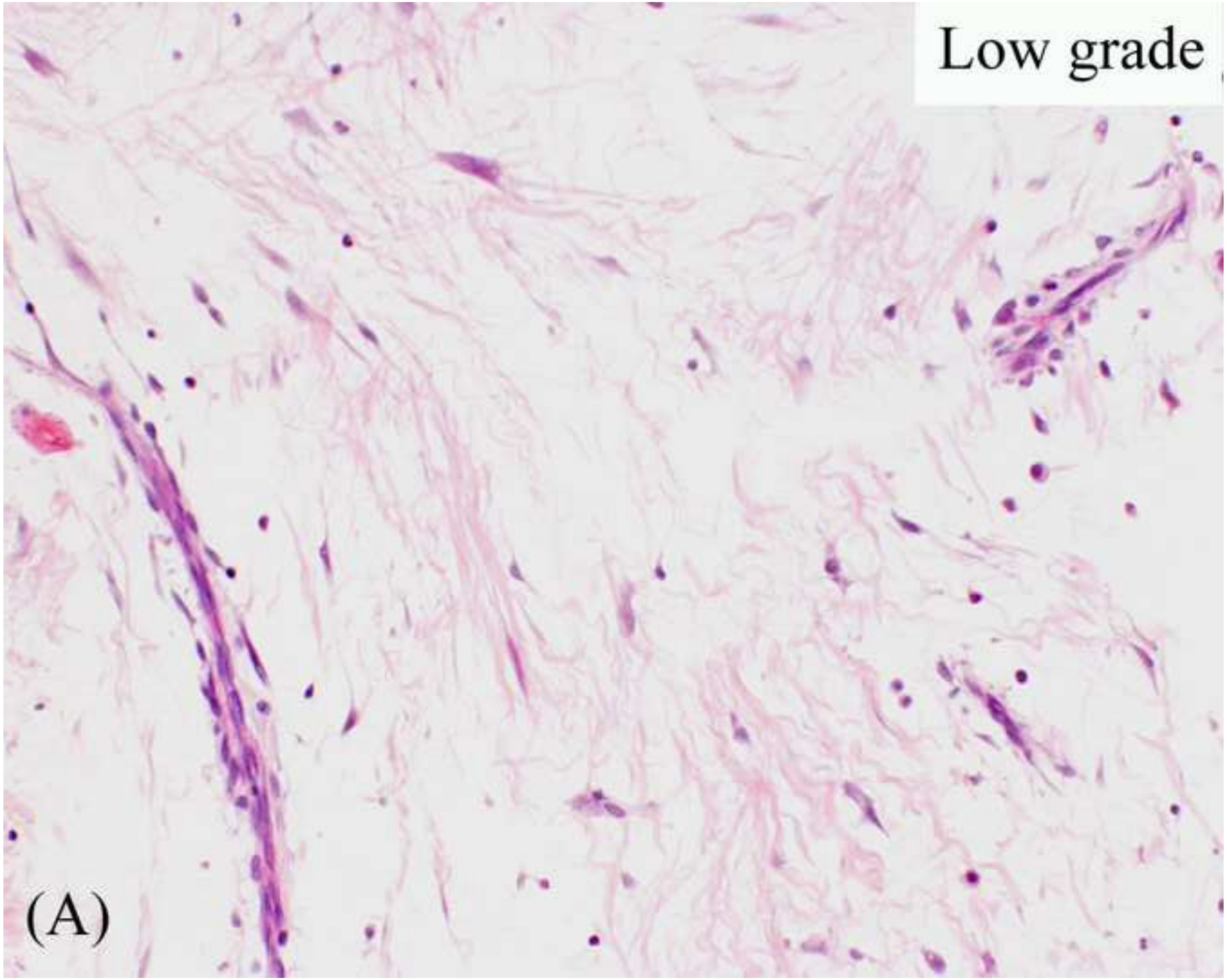

Figure(s)
Click here to download high resolution image

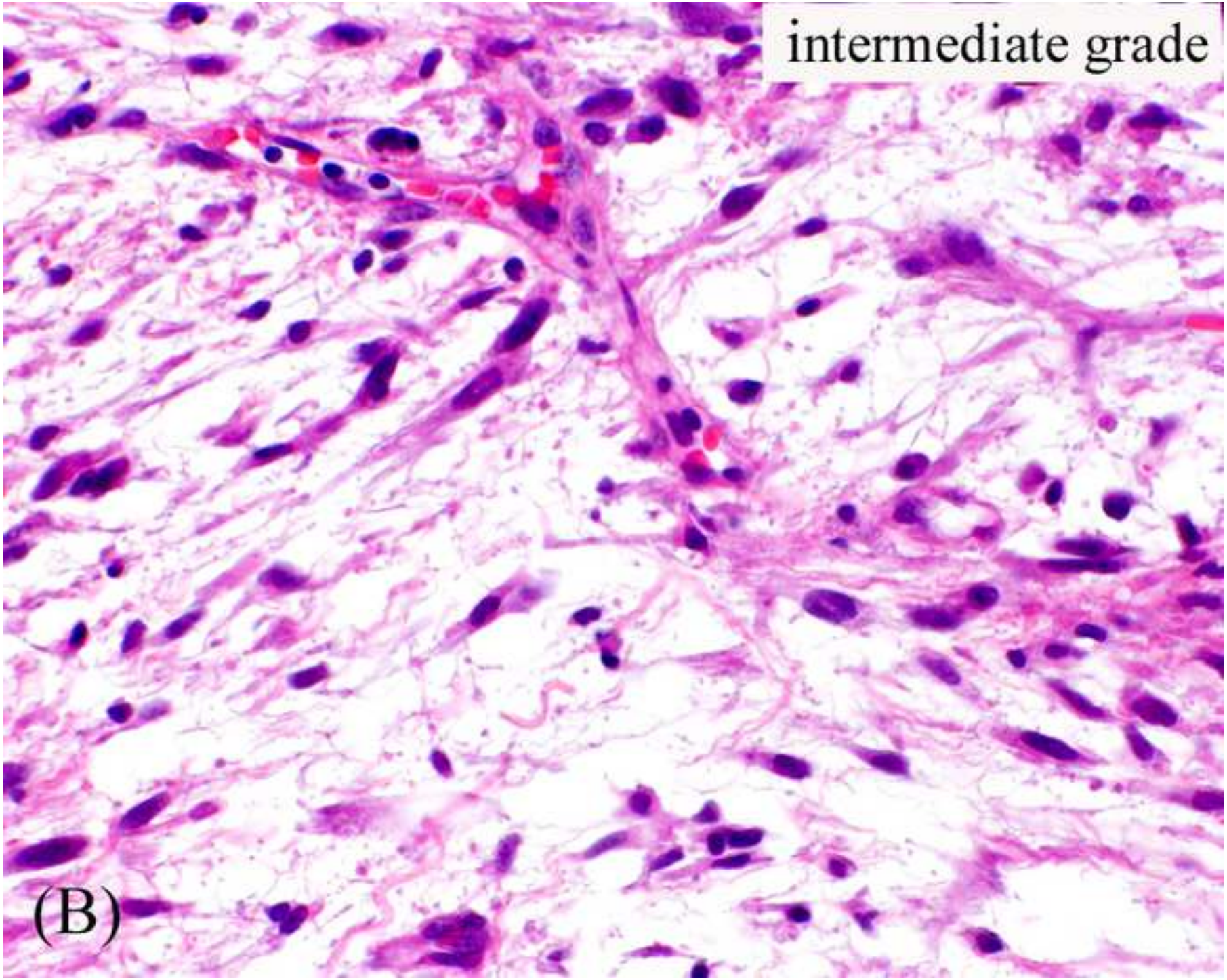

Figure(s)
Click here to download high resolution image

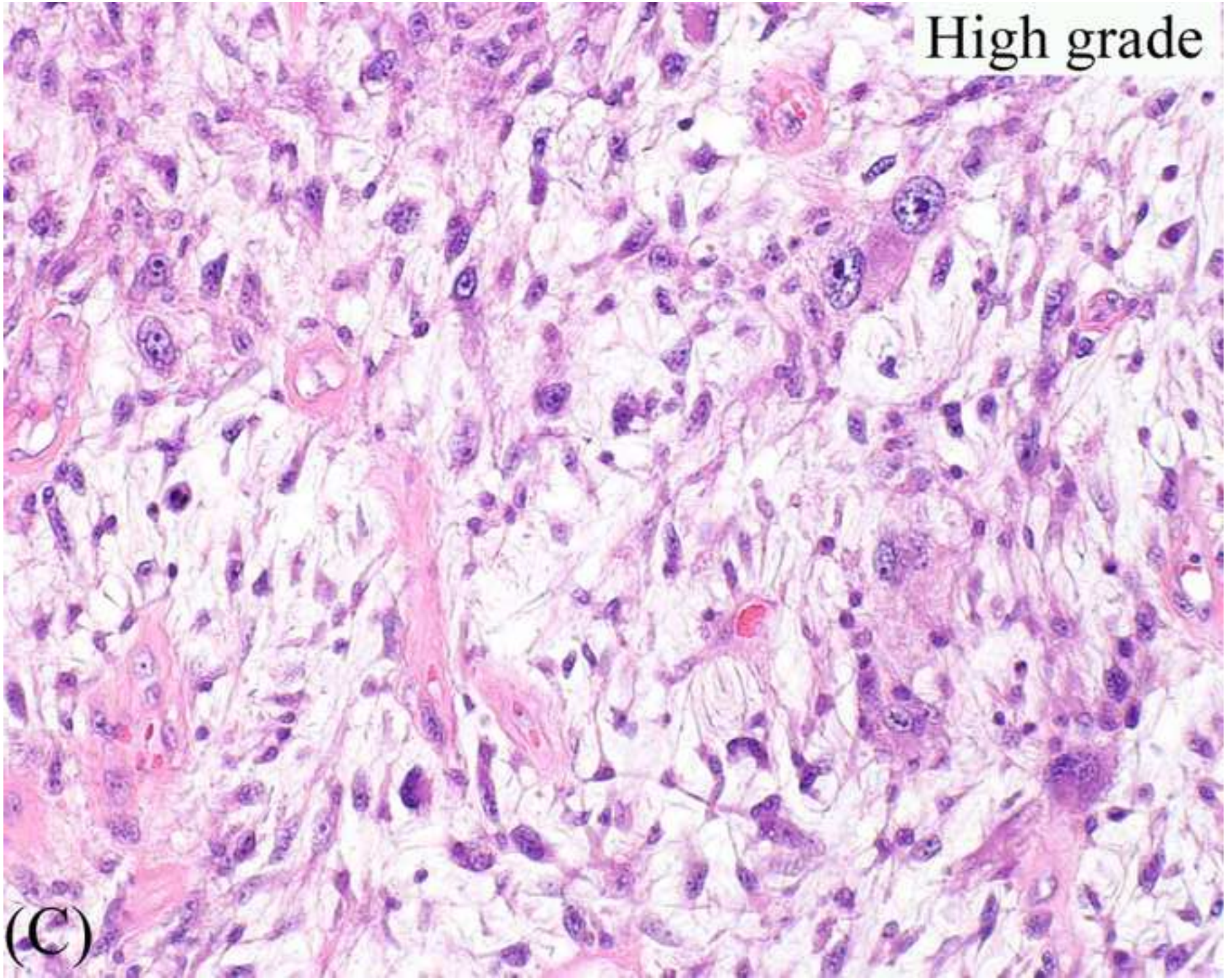

Figure(s)
Click here to download high resolution image

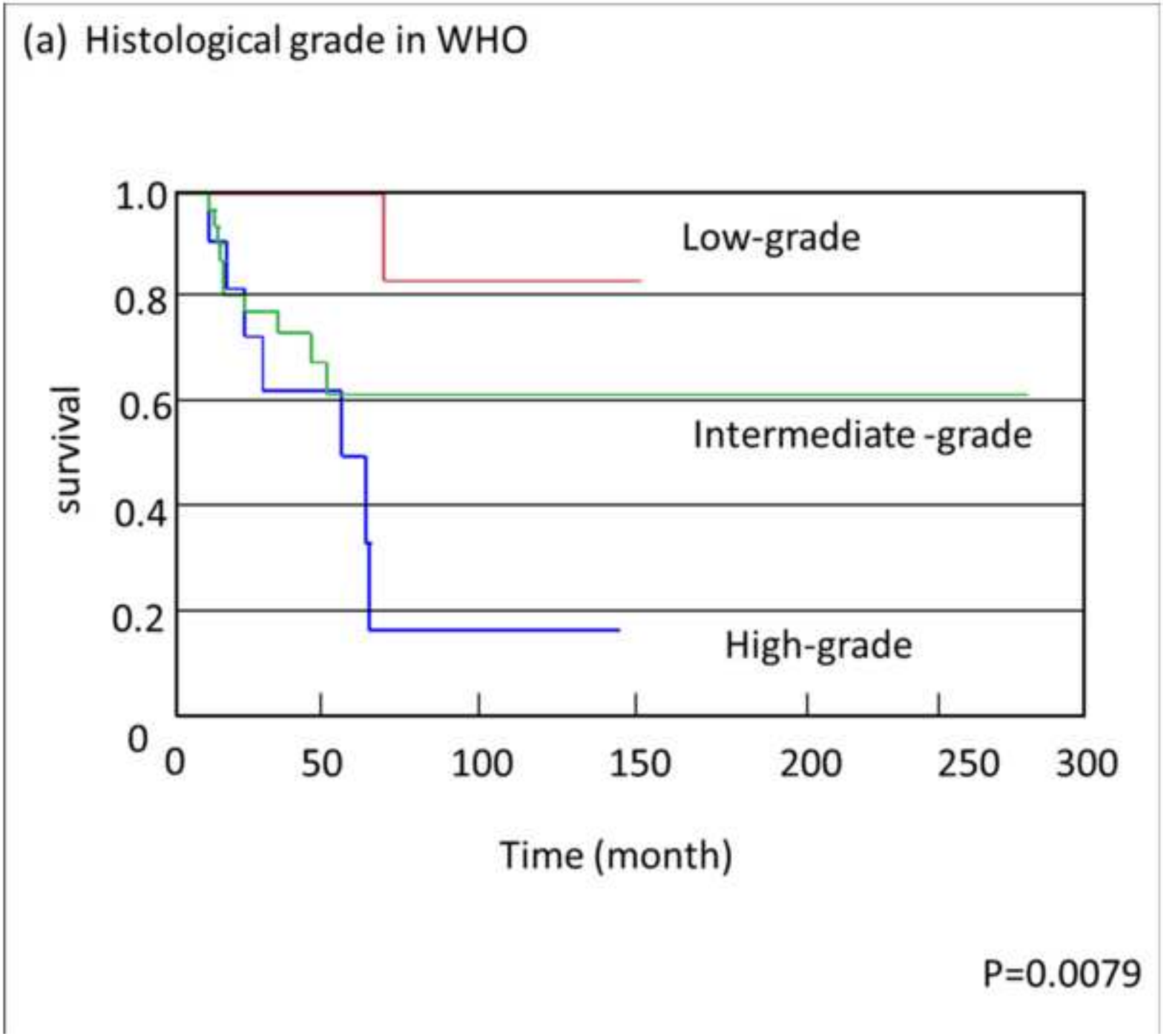

Figure(s)
Click here to download high resolution image

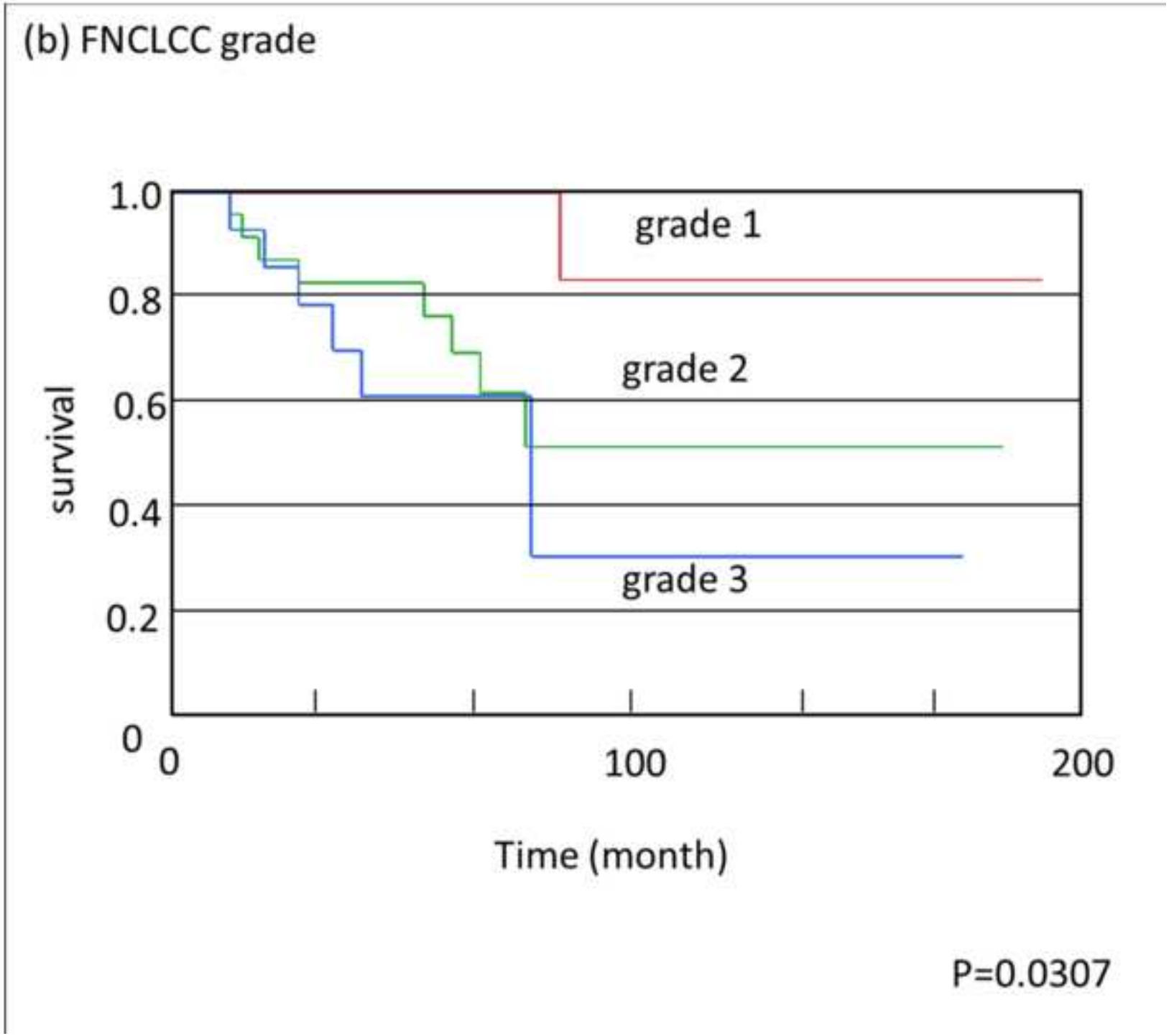

Figure(s)
Click here to download high resolution image

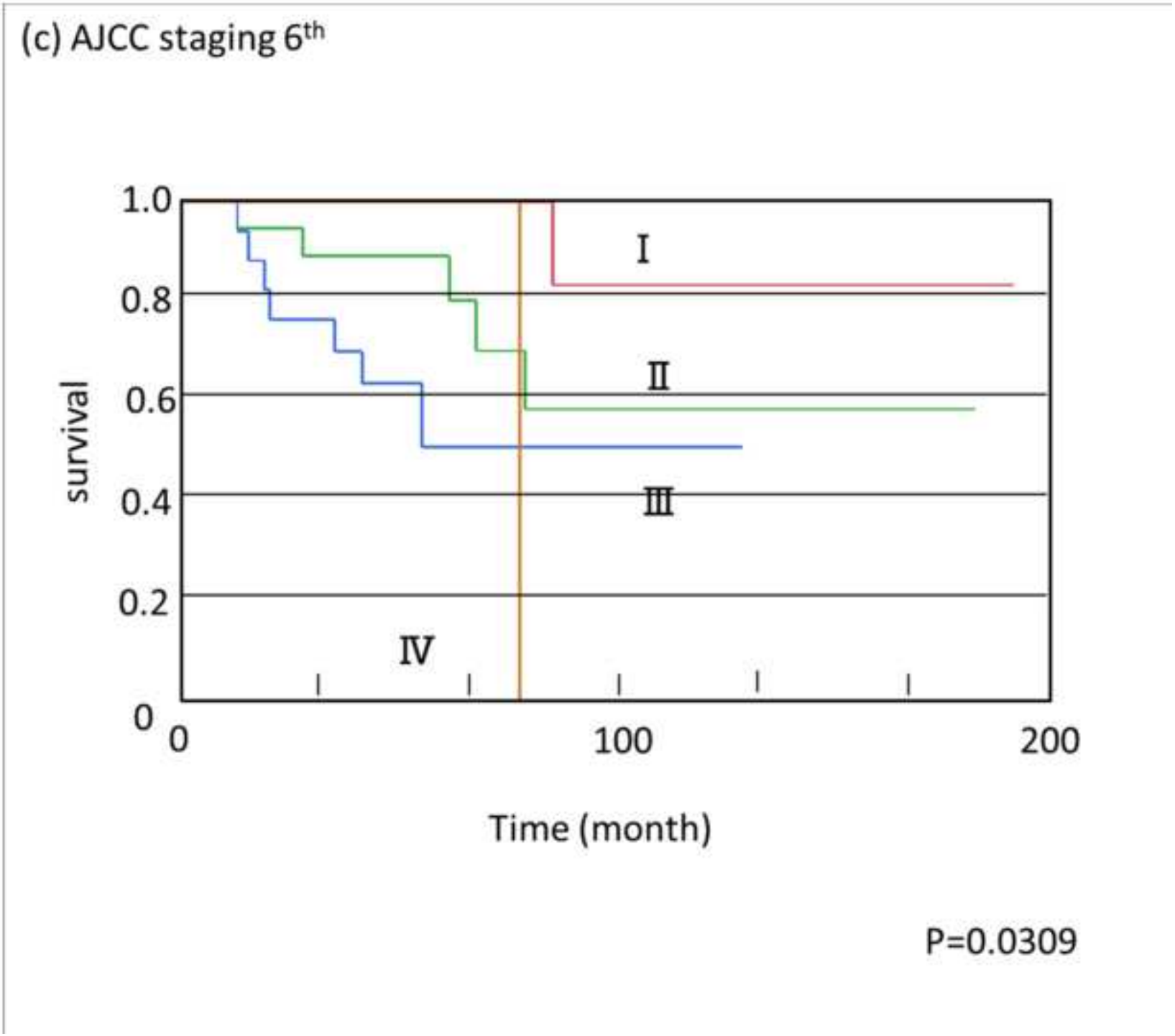

Figure(s)
Click here to download high resolution image

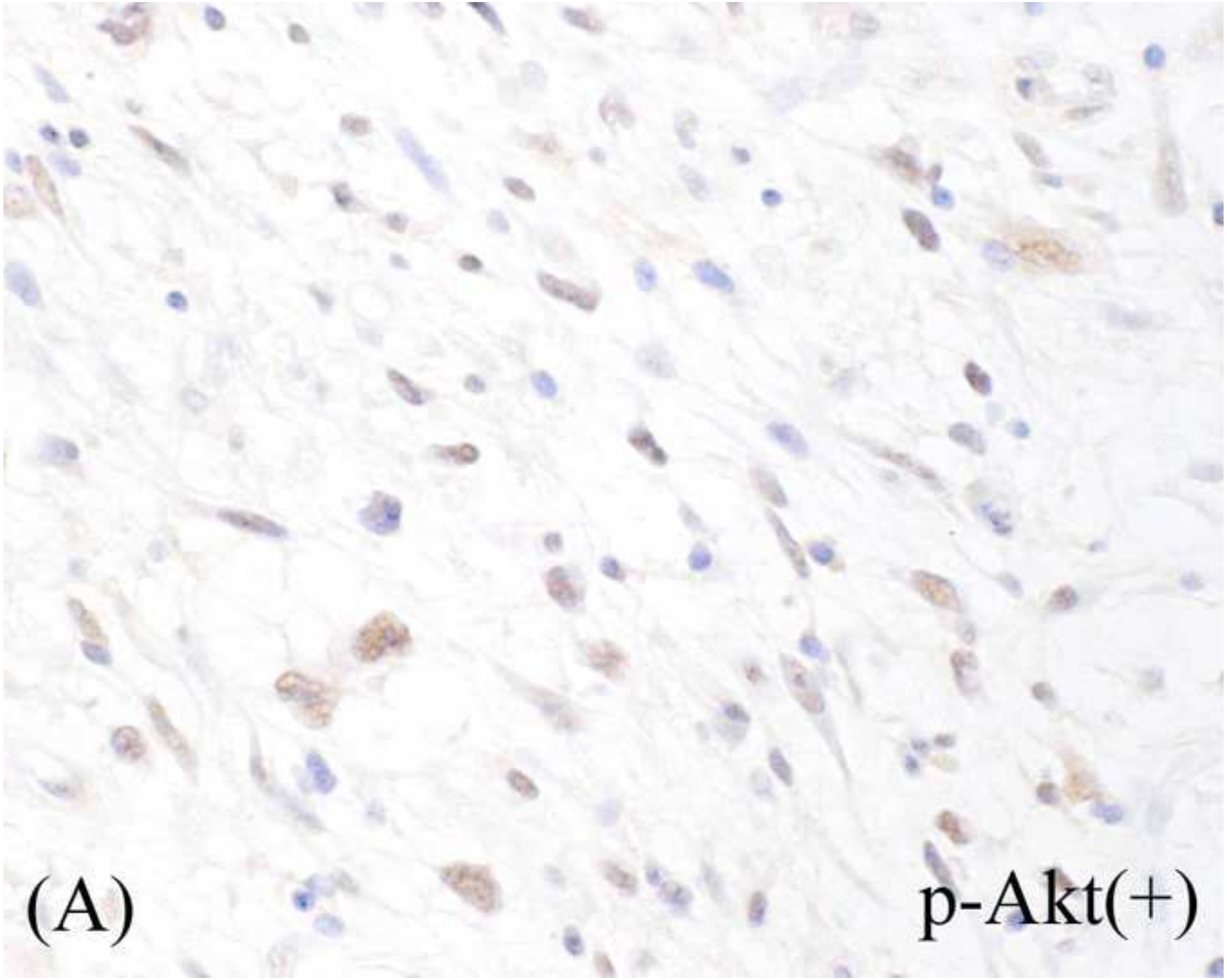

Figure(s)
Click here to download high resolution image

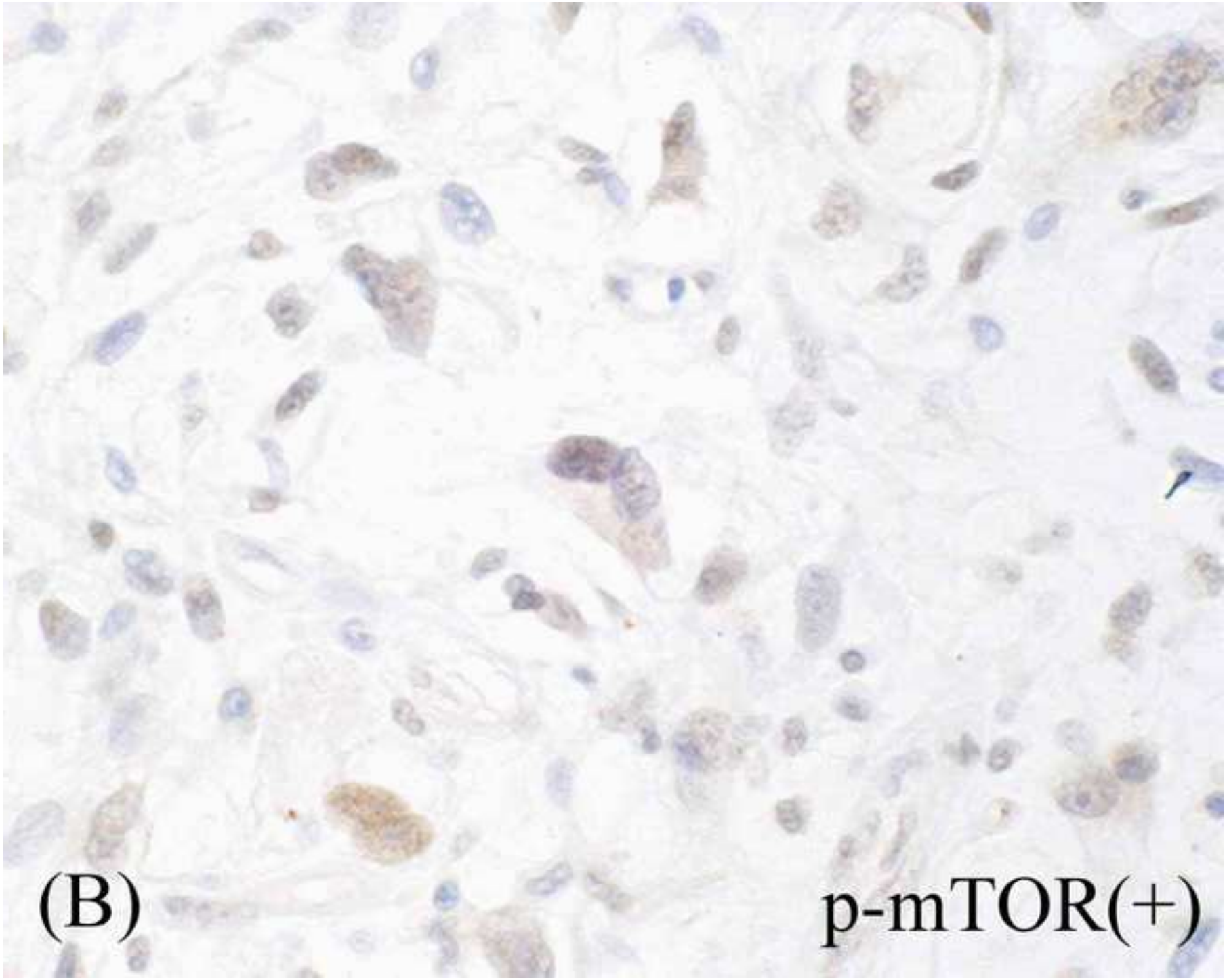

Figure(s)
Click here to download high resolution image

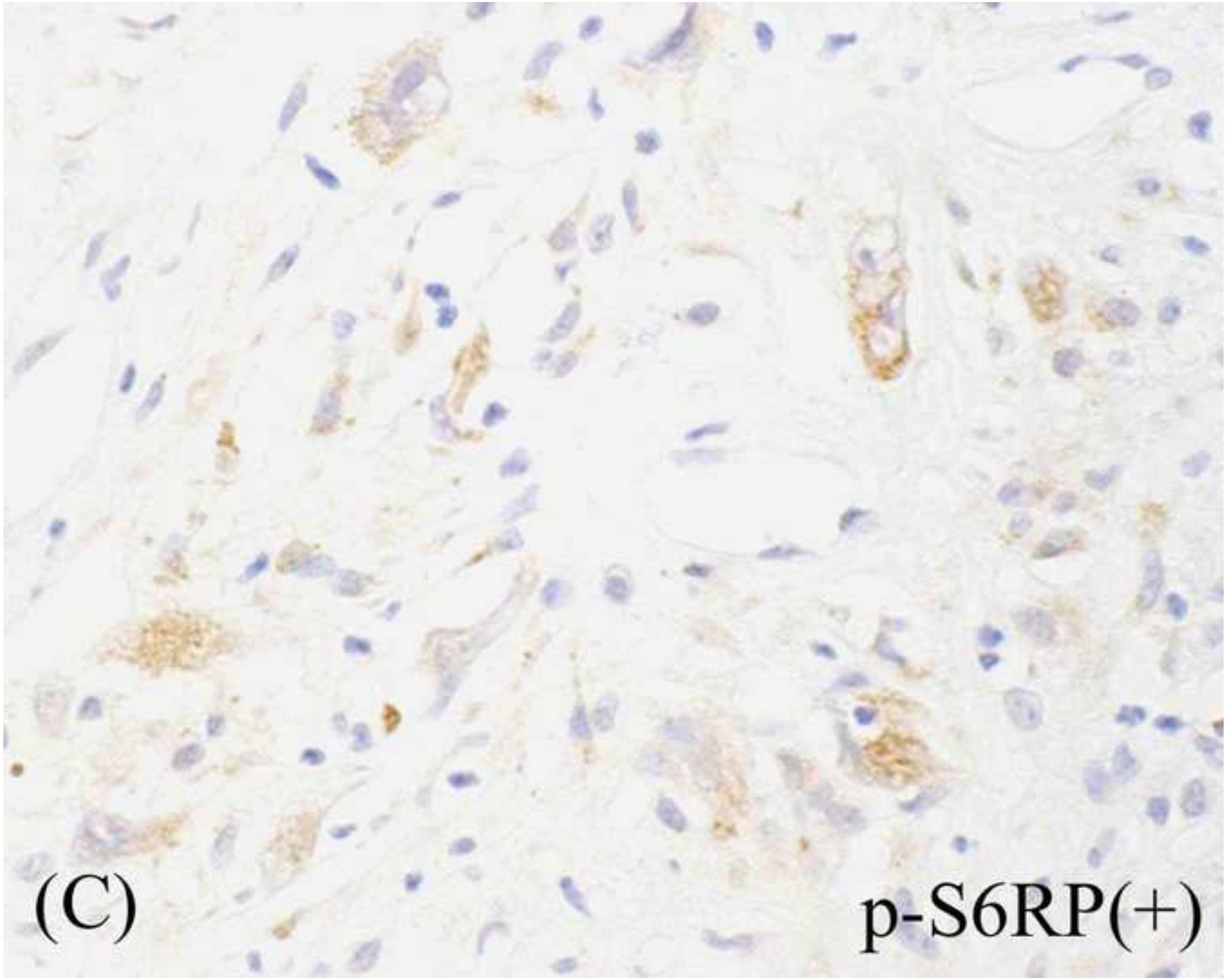

Figure(s)
Click here to download high resolution image

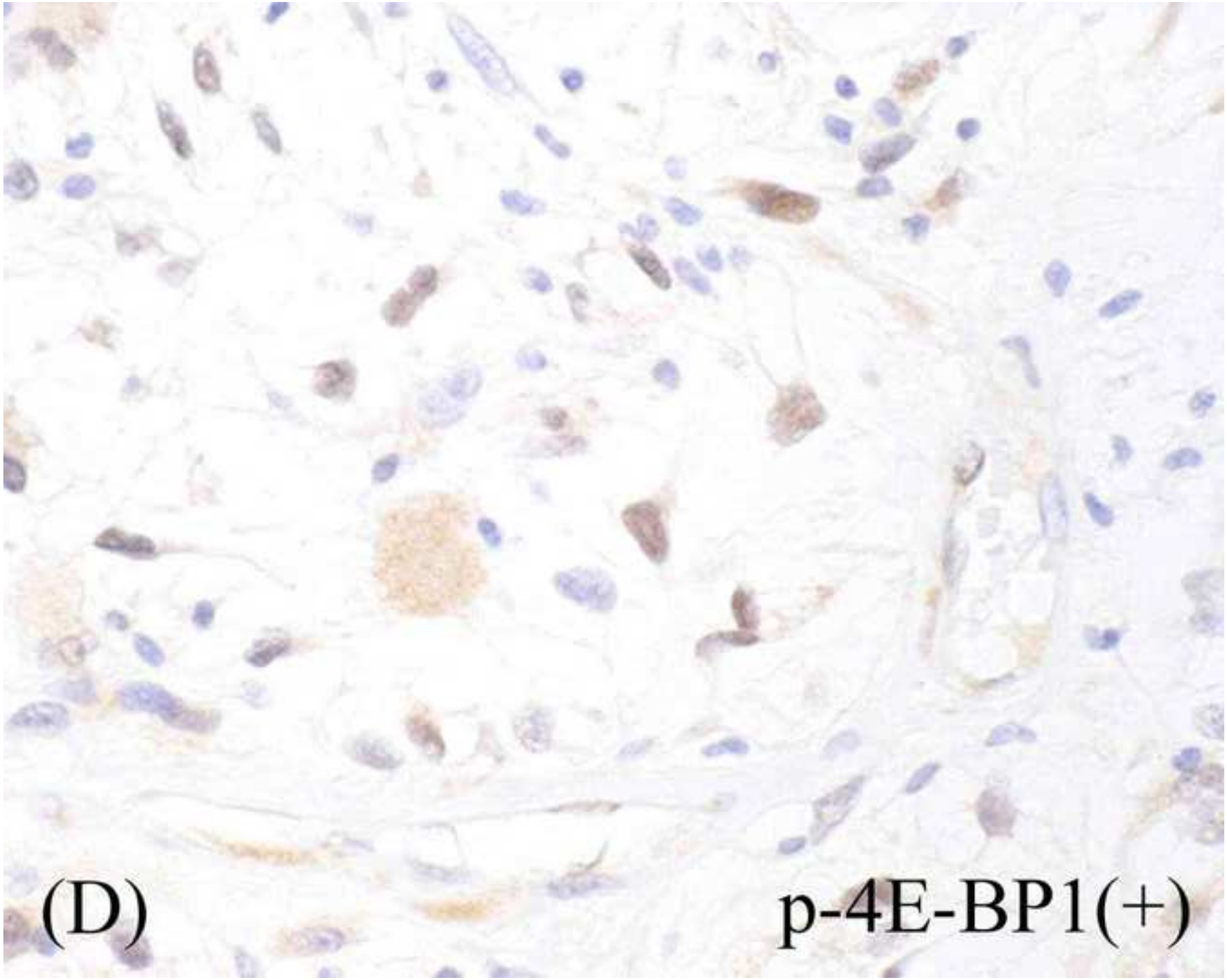

Figure(s)

Click here to download high resolution image

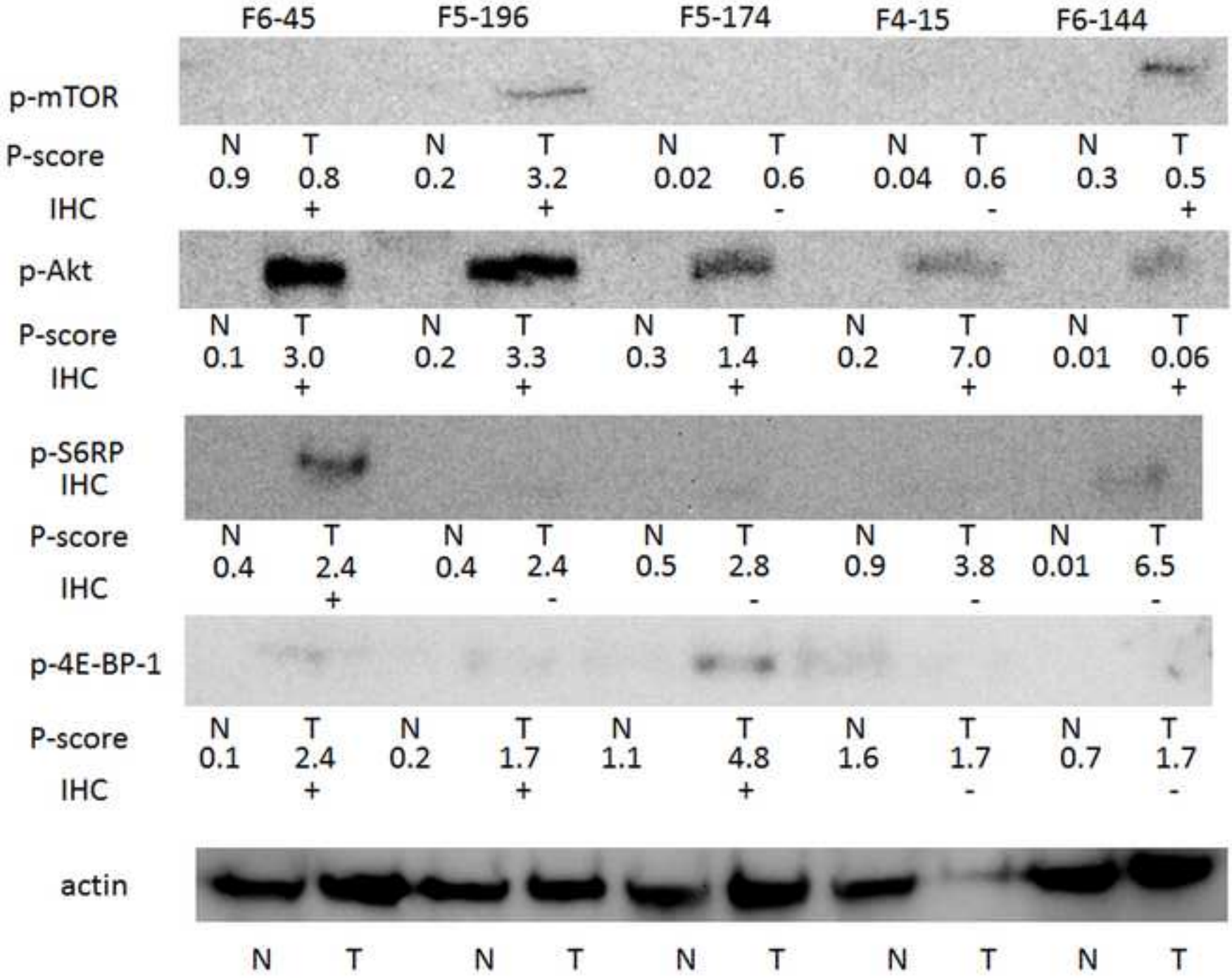

Figure(s)
Click here to download high resolution image

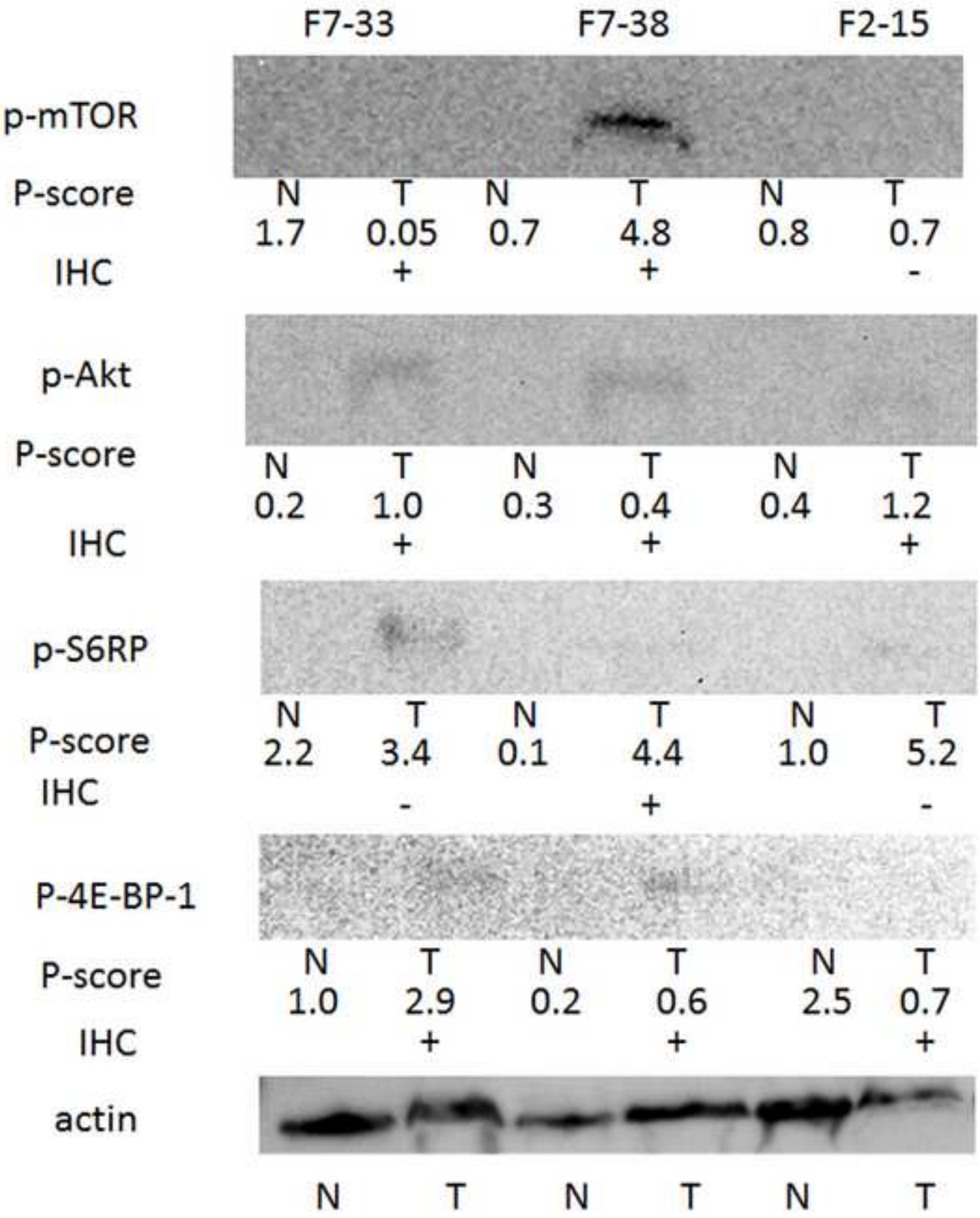

Table(s)

Table 1 Primer Sequences Used in Polymerase Chain; Reaction for Mutation Screening

Primer name	Sense 5'–3'	Antisense 5'–3'□	Annealing (°C)	Size (bp)
PIK3CA exon 9	*GCTAGAGACAATGAATTAAGGGAAA*	*AGCACTTACCTGTGACTCCA*	57	122
PIK3CA exon 20	*AACTGAGCAAGAGGCTTTGG*	*CTTTTCAGTTCAATGCATGCTG*	57	122
AKT 1 exon 2	*AGTGTGCGTGGCTCTCACCA*	*AGCCTCACGTTGGTCCACAT*	57	140

Table(s)

Table 2. Clinicopathological Parameters and Survival Analysis in 68 Primary Tumors

Parameter	Group	No	%	Analyzed Groups	Overall Survival, P[b]	Event-Free Survival, P[b]
Sex	Male	38	55.9	M vs F	0.785	0.788
	Female	30	44.1			
Size	<5 cm	28	41.2	<5 cm vs ≧5 cm	0.101	0.713
	≧5 cm	37	54.4			
	N/A	3	4.4			
Age [mean, 66.5 years]	<66 years	28	41.2	<66 years vs ≧66 years	0.785	0.081
	≧66 years	40	58.8			
Depth	Superficial	43	63.2	S vs D	0.0053[a]	0.172
	Deep	23	33.9			
	N/A	2	2.9			
Location	D	18	26.5	D vs Px	0.305	0.462
	Px	50	73.5			
Necrosis	None	31	45.6	None vs ≧50%	0.526	0.224
	<50%	33	48.5	≧50% vs 50%>t>0%	0.532	0.179
	≧50%	4	5.9			
Mitotic activity	0-9/10 HPF[d]	44	64.7	0-9 vs ≧20	0.0327[a]	0.559
	10-19/10 HPF	7	10.3	0-9 vs ≧10	0.0017[a]	0.2332
	20/10≧HPF	17	25.0	10-19 vs ≧20	0.1021	0.1761
Histological grade in WHO	High	36	52.9	H vs I vs L	0.0079[a]	0.2485
	Intermediate	14	20.6	H vs I	0.1251	0.4970
	Low	18	26.5	H vs L	0.0474[a]	0.1735
				I vs L	0.0008[a]	0.1265
				H vs I+L	0.8615	0.5897
				H+I vs L	0.0149[a]	0.1339
FNCLCC[c]	1	18	26.5	1 vs 2 vs 3	0.0307[a]	0.2901
	2	33	48.5	1 vs 2	0.0341[a]	0.1217
	3	17	25.0	1 vs 3	0.0067[a]	0.2825
				2 vs 3	0.4168	0.6639
				1 vs 2, 3	0.0149[a]	0.1339
				1, 2 vs 3	0.0651	0.8367
AJCC[d] 6th ed	Ⅰ	17	25.0	Ⅰ vs Ⅱ vs Ⅲ vs Ⅳ	0.0309[a]	0.3588
	Ⅱ	28	41.2	Ⅰ vs Ⅲ	0.0148[a]	0.173
	Ⅲ	19	27.9	Ⅰ vs Ⅱ	0.1041	0.225
	Ⅳ	1	1.5	Ⅰ vs Ⅱ+Ⅲ	0.0322[a]	0.1137
	N/A	3	4.4	Ⅰ+Ⅱ vs Ⅲ	0.0164[a]	0.2911
AJCC[d] 7th ed	Ⅰ	17	25.0	Ⅰ vs Ⅱ vs Ⅲ vs Ⅳ	0.0826	0.393
	Ⅱ	32	47.0	Ⅰ vs Ⅲ	0.0103[a]	0.2515
	Ⅲ	15	22.1	Ⅰ vs Ⅱ	0.069	0.1615
	Ⅳ	1	1.5	Ⅰ vs Ⅱ+Ⅲ	0.0322[a]	0.1478
	N/A	3	4.4	Ⅰ+Ⅱ vs Ⅲ	0.0533[a]	0.6551

[a] Statistically significant

[b] P-value

[c] FNCLCC, French Federation of Cancer Centers

[d] AJCC, American Joint Committee on Cancer

D, distal extremities

Px, proximal extremities and trunk

N/A, not available

Table(s)

Table 3 Immunohistochemical Results and Statistical Analysis, analysis in 68 samples of primary tumors

Analysis	Group	No.	%	p-Akt+, P[d]	p-mTOR+, P[d]	p-S6RP+, P[d]	p-4E-BP1+, P[d]	p-MEK+, P[d]
p-Akt	+	44	64.7	-	-	-	-	-
	-	24						
	N/A							
p-mTOR	+	31	45.6	0.0421[a]	-	-	-	-
	-	37						
	N/A							
p-S6RP	+	29	42.6	0.525	0.062	-	-	-
	-	39						
	N/A							
p-4E-BP1	+	43	63.2	0.965	0.0245[a]	0.0031[a]	-	-
	-	26						
	N/A							
p-MEK	+	44	64.7	0.0186[a]	0.219	0.106	0.372	-
	-	22						
	N/A	2						
p-Akt (+)	p-mTOR(+)/p-S6RP(+)	13	19.1					
	p-mTOR(-) or p-S6RP(-)	55						
p-Akt (+)	p-mTOR(+)/p4E-BP1(+)	17	25					
	p-mTOR(-) or p4E-BP1(-)	51						
Necrosis	None vs ≧50%			0.900	0.900	0.552	0.552	0.277
	None vs >0%			0.060	0.774	0.418	0.534	0.0048[a]
Mitotic activity	0-9 vs ≧20			0.938	0.208	0.785	0.0250[a]	0.957
	0-9 vs ≧10			0.802	0.294	0.904	0.0086[a]	0.853
WHO grading	H vs I+L			0.059	0.774	0.418	0.534	0.0048[a]
	H+I vs L			0.348	0.244	0.857	0.541	0.0213[a]
[c] FNCLCC	1,2 vs 3			1.000	0.0161[a]	0.933	0.0085[a]	0.843
	1 vs 2,3			0.348	0.219	0.857	0.434	0.0213[a]
Sex				0.833	0.740	0.695	0.623	0.593
Age	≧66 years			0.952	0.907	0.639	0.0035[a]	0.479
Location	D vs Px			0.710	0.910	0.857	0.828	0.111
Depth	S vs Dp			0.095	0.773	0.102	0.494	0.104
Diameter	≧5 cm			0.183	0.643	0.591	0.168	0.170
AJCC[b] 6th ed	Ⅰ vs Ⅲ			0.345	0.173	0.950	0.790	0.0062[a]
	Ⅰ vs Ⅱ,Ⅲ			0.494	0.261	0.803	0.602	0.0121[a]
	Ⅰ,Ⅱ vs Ⅲ			0.371	0.251	0.371	0.922	0.0372[a]
AJCC[b] 7th ed	Ⅰ vs Ⅲ			0.647	0.0291[a]	0.946	0.0179[a]	0.286
	Ⅰ vs Ⅱ,Ⅲ			0.494	0.261	0.803	0.602	0.0121[a]
	Ⅰ,Ⅱ vs Ⅲ			0.923	0.0176[a]	0.737	0.0030[a]	0.568
Overall survival				0.307	0.428	0.064	0.848	0.444
Event-free survival				0.246	0.344	0.698	0.404	0.294

[a] Statistically significant

[b] AJCC, American Joint Committee on Cancer

[c] FNCLCC, French Federation of Cancer Centers

[d] P-value

D, distal extremities

Px, proximal extremities and trunk

S, superficial

Dp, deep

4E-BP1, eukaryotic translation initiation factor 4E-binding protein

mTOR, mammalian target of rapamycin

N/A, not available

*Response to Reviewers

Dr. Ricardo. V. Lloyd
Editor-in-Chief
Human Pathology

December 17, 2013

Dear Dr. Ricardo V. Lloyd

Thank you very much for your letter and the reviewers' comments on our manuscript entitled **"Activation of the Akt/mTOR pathway in myxofibrosarcomas"** by Yusuke Takahashi et al. The comments offered by the reviewers were very helpful and we have revised our manuscript to incorporate your suggestions and the reviewers' suggestions as follows:

Comments and our replies

Editors' comments:

1. The figures need improving. The minimum resolution for photos is 300 dpi, and it is 1200 dpi for graphs. The following instructions may be helpful: http://www.elsevier.com/wps/find/authors.authors/authorartworkinstructions. Also, consider adding information about staining and magnification to the figure legends where appropriate.

Reply: We improved the resolution for photos according to your comment.

2. The number of cases for location and necrosis in table 1 do not total 68 as expected. Please review values and make any necessary corrections or insert explanatory footnotes as needed.

Reply: We rewrote the cases and information for location and necrosis in table 2,3.

3. Reference #3 is incomplete. If this is in press, please indicate as much (doi is also appreciated) and provide updates when more information becomes available. Otherwise, please provide volume and page numbers.

Reply: We rewrote the reference #3 with more information.

4. Ensure that gene symbols are consistently italicized in abstract, main text, tables, etc, while proteins are not.

Reply: We rewrote the gene symbols in italicized according to your comment.

Reviewers' comments:

Reviewer #1:

1. There are huge amount of data, but the involvement of the Akt/mTOR/S6RP-4E-BP1 pathway is still uncertain since it is unclear whether the authors presented the (constitutive) activation of this pathway or just concomitant activation of several of these proteins from signals emanated from various upstream molecules or from interconnecting pathways. The authors need to clarify the proportion of S6RP and 4E-BP1 phosphorylation, presumably mediated by phosphorylated-Akt, i.e., p-Akt(+)/p-mTOR(+)/p-S6RP(+), and p-Akt(+)/p-mTOR(+)/p-4E-BP1(+), by immunohistochemistry, in a flow chart.

Reply: We added the proportion of S6RP and 4E-BP1 phosphorylation, presumably mediated by phosphorylated-Akt in table 3. and main text p. 11, line 19-20 according to your comment.

2. The authors describe that "In the comparative analysis of immunoreactivity between primary and recurrent tumors, no significant difference in intensity or proportion of immunoreactive cells was observed between 12 recurrent tumors and their concordant primary tumor" in Page 12. What does "no significant difference" mean? Were all the results the same, or were there any differences? The delicate difference should not be evaluated by crude statistical analysis. This referee is curious about the details of phosphorylation status of proteins examined between primary and recurrent tumors in 12 patients.

Reply: We added the result of the immunoreactivity in main text p. 12, line19-20; p.13, line 1-3, and showed the propensity of the each phosphorylated proteins.

3. Results and Discussion are a little bit repetitive. Instead, the referee personally would like to see the result of survival analysis on p-Akt, p-mTOR and p-S6PR, even though they did not show statistically significant differences.

Reply: We added the explanation in the results p.13, line 8-10. The results of survival analysis showed in table 3.

Reviewer #2:
This study is a logical extension of prior work from the same group, which was previously focused on leiomyosarcomas and MPNSTs. The results are quite convincing if one accepts the technical approach that the authors have used. However, they need to discuss whether or not phosphorylation data in formalin-fixed/paraffin-embedded tissue has any true validity, since phosphorylation levels decay as soon as tissue is surgically removed - therefore the data presented may all be artefactual or false. The authors should explain/justify why these data are valid.

Reply: We rewrote the explanation in the discussion p.15, line 13-15., and added references (31, 32) according to your comment.

Aside from this concern, the work is carefully and thoroughly done in a large number of cases. Figures Ia and Ib are not really typical of myxofibrosarcoma and could likely be improved.

Reply: We changed the figure Ia and Ib according to your comment.

We thank you for your very helpful suggestions which have improved our report. Your kind consideration of this revision for publication in ***Human Pathology*** would be appreciated.

Sincerely yours,

Yoshinao Oda, M.D. PhD.
Yusuke Takahashi, M.D.