Minimally Invasive Total Pharyng-Laryngo-Esophagectomy and Reconstruction with Gastric Tube : Report of Three Cases

Kimura, Yasue
Department of Surgery and Science, Graduate School of Medical Sciences, Kyushu University | Department of Gastroenterological Surgery, National Kyushu Medical Center, Clinical Research Institute | Department of Gastroenterological Surgery, National Kyushu Medical Center, Clinical Research Institute

Morita, Masaru
Department of Surgery and Science, Graduate School of Medical Sciences, Kyushu University

Saeki, Hiroshi
Department of Surgery and Science, Graduate School of Medical Sciences, Kyushu University

Ikeda, Tetuo
Department of Surgery and Science, Graduate School of Medical Sciences, Kyushu University

他

https://doi.org/10.15017/1430778

出版情報：福岡醫學雜誌. 104 (11), pp.442-448, 2013-11-25. 福岡医学会
バージョン：
権利関係：

Minimally Invasive Total Pharyng-Laryngo-Esophagectomy and Reconstruction with Gastric Tube : Report of Three Cases

Yasue Kimura[1)2)], Masaru Morita[1)], Hiroshi Saeki[1)],Tetuo Ikeda[1)], Koji Ando[1)], Eiji Oki[1)], Keishi Sugimachi[1)], Yo-ichi Yamashita[1)], Hideaki Uchiyama[1)], Hirofumi Kawanaka[1)], Mitsuhiko Ohta[2)], Yoshihisa Sakaguchi[2)], Tetsuya Kusumoto[2)], Sei Yoshida[3)], Torahiko Nakashima[3)], Masayuki Watanabe[4)] Toshiya Furuta[5)] and Yoshihiko Maehara[1)]

[1)]*Department of Surgery and Science, Graduate School of Medical Sciences, Kyushu University*
[2)]*Department of Gastroenterological Surgery, National Kyushu Medical Center, Clinical Research Institute*
[3)]*Department of Otorhinolaryngology, Graduate School of Medical Sciences, Kyushu University*
[4)]*Department of Gastroenterological Surgery, Graduate School of Life Sciences, Kumamoto University, Kumamoto, Japan*
[5)]*Department of Surgery, Koga Central Hospital, Koga, Japan*

Abstract : Total pharyngo-laryngo-esophagectomy (TPLE) is indicated for either cervical esophageal cancer or synchronous double cancer of the thoracic esophagus and head and neck and this operation is extremely invasive. We adopted minimally invasive surgery for three patients who underwent this operation : VATS (video-assisted thoracoscopic surgery) esophagectomy was undergone in left semi-prone position and laparoscopic approach was also applied to reconstruction with gastric tube. After pharyngo-laryngectomy and gastric tube pull-up through post-mediastinal route, cervical anastomosis was performed. Free jejunal interposition was added in a case, while microvascular venous anastomosis between short gastric vein and cervical vein in another two cases. All patients recovered well without any postoperative complications.

This is the first report, which describes minimally invasive TPLE using both VATS and laparoscopic technique in addition with plastic surgery.

Key words : Esophageal cancer・Thoracoscopic esophagectomy・Jejunal flap

Introduction

Esophageal cancer is the eighth common incident cancer in the world and the prognosis has been poor[1)2)]. Surgical resection is the golden standard for treatment of this cancer : however, it is extremely invasive for the patients since it frequently needs both thoracic and abdominal approaches. Another clinical problem of esophageal cancer is the frequent association of head and neck cancer and such multiple occurrence of carcinoma in the upper aerodigestive tract mainly due to the common risk factors such as cigarette smoking and alcohol consumption[3)~5)].

Total pharyngo-laryngo-esophagectomy (TPLE) is mainly indicated either for synchronous double cancer of the thoracic esophagus and the head and neck or for cervico-thoracic esophageal cancer. This operation is considered to be most complicated and the most invasive surgery among gastro-intestinal tract surgeries due to unstable blood-flow of reconstructed conduit as well as extremely wide resection field. In order to overcome these problems, we recently reported the significance of application of techniques appropriate for each case, such as staged opera-

Corresponding Author : Yasue Kimura MD, Department of Surgery and Science, Graduate School of Medical Sciences, Kyushu University
Address : 3-1-1 Maidashi, Fukuoka 812-8582, Japan
Tel : +81-92-642-5466 Fax : +81-92-642-5482
E-mail : yasuek@surg2. med. kyushu-u. ac. jp

Table 1 Patients' profile

Case	Age	Sex	Tumor locations and staging	Another cancer
1	55	M	Hypolarynx (T4aN0M0 StageIVa), Mid-thoracic esophagus (T1N0M0 StageI)	tongue cancer, previous
2	33	M	Cervical esophagus (T4N1M0 StageIII)	laryngeal cancer, previous
3	57	M	Cervical and mid-thoracic esophagus (T3N1M0 StageIII)	

tions, muscular flaps and microvascular anastomosis[6].

Minimally invasive esophagectomy using video-assisted thoracoscopic surgery (VATS) technique is performed with increasing frequency and proves to be a safe and effective surgical alternative to the open technique[7]. Minimally invasive esophagectomy using thoracoscopic esophageal mobilization and lymph nodes dissection in prone position seems to offer some advantages with regard to surgeon ergonomics and clinical outcome[8].

Here we report three cases, who underwent minimally invasive TPLE using VATS esophagectomy in prone position followed by laparoscopic reconstruction with gastric tube.

Case Report

Present illness and clinical findings

Case1 : A 55-year-old man was underwent endoscopy because of discomfort in the hypopharyngeal region. Endoscopy showed bloody tumor on the pharynx, and ulcerative and localized type of tumor on thoracic esophagus. He was diagnosed hypopharyngeal (T4aN0M0StageIVa) and mid-thoracic esophageal cancer (T1N0M0 Stage I)[9]. He had a past history of advanced tongue cancer 8 years before, which was cured by multimodal therapy including chemotherapy, radiotherapy (total 50 Gy). As an initial treatment for synchronous double cancer, he received chemotherapy with S-1 since he rejected operation. However, the hypopharyngeal tumor showed progression and surgical resection of both pharyngolarynx and esophagus was indicated.

Case2 : A 33-year-old man suffered from dysphagia and endoscopy revealed ulcerative and localized type of tumor with severe stenosis on cervical esophagus. He was diagnosed as squamous cell carcinoma of the cervico-thoracic esophagus. Computed tomography revealed tracheal invasion and supraclavicular lymph nodes metastasis (T4N1M0 Stage III). He had past history of advanced laryngeal cancer cured by radical neck lymphadenectomy and radiotherapy (total 70 Gy) four years before. Following neoadjuvant chemotherapy with high dose FP therapy (5-FU : 1000mg/d1-5 and CDDP : 80mg/d1), TPLE was undergone.

Case3 : A 57-year-old man underwent endoscopic examination because of dysphagia and was diagnosed as multiple squamous cell carcinoma of the cervical and thoracic region (T3N1M0 Stage III). After chemoradiotherapy as a neoadjuvant therapy (two cycles high dose FP therapy ; 5-FU : 1000mg/d1-5 and CDDP : 80mg/d1, total 40 Gy /20fr), he was taken surgical resection for cervical and middle thoracic esophageal cancer.

Table 1 shows patients' profile. These three cases had cervico-thoracic esophageal cancer or multiple esophageal cancers, which were indication for TPLE.

Surgical procedure

Under satisfactory general anesthesia with the patient in a spine position, then the position was changed to left semi-prone position. Two 12mm ports and two 5mm ports were inserted to the intrathoracic space and an artificial CO_2 pneumothorax was achieved at a pressure of 5 mmHg (Fig. 1). The middle and lower esophagus

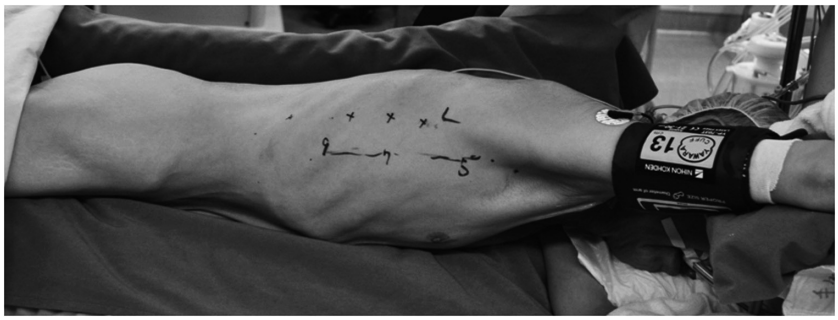

Fig. 1 Patients' position before surgery. Thoracoscopic esophagectomy was performed in this semi-prone position.

was dissected and Azygos arch was doubly ligated and cut with LigaSure® . Right bronchial artery was preserved. Right vagal nerve and recurrent laryngeal nerve were clearly confirmed, mediastinal lymph node dissection was performed. The upper and the middle esophagus was divided with Endo GIA ultra® .

After the position was changed to the supine position, 2cm skin incision at the navel was made or laparotomy and 12mm port was inserted. And one more 12mm port and three 5mm ports were inserted. Lesser curvature was dissected and #1, 2, 3, 7 lymph nodes were dissected. During the dissection, right gastroepiploic vessels was preserved and left gastric vessels were ligated, clipped and cut with LigaSure® . Greater curvature of the stomach was dissected. The esophageal hiatus was dissected and the lower esophagus was pulled out from the mediastinum.

The esophago-gastric organ was pulled out through the skin incision of navel from peritoneal cavity, gastric tube, which 3.5cm in width was made with Endo GIA ultra® . The blood flow of the gastric tube was found to be enough.

For pharyngo-laryngectomy, U-shaped skin incision was made in cervical site. Case 1 and 2 had a severe adhesion because of former operation. Larynx and hypopharynx was raised, cervical esophagus was released from trachea. Trachea was cut just above clavicle and pharynx was cut. Then, the specimen was excised. Lymph nodes dissection was performed in case of Case3. Case 1 and 2 had already performed neck lymph nodes dissection in previous operation. The gastric tube was inserted to the right thoracic cavity through esophageal hiatus and pulled up to the neck through the mediastinum route by way of echo probe cover.

Therefore the gastric tube was not enough to reach to anastomotic site of pharynx we decided to interpose free jejunum in Case1. Laparoscopy revealed Treitz ligament and orientation of proximal jejunum. The jejunum 30-50cm jejunum from Treitz ligament, which was supplied blood flow from the 3rd jejunum artery, was dissected as the free flap of jejunum for reconstruction. The free flap of jejunum was anastomosed with the stump of pharynx in oral side and anastomosed with gastric tube in anal side. Next, vascular anastomosis was performed under microscope. The jejunal artery (2.5mm) was anastomosed with right superior thyroid artery (2.5mm) with 9-0 nylon. The jejunal vein (3mm) was with left internal jugular vein. The leak test with the use of dye was done resulting in no finding of leakage. The blood flow of anastomosis was good. In case 2 and 3, microvascular anastomosis between short gastric vein and cervical vein was added when reconstructing with gastric tube.

There was no complication in all three cases and activity in hospital and time to discharge were independent of the abdominal procedure. Figure 2 shows the skin incision of this operation.

Discussion

The prognosis of esophageal cancer has been

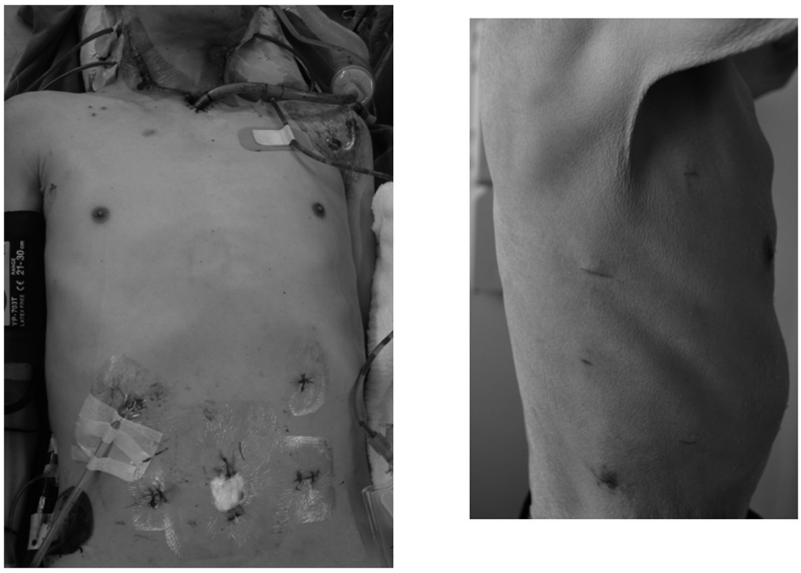

Fig. 2 Case1 patient was reconstructed with gastric tube and jejunal flap after total esophagectomy.

poor[1)2)]. A nationwide registry of 5066 Japanese patients with esophageal cancer treated in 2004 showed that second cancers in another organ were recognized in 981 patients (19.4%). Gastric cancer is the most common (353 lesions), followed by head and neck cancer including 162 pharyngeal cancers, 66 laryngeal cancers and 24 cancers in the oral cavity[2)]. The treatment for double cancer is often performed chemoradiotherapy, while in the case of synchronous double cancer of the thoracic esophagus and the head and neck or for cervico-thoracic esophageal cancer TPLE is mainly indicated.

Minimally invasive esophagectomy can be performed in decubitus positions. However, it is not until recently that the prone position has gained popularity. The technique was first described in 1994 by Cuschieri[10)], but it was not widely adopted. In 2006, Palanivelu and colleagues[7)] published a 130-patient series and concluded that mobilization of the esophagus and mediastinal lymphadenectomy with the thoracoscopic part in prone position is comparable with the decubitus position in terms of blood loss and another complications, and had a significantly shorter duration. Minimal access surgery has gained wider applications in recent years and these new techniques have also been applied to cancer surgery[11)]. Cadiere et al. described thoracoscopic procedure in prone position improved quality of lymphadenectomy and excellent vision of the mediastinal space[12)]. In the current study, this method can be applied to TPLE safely and less invasive for these cases of esophageal cancer with head and neck cancer.

Microvascular free tissue transfer has been gained world-wide acceptance as a means of reconstructing post-oncologic surgical defects in the head and neck region and cervical esophageal cancer. The development and refinement of microvascular instruments and magnification have improved the overall success rates reported to 94-96% ; but uncommon complications may prove devastating. Open laparotomy was often performed for harvest of the jejunum. Gherardini G. et al. [13)] reported endoscopic harvest of the jejunum is indicated for the reconstruction of complex defects of the head and neck and specifically the reconstruction of circumferential defects of the esophagus. Laparoscopy for intra-abdominal procedures is a proven technique that yields less morbidity and provides an anatomical exposure similar to that of the open approach in our case.

In determining the treatment strategy for multiple cancers of the UADT region [14], the stage and the location of the more advanced tumor, which strongly influence the prognosis, the order for treating each primary lesion and the general patient status should be considered. There is the problem between curability and quality of life. The procedures with sacrificing the vocal function and swallowing function sometimes cannot be avoided during the complete cure of head-and-neck cancer, which leads to a loss of the patient quality of life. These complicated procedures cannot be achieved by a single treatment. Surgical procedures sometimes requires TPLE. A long organ is required for reconstruction, otherwise there are some problems such as unstable blood flow and tension. We have not only created narrow gastric tube but also performed microvascular venous anastomosis preventing congestion[15][16]. As a matter of course, free jejunal transfer using of a pectoralis myocutaneous flap and microvascular anastomosis had been performed in case of the gastric tube not enough to reach to anastomotic site of pharynx[17].

Surgical procedures are generally too invasive and complicated, as multiple cancer of the UADT requires an extensive surgical field ranging from the head and neck region to the abdomen. Furthermore these UADT cancer patients were heavy smokers and alcohol consumptions, who have respiratory complication or liver damage. It is important to reduce the risk of postoperative complication, because the rates of perioperative complication are more compared with other gastrointestinal cancer[18)~20]. It was very difficult to decide on the proper operation that should be applied to the extended multiple lesions, as well as the proper timing and order. We sometimes perform two-staged operation[21], microvascular anastomosis such as supercharge or superdrainage[16].

In the current study, our three cases had past history of previous operation for head and neck cancers. Then these cases were performed thoracoscopic and laparoscopic operation to reduce invasiveness and complications. After minimal invasive TPLE adopting VATS laparoscopic techniques, perioperative complications have never developed in these cases.

Conclusion

This is the clinical report of a thoracoscopic total esophagectomy in prone position and laparoscopic assisted reconstruction gastric tube for hypopharngeal and esophageal cancers. No surgical complications developed during the postoperative period, demonstrating the safety and feasibility of minimally invasive TPLE including both VATS and laparoscopic surgery and technique of plastic surgery.

Refarences

1) Muller JM, Erasmi H, Stelzner M, Zieren U and Pichlmaier H : Surgical therapy of oesophageal carcinoma. Br J Surg 77 : 845-857, 1990.
2) Ozawa S, Tachimori Y, Baba H, Fujishiro M, Matsubara H, Numasaki H, Oyama T, Shinoda M, Takeuchi H, Teshima T, Udagawa H, Uno T and Barron JP : Comprehensive Registry of Esophageal Cancer in Japan, 2004. Esophagus 9 : 77-98, 2012.
3) Morita M, Araki K, Saeki H, Sakaguchi Y, Baba H, Sugimachi K, Yano K, Sugio K and Yasumoto K : Risk factors for multicentric occurrence of carcinoma in the upper aerodigestive tract-analysis with a serial histologic evaluation of the whole resected-esophagus including carcinoma. J Surg Oncol 83 : 216-221, 2003.
4) Toh Y, Oki E, Ohgaki K, Sakamoto Y, Ito S, Egashira A, Saeki H, Kakeji Y, Morita M, Sakaguchi Y, Okamura T and Maehara Y : Alcohol drinking, cigarette smoking, and the development of squamous cell carcinoma of the esophagus : molecular mechanisms of carcinogenesis. Int J Clin Oncol 15 : 135-144, 2010.
5) Morita M, Kumashiro R, Kubo N, Nakashima Y, Yoshida R, Yoshinaga K, Saeki H, Emi Y, Kakeji Y, Sakaguchi Y, Toh Y and Maehara Y : Alcohol drinking, cigarette smoking, and the development of squamous cell carcinoma of the esophagus : epidemiology, clinical findings, and prevention. Int J Clin Oncol 15 : 126-134, 2010.
6) Morita M, Kawano H, Otsu H, Kimura Y, Saeki

H, Ando K, Ida S, Oki E, Ikeda T, Kusumoto T, Fukushima JI, Nakashima T and Maehara Y : Surgical Resection for Esophageal Cancer Synchronously or Metachronously Associated with Head and Neck Cancer. Ann Surg Oncol, 2013.

7) Palanivelu C, Prakash A, Senthilkumar R, Senthilnathan P, Parthasarathi R, Rajan PS and Venkatachlam S : Minimally invasive esophagectomy : thoracoscopic mobilization of the esophagus and mediastinal lymphadenectomy in prone position--experience of 130 patients. J Am Coll Surg 203 : 7-16, 2006.

8) Fabian T, McKelvey AA, Kent MS and Federico JA : Prone thoracoscopic esophageal mobilization for minimally invasive esophagectomy. Surg Endosc 21 : 1667-1670, 2007.

9) TNM Classification of Malignant Tumours. New York, Wiley-Blackwell, 2009.

10) Cuschieri A : Thoracoscopic subtotal oesophagectomy. Endosc Surg Allied Technol 2 : 21-25, 1994.

11) Jarral OA, Purkayastha S, Athanasiou T, Darzi A, Hanna GB and Zacharakis E : Thoracoscopic esophagectomy in the prone position. Surg Endosc 26 : 2095-2103, 2012.

12) Cadiere GB, Torres R, Dapri G, Capelluto E, Hainaux B and Himpens J : Thoracoscopic and laparoscopic oesophagectomy improves the quality of extended lymphadenectomy. Surg Endosc 20 : 1308-1309, 2006.

13) Gherardini G, Gurlek A, Staley CA, Ross DA, Pazmino BP and Miller MJ : Laparoscopic harvesting of jejunal free flaps for esophageal reconstruction. Plast Reconstr Surg 102 : 473-477, 1998.

14) Watanabe A, Hosokawa M, Taniguchi M, Tsujie H and Sasaki S : Head and neck cancer associated with esophageal cancer. Auris Nasus Larynx 34 : 207-211, 2007.

15) Saeki H, Morita M, Harada N, Egashira A, Oki E, Uchiyama H, Ohga T, Kakeji Y, Sakaguchi Y and Maehara Y : Esophageal replacement by colon interposition with microvascular surgery for patients with thoracic esophageal cancer : the utility of superdrainage. Dis Esophagus 26 : 50-56, 2013.

16) Uchiyama H, Shirabe K, Morita M, Kakeji Y, Taketomi A, Soejima Y, Yoshizumi T, Ikegami T, Harada N, Kayashima H, Morita K and Maehara Y : Expanding the applications of microvascular surgical techniques to digestive surgeries : a technical review. Surg Today 42 : 111-120, 2012.

17) Sekido M, Yamamoto Y, Minakawa H, Sasaki S, Furukawa H, Sugihara T, Nohira K, Yajima K, Shintomi Y, Okushiba S, Kato H and Hosokawa M : Use of the "supercharge" technique in esophageal and pharyngeal reconstruction to augment microvascular blood flow. Surgery 134 : 420-424, 2003.

18) Morita M, Nakanoko T, Fujinaka Y, Kubo N, Yamashita N, Yoshinaga K, Saeki H, Emi Y, Kakeji Y, Shirabe K and Maehara Y : In-hospital mortality after a surgical resection for esophageal cancer : analyses of the associated factors and historical changes. Ann Surg Oncol 18 : 1757-1765, 2011.

19) Jamieson GG, Mathew G, Ludemann R, Wayman J, Myers JC and Devitt PG : Postoperative mortality following oesophagectomy and problems in reporting its rate. Br J Surg 91 : 943-947, 2004.

20) Liu JF, Watson DI, Devitt PG, Mathew G, Myburgh J and Jamieson GG : Risk factor analysis of post-operative mortality in oesophagectomy. Dis Esophagus 13 : 130-135, 2000.

21) Hisamatsu Y, Morita M, Saeki H, Egashira A, Ohga T, Kakeji Y, Fukushima J, Shiratsuchi H, Nakashima T and Maehara Y : Staged resection and reconstruction following definitive chemoradiotherapy for perforated cervico-thoracic esophageal cancer with mediastinal abscess. Esophagus 8 : 197-201, 2011.

(Received for publication October 10, 2013)

（和文抄録）

咽頭喉頭摘出が必要な食道癌症例に対し胸腔鏡および腹腔鏡下に咽頭喉頭食道亜全摘・胃管再建を施行した3例の検討

[1)]九州大学大学院医学研究院　消化器・総合外科
[2)]国立病院機構　九州医療センター　消化器外科
[3)]九州大学大学院医学研究院　耳鼻咽喉科
[4)]熊本大学大学院　消化器外科
[5)]古賀中央病院

木村和恵[1)2)]，森田　勝[1)]，佐伯浩司[1)]，池田哲夫[1)]，安藤幸滋[1)]，沖　英次[1)]，杉町圭史[1)]，山下洋市[1)]，内山秀昭[1)]，川中博文[1)]，太田光彦[2)]，坂口善久[2)]，楠本哲也[2)]，吉田　聖[3)]，中島寅彦[3)]，渡邊雅之[4)]，古田斗志也[5)]，前原喜彦[1)]

咽頭喉頭食道全摘術は，異時性同時性頭頸部合併食道癌症において適応となるが，大きな侵襲を伴う手術である．我々は，咽喉食摘が必要な3例に対して低侵襲な胸腔鏡下食道全摘，腹腔鏡下胃管再建を施行した．左半腹臥位にて胸腔鏡下に食道亜全摘を施行し，仰臥位になった後，腹腔鏡下に胃管作成を施行した．その後，咽喉食摘し，胃管は後縦隔経路にて頸部吻合をおこなった．胃管と咽頭の吻合距離が不十分な時は遊離空腸を間置し再建し，さらに短胃静脈と頸静脈を血管吻合した．全例大きな合併症はなく経過した．これらの手術に胸腔鏡腹腔鏡を用いることは比較的少ないため，当科での経験を報告する．