

## Temporal Effects of High Dietary Zinc on the Histological Changes Produced in White Leghorn Cocks

Eltohamy, Magda Mohammed

Laboratory of Animal Husbandry II, Faculty of Agriculture, Kyushu University

Takahara, Hitoshi

Laboratory of Animal Husbandry II, Faculty of Agriculture, Kyushu University

Okamoto, Masao

Laboratory of Animal Husbandry II, Faculty of Agriculture, Kyushu University

<https://doi.org/10.5109/23709>

---

出版情報：九州大学大学院農学研究院紀要. 24 (4), pp.189-199, 1980-02. Kyushu University  
バージョン：  
権利関係：

## Temporal Effects of High Dietary Zinc on the Histological Changes Produced in White Leghorn Cocks

Magda Mohammed Eltohamy, Hitoshi Takahara  
and Masao Okamoto

Laboratory of Animal Husbandry II, Faculty of Agriculture,  
Kyushu University 46-06, Fukuoka 812

(Received September 19, 1979)

Effects of high dietary Zn on histological changes of the endocrine glands were investigated in White Leghorn cocks. Cocks received 1000 ppm dietary Zn showed normal testicular development. In the groups received 3000 and 4000 ppm dietary Zn, the inhibitory effects in the testes suggested impaired production and/or release of adenohipophysial gonadotrophic hormone. Adenohipophysis of the group received 1000 ppm dietary Zn showed an increase in PAS-positive materials of the basophils, while adenohipophysis of the groups received 3000 and 4000 ppm dietary Zn showed the marked regressive changes. In these morphological changes, evidence of diminished cellular activity support the morphological changes detected in the testes. Caudal acidophils of the group received 1000 ppm dietary Zn increased in number and size, while the acidophils of the groups received 3000 and 4000 ppm dietary Zn decreased in number and size. These changes might illustrate to interfere with somatic growth. Amphophils of the cephalic lobe were in an active functional phase in all groups received Zn. Histological and histochemical changes in the adrenals, reflected in cortical hypertrophy and increase lipid and cholesterol contents in the cortex, were indication of active adrenals in all groups received Zn. Thyroid glands were more resistant to high levels of dietary Zn. Pancreas of the group received 1000 ppm dietary Zn was unaltered, while the glands in the groups received 3000 and 4000 ppm dietary Zn were markedly changed in both exocrine and endocrine portions. After 2 weeks of recovery period, the testes, adenohipophysis, adrenals and pancreas restored to normal condition. Therefore, the results led to assumption that Zn has direct effect not only on the testes, adenohipophysis but may be also on the adrenals, while the thyroids were resistant to Zn addition.

### INTRODUCTION

The indispensability of Zn for normal reproductive processes in human and animals is well documented. Several organs with endocrine function such as thyroids, adrenals, testes and pancreas in the rat show a relatively high uptake of  $^{65}\text{Zn}$ . The role of Zn in the normal function of the male genital tract has been demonstrated (Miller *et al.*, 1958). Mawson and Fischer (1953) reported that semen and spermatozoa were rich sources of Zn. Therefore, Zn seems to have a particular role in the physiological function of the testes. Testicular Zn metabolism has been shown to be regulated under the control of pituitary gland. Hypophysectomy depresses radiozinc uptake of the

testes in the rats and interstitial cell stimulating hormone (ICSH) administration prevents the fall of radiozinc uptake (Gunn *et al.*, 1961).

Pancreas is one of the organs in which the most rapid accumulation and turnover of retained Zn occurs (Feaster *et al.*, 1954). Pancreatic acinar cells are known to be a major excretion pathway of Zn (Montgomery *et al.*, 1943). Since Zn is believed to play a direct role in protein synthesis, some abnormalities of pancreatic exocrine function might be predicted when this organ supplied with inadequate Zn.

Growth retardation, anemia and disturbance in tissue levels of several essential minerals were produced by high levels of dietary Zn (Grant-Frost and Underwood, 1958). The adverse physiological effects produced by high dietary Zn in rats have been attributed to reduce food intake. Previous morphological studies demonstrated that the adverse physiological effects of high dietary Zn on the testes of cockerels might be due to endocrine mechanism (Eltohamy *et al.*, 1979). But the significance and exact nature of the hormonal control involvement which accompanies with the administration of dietary Zn are still unknown in the cocks.

The present study was undertaken in order to gain background information necessary for evaluating the effects of high dietary Zn in mature cocks, to define and correlate the morphological changes in the testes, adeno-hypophysis, adrenals, thyroids and pancreas, to elucidate the role of high dietary Zn on the adeno-hypophysis-gonadal axis and to assess whether or not the adverse physiological effects of high dietary Zn can recover when the cocks fed diet without added Zn.

## MATERIALS AND METHODS

Twelve-weeks old, 48 White Leghorn cocks were randomly divided into four experimental groups of 12 cocks each. One group was fed a basal diet (Table 1) which contained 80 ppm Zn. Three other groups were fed the diets to which Zn ammonium sulphate was added at levels of 1000, 3000 and 4000 ppm. The diets and water were offered *ad libitum*. Body weights were recorded at 7 days intervals. At the end of 25 days experimental periods, 24 cocks (6 cocks from each experimental group) were sacrificed by decapitation. As rapidly as possible, testes, adeno-hypophysis, adrenals, thyroids and pancreas were removed, weighed and used for Zn analysis and histological examination.

Zn contents of the diet and individual organs were determined by atomic absorption spectrophotometry after wet digestion of samples in the nitric perchloric acids mixture. Zn content was calculated as Zn concentration on fresh weight basis.

The adeno-hypophysis was fixed in sublimate-formol and stained with Matsuo tetrachrome method and periodic acid-Schiff (PAS) method. The testes and thyroids were fixed in Bouin's solution and stained with hematoxylin-eosin (HE) and PAS-hematoxylin. The adrenals and pancreas were fixed in 10% formalin and stained with HE. Frozen sections of the adrenals were

**Table 1.** Composition of the basal diet.

Ingredient	(%)
Corn	24.0
Barley	50.5
Soybean	7.0
Fish meal	18.0
Sodium chloride	0.5

stained with Sudan black for lipid. The schultz test for cholesterol were also performed. The other 24 cocks (the remainder 6 cocks from each experimental group) were placed on the diets without addition of Zn for 2 weeks recovery period and then sacrificed. This was done in order to find out whether or not the cocks could recover from the high levels of Zn.

**RESULTS**

**Body and organ weights**

Data illustrating the effects of high dietary Zn on body, testes, adeno-hypophysis, adrenals, thyroids and pancreas weights found in experimental and recovery periods are presented in Table 2. The level of 1000 ppm dietary Zn caused slight increase in body weight of the cocks over that of control, but the difference was not significant. Significant depression of body weight occurred only with the level of 4000 ppm dietary Zn. For the recovery period,

**Table 2.** Effects of high dietary Zn levels on body and organ weights for the experimental and recovery periods.

Zn added to the diet (ppm)	Body weight (g)	Adeno-hypophys weight (mg)	Adrenals weight (mg)	Thyroids weight (mg)	Pancreas weight (g)	Testes weight (g)
<b>Experimental period</b>						
0	1782.00*	12.70*	183.28*	166.00*	3.11*	20.97*
	± 112.56	± 3.00	± 35.30	± 45.60	± 0.70	± 4.46
1000	1815.00	13.75	197.87	168.00	3.11	21.10
	± 161.12	± 2.24	± 30.30	± 36.30	± 0.29	± 6.04
3000	1746.00	13.14	181.52	142.80	3.03	8.75
	± 163.95	± 3.44	± 30.33	± 45.90	± 0.60	± 4.52
4000	1443.57 <sup>1)</sup>	9.80	174.00	169.60	2.18	0.88 <sup>1)</sup>
	± 252.07	± 4.26	± 42.10	± 98.40	± 0.71	± 0.93
<b>Recovery period</b>						
0	1790.00	10.70	140.00	146.10	3.03	30.22
	± 51.96	± 0.71	± 53.00	± 46.10	± 0.56	± 2.39
1000	1860.00	11.53	124.17	192.50	3.23	29.99
	± 45.83	± 0.35	± 33.26	± 49.32	± 0.33	± 1.39
3000	1890.00	12.05	219.15	147.75	3.45	27.07 <sup>1)</sup>
	± 27.07	± 1.63	± 35.14	± 44.48	± 0.51	± 0.33
4000	1862.50	10.83	185.50	168.52	3.11	26.01 <sup>1)</sup>
	± 69.46	± 0.88	± 25.44	± 55.51	± 0.63	± 7.86

\* Mean value ± standard error. <sup>1)</sup> Significantly different (P<0.01) from control group by analysis of variance.

the body weights were essentially the same for the three groups supplemented dietary Zn and they were slightly larger than that of normal control. Organ weights of all groups were not affected by the addition of Zn to the diet except the testes. Comparison of organ weights data obtained within groups showed that the only significant change was a decrease in testes weights of the group received 4000 ppm dietary Zn. With the exception of the testes, no differences were found between the three groups and control in organ weights after the recovery period.

### Tissue Zn concentration

Data showing Zn concentration on wet weight basis of testes, adeno-hypophysis, adrenals, thyroids and pancreas are tabulated in Table 3. No significant differences were found between experimental groups and their control in Zn concentration of the testes, the trend indicated higher values in the group received 4000 ppm dietary Zn. As the levels of dietary Zn increased, a corresponding increase in Zn concentration of adrenals was detected. Adrenals of the group received 4000 ppm dietary Zn contained a significantly higher concentration of Zn than that of the control. Zn concentrations in the thyroids of the groups received the levels of 1000 and 3000 ppm dietary Zn were higher than that of the control, but the data were statistically not significant. The high level of 4000 ppm dietary Zn reduced the concentration of Zn in the thyroids but the reduction was not significant. The same trend occurred in the pancreas but the magnitude was higher in pancreas than that in the

**Table 3.** Effects of high dietary Zn levels on Zn concentration of testes, adrenals, thyroids and pancreas.

Zn added to the diet (ppm)	Tissue Zn concentration			
	Testes (ppm)	Adrenals (ppm)	Thyroids (ppm)	Pancreas (ppm)
<b>Experimental period</b>				
0	12.83*	32.34*	57.40*	47.19*
	± 1.53	± 6.90	± 25.31	± 9.30
1000	12.29	69.34 <sup>2)</sup>	69.61	61.53
	± 1.04	± 25.53	± 31.38	± 4.92
3000	15.62	74.41	71.80	133.66
	± 2.90	± 10.26	± 24.94	± 16.00
4000	22.09	59.62 <sup>1)</sup>	47.00	243.46 <sup>1)</sup>
	± 2.09	± 16.90	± 16.21	± 62.63
<b>Recovery period</b>				
0	12.03	45.93	89.35	37.36
	± 0.28	± 14.60	± 26.55	± 9.99
1000	11.53	64.01	67.43	42.59
	± 0.38	± 12.21	± 25.43	± 4.99
3000	10.50 <sup>2)</sup>	42.49	60.44	36.15
	± 1.78	± 6.69	± 16.50	± 4.65
4000	11.40 <sup>2)</sup>	52.27	46.82 <sup>1)</sup>	40.91
	± 1.69	± 6.59	± 7.18	± 7.83

\* Mean value ± standard error. <sup>1)</sup> Significantly different ( $p < 0.01$ ) from the control group by analysis of variance. <sup>2)</sup> Significantly different ( $p < 0.05$ ) from the control group by analysis of variance.

adrenals.

With the exception of the testes of the groups received the levels of 3000 and 4000 ppm dietary Zn, no significant changes were detected in Zn concentration of all organs after the recovery period.

### **Histological changes**

Histological examination of the testes revealed that the seminiferous tubules in the group receiving 1000 ppm dietary Zn had normal development. The majority of the tubules contained spermatids in advanced stages of development and spermatozoa and they were presented in a large percentage of tubules (Pl. III-Fig. 2). Seminiferous tubules diameter remained within normal limits. The interstitial cells were not increased. The testes from the group receiving 3000 ppm dietary Zn exhibited a delay in spermatogenesis. All of the seminiferous tubules were reduced in size as compared with that of the control, but not so seriously reduced as that of the group receiving 4000 ppm dietary Zn. In most of the tubules, spermatogenesis had not proceeded beyond the stage of primary spermatocytes. The interstitial cells were increased in number and size. The most noticeable effect of dietary Zn was evident in the seminiferous tubules of the group receiving 4000 ppm dietary Zn (Pl. III-Fig. 3. Compare with Pl. III-Fig. 1). They were markedly diminished in diameter and often irregular in contour. In all tubules the normal sequence in spermatogenesis was impaired. Spermatids and spermatozoa were completely absent in most tubules. Only Sertoli cells and spermatogonia were presented in seemingly good condition. There were hyperplasia in the interstitial cells. The interstitial tissue condensed possibly due to shrinkage of the seminiferous tubules. No obvious changes were detected in histological feature after the recovery period (Pl. III-Fig. 4).

Increased amount of PAS-positive materials of the basophils were apparent in the adenohypophysis of the group receiving 1000 ppm dietary Zn. This level did not appear to increase the number and size of the basophils. On the contrary, the number and size of the acidophils in caudal lobe were increased and the cytoplasmic granules stained intensely with orange G in these cells (Pl. IV-Fig. 6. Compare with Pl. IV-Fig. 5). The amphophils of the cephalic lobe increased distinctly in number, enlarged in size and occupied large area of the cephalic lobe. The enlarged amphophils were polygonal in shape with a large nucleus and contained faint granules which stained weakly with PAS method (Pl. IV-Fig. 9. Compare with Pl. IV-Fig. 8). These enlarged cells suggest an active functional phase of the cells.

Adenohypophysis of the group receiving 3000 ppm dietary Zn showed slight reduction in number and size of the basophils. PAS-positive materials were diminished. Some vacuoles occurred in these cells and may be inactive in hormone production. The acidophils appeared to be decreased in number and smaller in size than that in the group receiving 1000 ppm dietary Zn, but they were larger in number than that in normal control. The amphophils were identical to those found in the group receiving 1000 ppm dietary Zn except slight reduction in number.

The effects of 4000 ppm dietary Zn were marked in the adenohipophysis (Pl. IV-Figs. 7 and 10). Many of the basophils were shrunken and their cytoplasms were depleted of secretory granules, so that they were difficult to distinguish from chromophobes. The basophils also showed marked regressive changes, such as vacuolation of the cytoplasm, pyknosis of the nuclei and degranulation. There was marked reduction in size of the acidophils as compared with that in other experimental groups. They stained very lightly with orange G. The amphophils were enlarged to some extent and increased in number as compared with that in other groups. The cell boundaries were often less distinct. These morphological changes in the adenohipophysis of the cocks receiving 4000 ppm dietary Zn support the morphological changes in the testes as described previously. After the recovery period, the cellular activities were restored to normal condition in all groups.

In the group receiving 1000 ppm dietary Zn, the adrenal cortex was larger than that in the control. Hypertrophied cortex showed enlargement of the component cells throughout the gland. In addition to this, they reacted strongly with Sudan black and showed considerably more lipid as compared with that in the control (Pl. V-Figs. 13 and 14). Schultz cholesterol test was strongly positive for the hypertrophied cortex which suggested an increase in the cholesterol content. Concurrent with the cellular hypertrophy in the cortex, there was degranulation in the medullary cells. Adrenals of both groups receiving the levels of 3000 and 4000 ppm dietary Zn showed hypertrophy in the cortex as compared with that in the control (Pl. V-Fig. 15). A decrease in medullary cell granulation occurred in the groups received 3000 and 4000 ppm dietary Zn.

Histological examinations of the thyroids revealed no differences between groups were detected, indicating that these organs are more resistant to the changes in the levels of high dietary Zn.

Pancreatic tissue of the group receiving 1000 ppm dietary Zn appeared to be morphologically normal. There were well developed acini and numerous islets of Langerhans of various size which were characteristic of this gland.  $\alpha$ - and  $\beta$ -cells in the islets were heavily granulated. The acinar cells of the group receiving 3000 ppm dietary Zn were small, poor in cytoplasm and contained small densely granulated areas at the apical position of the cells. The islets of this group appeared to decrease in number and enlarged in size in comparison with that in control. Marked changes in the acini and islets of the pancreas of the group receiving 4000 ppm dietary Zn were observed (Pl. V-Fig. 17. Compare with Fig. 16). The acinar cells showed loss of zymogen and other cytoplasmic granules. Well developed connective tissue were found between the acini. In some parts, scattered acinar cells could be identified in the fibrous stroma and contained zymogen like granules. Some vacuoles appeared in these cells. The nuclei of these cells were stained strongly with HE stain. The islets of this group were enlarged and had irregular outlines but  $\beta$ -cells appeared to be larger than those of normal control and somewhat degranulated. After recovery period, the cytoplasmic granules in the acinar cells increased and the normal activity might reappeared in all groups. Signs

of recovery of all groups were observed in the acinar and islet cells histologically.

## DISCUSSION

The results of the present study indicate that the cocks tolerated the levels of 1000 and 3000 ppm dietary Zn without adverse effect. While the level of 4000 ppm dietary Zn adversely affected growth. Various factors that might contribute to poor growth with high levels of dietary Zn were enumerated and discussed (Roberson and Schaible, 1960; Johnson *et al.*, 1962). Besides these factors, the reduction of pituitary growth hormone secretion may be added, this assumption was supported by reduction in number and size of acidophils of the adenohypophysis in the present study (discussed later).

Spermatogenesis was qualitatively normal in the cocks received the level of 1000 ppm dietary Zn, as shown by the appearance of large numbers of mature spermatozoa in this study. Although the cockerels received the same level of dietary Zn from one day old to maturity did not show normal testicular development but a damage of seminiferous tubules and also germinal cells were observed (Eltohamy *et al.*, 1979). The possible explanation of these findings was that the physiological changes necessary to produce such an effect may be occur within the first 50 days of age. In support of this suggestion, it was found that the testes sensitivity to Zn appears at certain stage of testicular development. Clermont and Perey (1957) stated that the specific testicular function of Zn in some relation to the meiotic division began at the time of appearance of the first spermatocytes in rats. Generally, it can be stated that germinal cells of immature cockerels are more susceptible to this level of Zn than those of adult, Zn sensitivity decreased with an increase in the age of birds.

Considerable evidence is available which indicates the inhibitory effects of the levels of 3000 and 4000 ppm dietary Zn on the reproductive function in the cocks. These inhibitory effects reflected in the depression of testes and comb weights and high accumulation of Zn in the testes. Histological studies of such testes revealed a corresponding inhibition of the maturation division at the stage of spermatocytes resulted in delay of spermatogenesis and hyperplasia of the interstitial cells. These observations were strongly dependent on the levels of dietary Zn, suggested that the levels of dietary Zn were critical and the levels of 3000 and 4000 ppm used in the present study were excessive. In general, the severity of the effects of these levels of dietary Zn on the testicular tissue was directly related to the concentration of Zn in the testes. The marked accumulation of Zn in the testes from these levels of dietary Zn may show an excess of Zn over that required by the testes. This excess of Zn in the testes may interfere with some factors essential for maintenance of the efficiency of the testes to concentrate Zn at optimal levels and normal development of spermatogenesis.

Interstitial cells are also susceptible to the high levels of dietary Zn.



The hyperplasia detected in these cells in the group received the level of 4000 ppm dietary Zn may be due to temporal loss of testosterone (Lindsey *et al.*, 1969). The comb of this group was observed to be paler, less turgid and smaller than those of the other groups, indicating a decrease in androgen activity. In this regard, Zn was shown under certain conditions to have cancerogenic activity when injected as 5% solution of sulfate (Gunn *et al.*, 1964). Therefore, it seems that Zn has effects on spermatogenesis and also on interstitial cells.

The studies of the criteria involved showed that the changes induced by the high levels of dietary Zn were of a reversible character since each criterion reached a normal level after 2 weeks recovery of Zn. Subsequent decrease in the concentration of the testicular Zn paralleled further recovery of the germinal epithelium. It is obvious that the germinal epithelium beyond the stage of spermatocytes were not in a state of arrest, since they were able to produce spermatozoa in many of the tubules after the recovery period. On the basis of these observations it is postulated that, there is a definite delay in the formation of spermatocytes and spermatids and the late stage of spermatids failed to mature. Thus the inhibitory effects of high levels of dietary Zn on testicular maturation represent transient blockade and the maturation division of the spermatogonia can be considered as the primary site of action by dietary Zn.

From the present results it is assumed that the decrease in Zn storage in the testes after recovery period may reach the optimum value which is necessary for optimum maturation of the spermatogenesis and then presumably represent a return to normal level. The reversible character of the inhibitory action of the high levels of dietary Zn may be due to the high degree of resistance of spermatogonia. It is also evident that Sertoli cells are not directly concern with Zn.

In mammals, reptiles and amphibians, the acidophils of the adenohypophysis have been considered to be STH-producing cells (Purves, 1961). In birds there is little evidence for the presence of growth hormone although in domestic fowl it has been recently demonstrated (Harvey and Scanes, 1978). In the present study the acidophils increased in size and number in the adenohypophysis of the cocks received the level of 1000 ppm dietary Zn. It seems that this level of Zn has stimulating effect on the acidophils of the adenohypophysis. While the regressive changes in these cells of the group received the level of 4000 ppm dietary Zn suggest the inhibitory effects to the secretion of growth hormone. These proposal seem likely in view of the following results. Growth of the cocks received the level of 1000 ppm dietary Zn was normal and that received the level of 4000 ppm dietary Zn was reduced.

PAS-positive basophils of the adenohypophysis in the groups received the levels of 3000 and 4000 ppm dietary Zn were shrunken and partially degranulated. This may indicate reduced gonadotrophic activity of these cells. In PAS staining method, it is difficult to identify the granules in the basophils producing FSH or LH, therefore all basophil granules considered together. The degranulation of the basophils indicates reduced secretion of gonadotrophin.

Lack of FSH would inhibit spermatogenesis and may result in spermatogenic arrest. While lack of LH would inhibit androgen secretion of the testes which may result in hypogonadism. The present histological results of the testes are compatible with changes observed in the adeno-hypophysis. In these results, marked reduction in testes and comb weights and impairment of normal spermatogenesis in the groups received 3000 and 4000 ppm dietary Zn suggest impaired production and/or release of gonadotrophic hormone of the adeno-hypophysis. The reduction in number and size and degranulation of PAS-positive basophils of adeno-hypophysis in the same groups substantiate this.

It is difficult to ascertain whether the reduction of gonadotrophins of the adeno-hypophysis, which brought about by dietary Zn, is a direct effect of Zn on adeno-hypophysis or a secondary effect of the imbalance of the endocrine function induced by Zn on the testes. The results obtained by capon (Eltohamy *et al.*, unpublished) in which received intramuscular injection of Zn ammonium sulphate at the level of 10  $\mu$ C/100 g of body weight for 21 days indicated that the basophils of the capon increased in number and size and formed castration cells. These results may contribute to the view that the testes are affected directly by high dietary Zn. Similarly, Shikita and Tamaoki (1963) stated that the loss of  $^{65}\text{Zn}$  incorporation by the testes was independent of the pituitary and that its uptake after 24 hours irradiation was related to the interstitial cells. Whereas, Gunn *et al.* (1961) showed that ICSH plays an important role in the uptake of  $^{65}\text{Zn}$  in the mature rat testis. Hypophysectomy depressed  $^{65}\text{Zn}$  uptake, and ICSH administration prevented the fall of  $^{65}\text{Zn}$  uptake. Therefore, it seems probable that Zn has direct effect not only on the testes but also on the adeno-hypophysis.

In normal condition, the amphophils of the cephalic lobe were considered to be the source of adrenocorticotrophic hormone (ACTH) and their PAS-positive granules are the carrier substance of ACTH (Mikami, 1958). In the present study, the amphophils were in an active functional phase in all groups receiving Zn, and the storage of PAS-positive granules decreased. Increased ACTH release was also suggested by adrenal hyperplasia. The action of dietary Zn was amply demonstrated on the adrenals of all groups received Zn. This was shown by elevation of adrenal Zn concentration, enlargement of the cortical cells, hyperplasia and increase in mitotic activity, lipid and cholesterol content of the cortex. The indications were that the adrenal was active one. These changes closely paralleled the changes seen in the adeno-hypophysis. The maximum effect was occurred with the level of 4000 ppm dietary Zn. This may be taken, perhaps, to indicate the correlation between adrenal activity and dietary Zn levels.

The decreased granulation of adrenal medullary cells may lead to the assumption that medullary tissue was also affected by high dietary Zn. It would appear that high dietary Zn may inhibit the synthesis or storage of catecholamines in the medullary granules or accelerate the release of them. It is known that catecholamine promotes the release of adeno-hypophysial ACTH which in turn stimulates the adrenal cortex.

The mechanism of the stimulation of the adrenals by dietary Zn was not

entirely clear, although several possibilities seem tenable. These could result from different sites, including a direct effect on the adrenal cortex or medulla, direct effect on the adenohypophysis control of the secretion of ACTH, or indirect effect *via* the testes (*via* steroid feed back). The third possibility seems more likely in which the regressive changes detected in the testes led to development of castration phenomena. In accordance with this, the adrenal changes were observed. In support of this suggestion, Rudzik and Riedel (1960) reported that the incorporation of  $^{65}\text{Zn}$  into the testes decreased after adrenalectomy.

The exocrine and endocrine tissues in the pancreas of the group received 1000 ppm dietary Zn were found to be normal in morphology despite the high concentration of Zn in this organ was detected. The same level has been reported to induce changes in exocrine portion of the pancreas, but not in the endocrine portion in the immature cockerels (Eltohamy *et al.*, 1979). This leads to a belief that pancreas of mature cock is more resistant to the level of 1000 ppm dietary Zn than that of the immature cockerels. It is evident that pancreatic tissue involving both acinar and islet cells was affected in the group receiving 4000 ppm dietary Zn. There may be specific inhibition of functional activity in acinar cells and that in  $\beta$ -cells in endocrine portion. The  $\beta$ -cells granulation was decreased and in turn insuline production may be diminished. The degranulation of zymogen granules and loss of cytoplasmic basophilia (presumed to reflect the nucleoprotein content of the cell) might construe to inhibition of protein synthesis in the same group. The same observation was seen in the pancreas of rat fed Zn deficient diet (Holtzer and Van Lancker, 1962). They related these changes to the release of amylase and ribonuclease from the zymogen granules into cytoplasm which were responsible to pancreatic autolysis. The role of high levels of dietary Zn in these diverse cellular activities was further emphasized by the finding that removal of Zn from the diet of the cocks was found to produce an increase in the granule contents of the acinar and islets cells and a return to normal condition was occurred. The characteristic arrangement of the parenchyma was restored.

#### REFERENCES

- Clermont, Y. and B. Perey 1957 Quantitative study of the cell population of the seminiferous tubules in immature rats. *Amer. J. Anat.*, **100**: 241-245
- Eltohamy, M. M., H. Takahara and M. Okamoto 1979 Effects of dietary Zn levels on the histological changes produced in White Leghon cockerels. *J. Fac. Agr., Kyushu Univ.*, **24**: 11-21
- Feaster, J. P., S. L. Hansard, J. T. McCall, F. H. Skipper and G. K. Davis 1954 Absorption and distribution of radiozinc in steers fed high zinc rations. *J. Anim. Sci.*, **13**: 781-788
- Grant-Frost, D. R. and E. J. Underwood 1958 Zinc toxicity in the rat and its interrelation with copper. *Australian J. Exp. Biol. Med. Sci.*, **36**: 339-346
- Gunn, S. A., T. C. Gould and W. A. D. Anderson 1961 Hormonal control of Zn in mature rat testis. *J. Endocr.*, **23**: 37-45
- Gunn, S. A., T. C. Gould and W. A. D. Anderson 1964 Effect of Zinc on cancerogenesis

- by Cadmium. *Proc. Soc. Exp. Med.*, **115**: 653-657
- Harvey, S. and C. G. Scanes 1978 The effect of adrenaline and adrenergic antagonists and agonists on growth hormone secretion in the domestic fowl. *Gen. Comp. Endoc.*, **34**: 69-70
- Holtzer, R. L. and J. L. Van Lancker 1962 Early changes in pancreatic autolysis. *Am. J. Pathol.*, **40**: 331-336
- Johnson, D. Jr., L. M. Arnin, Jr., F. X. Savino and H. W. Titus 1962 The tolerance of growing chickens for dietary Zn. *Poult. Sci.*, **41**: 311-317
- Lindsey, S., C. W. Nichols, G. E. Sheline and I. L. Chaikoff 1969 Leydig cell tumors in rat testes subjected to low dose X irradiation. *Radiat. Res.*, **40**: 366-378
- Mawson, C. A. and M. I. Fischer 1953 Zinc and carbonic anhydrase in human semen. *Biochem. J.*, **55**: 669-672
- Mikami, S. 1958 The cytological significance of regional patterns in the adenohypophysis of the fowl. *J. Agr., Iwate Univ.*, **3**: 473-545
- Miller, M. J., P. V. Elcoate, M. I. Fischer and C. A. Mawson 1958 The effects of dietary Zn deficiency on reproductive system of male rats. *Can. J. Biochem. Physiol.*, **36**: 557-569
- Montgomery, M. L., G. E. Sheline and I. L. Chaikoff 1943 The elimination of administrated zinc in the pancreatic juice, duodenal juice, and bile of the dog as measured by its radioactive isotope (Zn-65). *J. Exp. Med.*, **78**: 151-159
- Purves, H. D. 1961 Morphology of the hypophysis related to its function. In "Sex and Internal Secretion", Vol. 1, ed. by W. C. Young, Williams and Wilkins, Baltimore, pp. 161-239
- Roberson, R. H. and P. J. Schaible 1960 The tolerance of growing chicks for high levels of different forms of zinc. *Poult. Sci.*, **39**: 893-896
- Rudzik, A. D. and B. E. Riedel 1960 The effect of adrenalectomy and cortisone on zinc metabolism in the sex glands and adrenal of the male rat. *Can. J. Biochem. Physiol.*, **38**: 845-851
- Shikita, M. and B. Tamaoki 1963 Influence of X irradiation on zinc-65 uptake of the testes in mice. *Radiat. Res.*, **19**: 419-428

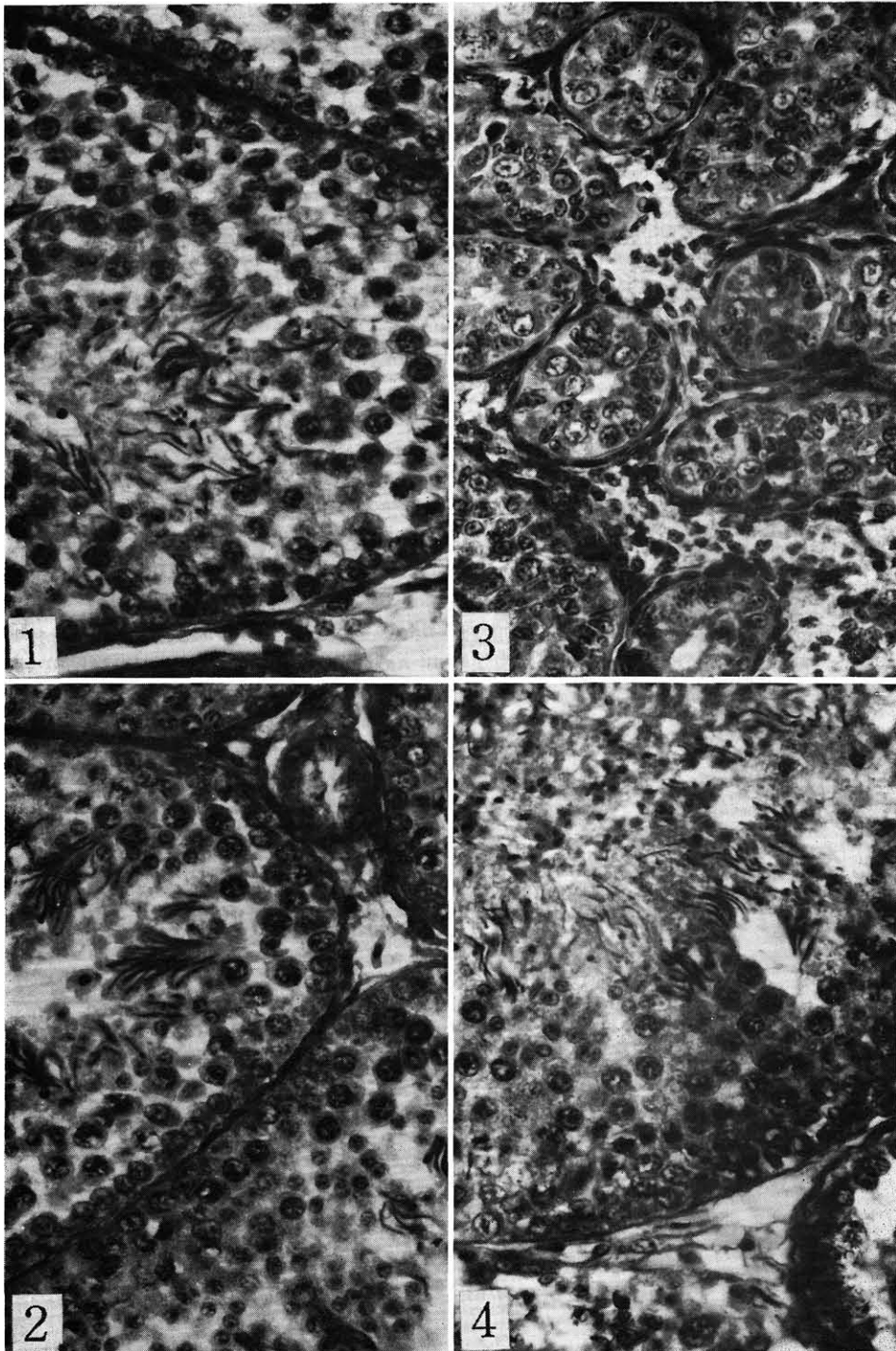
### Explanation of Plate III

**Fig. 1.** Testis from a cock fed the basal diet. Seminiferous tubules show orderly maturation of germinal cells. HE stain.  $\times 400$ .

**Fig. 2.** Testis from a cock fed the diet supplemented by 1000 ppm Zn. Seminiferous tubules show various stages of spermatogenesis. Spermatozoa present in large percentage of the tubules. HE stain.  $\times 400$ .

**Fig. 3.** Testis from a cock fed the diet supplemented by 4000 ppm Zn. Seminiferous tubules diminished in diameter. Spermatids and spermatozoa are completely absent. The tubules lined by Sertoli cells and spermatogonia. Interstitial cells are increased in number. HE stain.  $\times 400$ .

**Fig. 4.** Testis from a cock fed the basal diet after the recovery period. Note the complete stages of spermatogenesis and uniform tubular structure. There appears to be improved as compared with Fig. 1. HE stain.  $\times 400$ .



Histological Effects of Zinc in the Cocks

#### Explanation of Plate IV

**Fig. 5.** Caudal lobe of adenohypophysis from a cock fed the basal diet. Acidophils are numerous and uniformly granulated stained with orange G and acid fuchsin. Basophils have also numerous granules stained with methyl green and the cell boundaries are well defined. Matsuo tetrachrome stain.  $\times 400$ .

**Fig. 6.** Caudal lobe of adenohypophysis from a cock fed the diet supplemented by 1000 ppm Zn. Acidophils are increased in number and size. Basophils have normal appearance. Matsuo tetrachrome stain.  $\times 400$ .

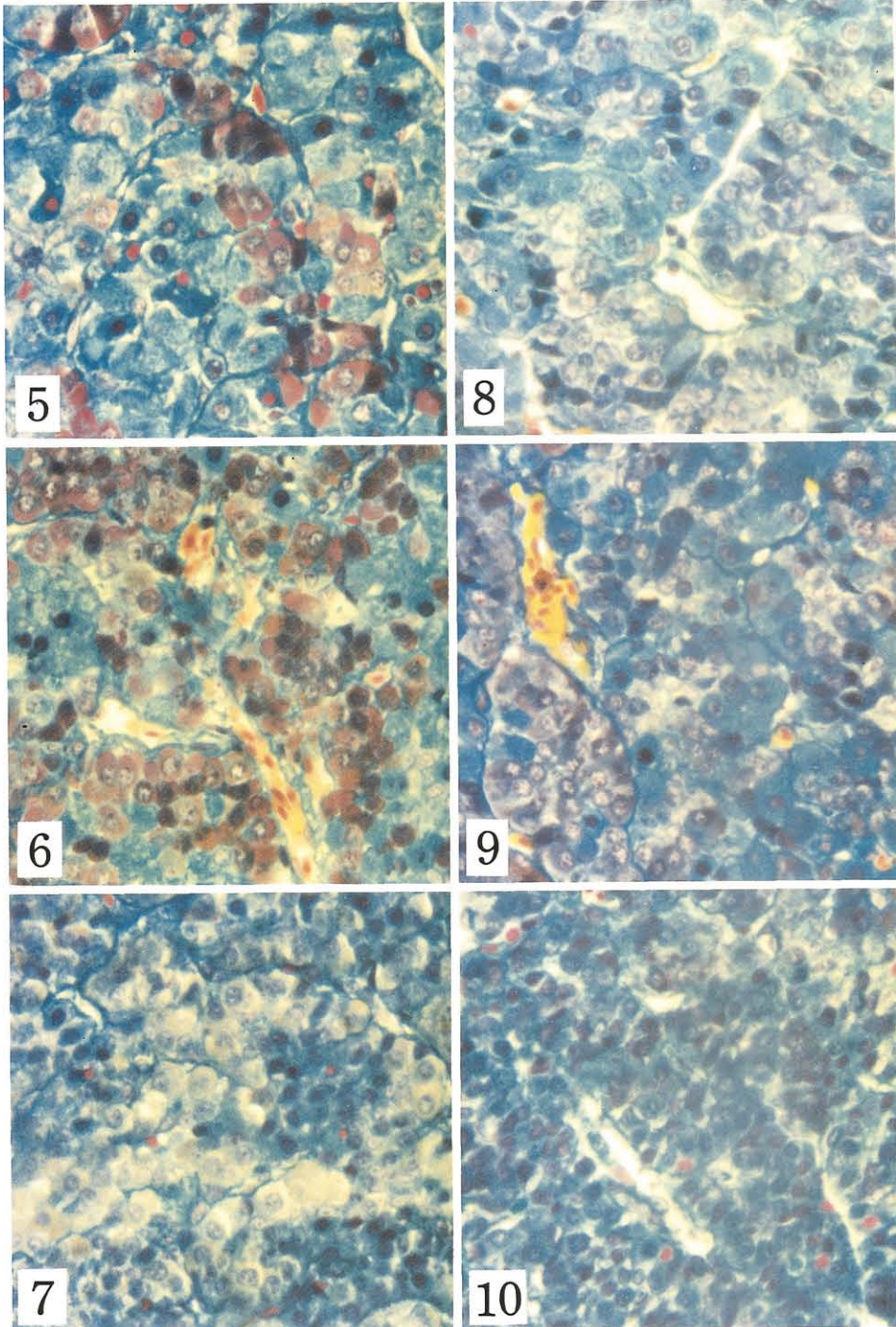
**Fig. 7.** Caudal lobe of adenohypophysis from a cock fed the diet supplemented by 4000 ppm Zn. Note increased severity of regressive changes in acidophils and basophils. Basophils are remarkably decreased and poorly granulated and their nuclei showed pyknosis. Matsuo tetrachrome stain.  $\times 400$ .

**Fig. 8.** Cephalic lobe of adenohypophysis from a cock fed the basal diet. Amphophils and basophils are numerous and granulated. Matsuo tetrachrome stain.  $\times 400$ .

**Fig. 9.** Cephalic lobe of adenohypophysis from a cock fed the diet supplemented by 1000 ppm Zn. Amphophils increased in number, and have numerous granules stained intensely with acid violet. Basophils have the normal appearance. Matsuo tetrachrome stain.  $\times 400$ .

**Fig. 10.** Cephalic lobe of adenohypophysis from a cock fed the diet supplemented by 4000 ppm Zn. Basophils decreased in number and size and their nuclei showed pyknosis. Amphophils are degranulated. Compare with Figs. 8 and 9. Matsuo tetrachrome stain.  $\times 400$ .





Histological Effects of Zinc in the Cocks



#### Explanation of Plate V

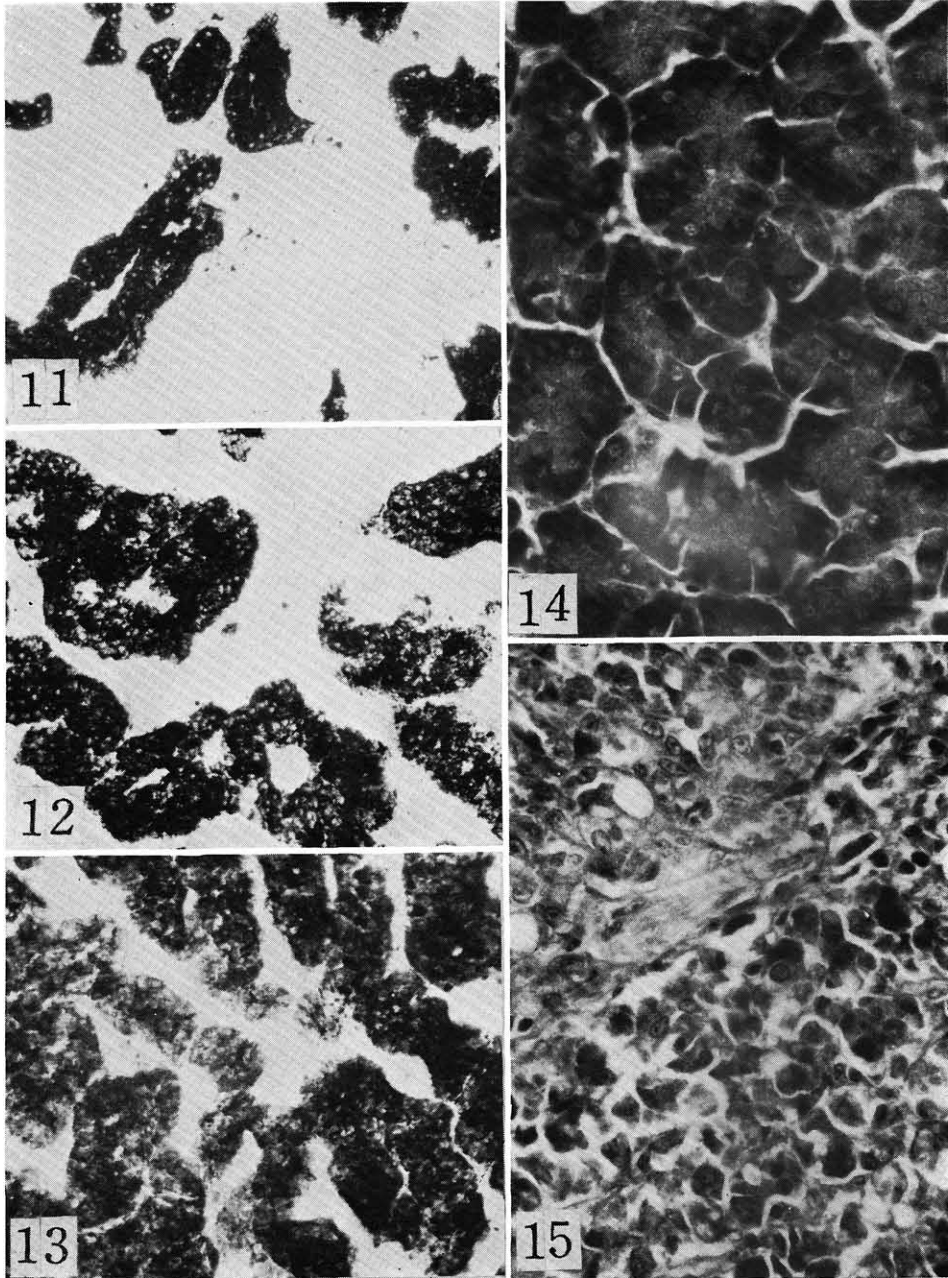
**Fig. 11.** Adrenal from a cock fed the basal diet. Cortical areas stain with Sudan black, while medullary regions are colorless. Sudan black stain.  $\times 100$ .

**Fig. 12.** Adrenal from a cock fed the diet supplemented by 1000 ppm Zn. Note the size of cortical area. Sudan black stain.  $\times 100$ .

**Fig. 13.** Adrenal from a cock fed the diet supplemented by 4000 ppm Zn. Note the hypertrophy of the cortical mass. Compare with Figs. 11 and 12. Sudan black stain.  $\times 100$ .

**Fig. 14.** Pancreas from a cock fed the basal diet. The acini filled with zymogen granules are noted. HE stain.  $\times 400$ .

**Fig. 15.** Pancreas from a cock fed the diet supplemented by 4000 ppm Zn. Well developed fibrous tissue are noted. HE stain.  $\times 400$ .



Histological Effects of Zinc in the Cocks