

Sagittal Cutting Error Changes Femoral Anteroposterior Sizing in Total Knee Arthroplasty

中原, 寛之

<https://doi.org/10.15017/1441096>

出版情報：九州大学, 2013, 博士（医学）, 課程博士
バージョン：
権利関係：やむを得ない事由により本文ファイル非公開（2）

All authors have read and agreed with the contents of this revised manuscript.

Sagittal Cutting Error Changes Femoral Anteroposterior Sizing in Total Knee Arthroplasty

Running title: Influence of Cutting Error in TKA

Hiroyuki Nakahara MD, Shuichi Matsuda MD, PhD Ken Okazaki MD, PhD,
Yasutaka Tashiro MD, PhD, Yukihide Iwamoto MD, PhD

Received: December 19, 2011

Accepted:

H. Nakahara, S. Matsuda (✉), K. Okazaki, Y. Tashiro, Y. Iwamoto
Department of Orthopaedic Surgery, Graduate School of Medical Sciences, Kyushu
University, 3-1-1 Maidashi, Higashi-ku, Fukuoka 812-8582, Japan
email: mazda@ortho.med.kyushu-u.ac.jp

Each author certifies that he or she, or a member of his or her immediate family, has no commercial associations (eg, consultancies, stock ownership, equity interest, patent/licensing arrangements, etc) that might pose a conflict of interest in connection with the submitted article.

All ICMJE Conflict of Interest Forms for authors and *Clinical Orthopaedics and Related Research* editors and board members are on file with the publication and can be viewed on request.

Each author certifies that his or her institution has approved the human protocol for this investigation, that all investigations were conducted in conformity with ethical principles of research, and that informed consent for participation in the study was obtained.

AU: Please do not delete query boxes or remove line numbers; ensure you address each query in the query box. You may modify text within selected text or outside the selected text (as appropriate) without deleting the query.

Abstract

Background Prosthetic alignment and size are important factors in achieving a long-term survival in TKA. Although two-dimensional and three-dimensional (3D) planning for component sizing has been introduced, it sometimes is difficult to cut the bones accurately according to preoperative planning. It is unclear whether changing sagittal alignment of the distal femur affects the AP dimension and sizing of the prepared bone.

Questions/purposes We therefore determined whether the AP dimension of the prepared distal femur increases if the distal femur is cut in extension and decreases if it is cut in flexion.

Methods One hundred knees were evaluated using 3D imaging software. The AP dimension of the cutting surface was measured when the femoral component was aligned perpendicular to the anatomic axis. The measurement was repeated when the distal bone cut was planned in flexed positions of 3° and 5° and extended positions of 3° and 5°.

Results The AP dimension of the prepared femur was increased by 2 and 3 mm with 3°

AU: Please do not delete query boxes or remove line numbers; ensure you address each query in the query box. You may modify text within selected text or outside the selected text (as appropriate) without deleting the query.

and 5° extension, respectively. The AP dimension of the prepared femur was decreased by 2 and 3 mm with 3° and 5° flexion, respectively.

Conclusions Our data suggest upsizing or downsizing of the femoral component can occur if the femoral osteotomy is performed in at least 3° extension or flexion.

Level of Evidence Level II, diagnostic study. See Guidelines for Authors for a complete description of levels of evidence.

AU: Please do not delete query boxes or remove line numbers; ensure you address each query in the query box. You may modify text within selected text or outside the selected text (as appropriate) without deleting the query.

Introduction

TKA is one of the most successful treatments for advanced arthritis [10, 16, 17].

Detailed preoperative planning can help achieve desired alignment and sizing.

Femoral AP and mediolateral sizing mismatches are frequent in TKA [6, 11]. Overhang of components may cause knee pain and increments of patellofemoral joint pressure [8, 11]. However, underhang may increase bleeding into the knee and permit increased osteolysis [6]. The size and shape of the prosthesis are determined by a gross estimate of the morphologic features of the knee. A cutting error of the distal femur might result in selecting larger or smaller implants compared with the patient's anatomy, causing a sizing mismatch between the AP and mediolateral dimensions. These errors are attributable to the difficulty in accurately cutting the bone according to preoperative planning [1, 18].

Changing sagittal alignment of the distal femur might affect the AP dimension and sizing of the prepared bone with the anterior referencing method. To avoid anterior notching, the femoral component can be located anteriorly when the component is placed in an extended position. When the distal femur is cut in a flexed position, the

AU: Please do not delete query boxes or remove line numbers; ensure you address each query in the query box. You may modify text within selected text or outside the selected text (as appropriate) without deleting the query.

femoral component can be located posteriorly to avoid an anterior space between the implant and bone. Varying the AP position of the component also would change AP sizing. However, it is unclear whether and to what degree a distal femoral cutting error in the sagittal plane influences the AP dimension and size of the femoral component.

We therefore asked the following questions: (1) Does the AP dimension of the prepared distal femur increase if the distal femur is cut in extension and does the dimension decrease if it is cut in flexion? (2) Are these changes large enough to result in the need for a different size implant if the distal femur is cut in flexed or extended positions of 3° and 5° ?

Patients and Methods

We retrospectively evaluated 100 knees in 90 patients who had varus deformities before TKA. There were 18 men and 82 women. The average (\pm SD) age of the patients was 74.9 ± 8.0 years and the average hip-knee-ankle angle of the knees was $12.0^\circ \pm 6.3^\circ$ in varus. We excluded patients who had valgus deformities or a history of previous knee surgery.

All measurements were performed using 3D imaging software for the bisurface

AU: Please do not delete query boxes or remove line numbers; ensure you address each query in the query box. You may modify text within selected text or outside the selected text (as appropriate) without deleting the query.

prosthesis (3D template version 02.02.02; Japan Medical Materials Corp, Osaka, Japan) based on the CT data. All patients had a CT scan of the affected limb. The AP dimensions in standard, flexed, and extended positions were measured as follows. First, the femoral component was aligned perpendicular to the mechanical axis in the coronal plane (Fig. 1A) and parallel to the surgical epicondylar axis in the axial plane (Fig. 1B). Planning then was performed in the sagittal plane to align the femoral component perpendicular to the femoral anatomic axis. The anatomic axis was defined as a line connecting the middle point of the femoral axis 15 cm and 5 cm proximal from the femoral intercondylar fossa (Fig. 2). We chose the appropriate femoral component size so there was no excessive overhang of the component from the femoral lateral posterior condyle. The AP position of the femoral component was adjusted so that the anterior lateral flange of the component did not notch the anterior bone cortex (Fig. 3). The AP dimension of the prepared femur was measured from the point where the anterior lateral flange contacted the anterior cortex to the most posterior part of the lateral femoral condyle. This measurement was performed on the line parallel to the distal cutting surface (Fig. 3). The measurement then was repeated when the distal bone cut was planned in flexed positions of 3° and 5° (Fig. 4A) and extended positions

AU: Please do not delete query boxes or remove line numbers; ensure you address each query in the query box. You may modify text within selected text or outside the selected text (as appropriate) without deleting the query.

of 3° and 5° (Fig. 4B). A 3-mm change in AP dimension would result in the use of a different size implant.

We assessed intraobserver or interobserver variability in the measurements by intraclass or interclass correlation coefficients using an ANOVA. The intraclass correlation coefficient was calculated from data derived from the three measurements performed by one observer (HN) on 10 knees. The interclass correlation coefficient was calculated from the average of the three measurements of one observer (NH) and the data from two observers (SK, SO) on the same 10 knees. The intraclass correlation coefficient for the three measurements conducted by the same examiner was 0.86, whereas the interclass correlation coefficient for the average of the three measurements of one examiner and the two other examiners was 0.92. We compared the AP dimensions of the distal femur in 3° and 5° extended or flexed positions with the AP dimensions in the standard position using the Wilcoxon signed-rank test. Statistical analyses were performed using JMP software (Version 8.0; SAS Institute, Cary, NC, USA).

Results

AU: Please do not delete query boxes or remove line numbers; ensure you address each query in the query box. You may modify text within selected text or outside the selected text (as appropriate) without deleting the query.

The AP dimension of the prepared femur was increased in the extended position and decreased in the flexed position (Table 1). The dimension was increased by 1.8 ± 0.6 mm (range, 0.1–3.2 mm) with 3° extension and by 3.1 ± 0.7 mm (range, 0.7–5.2 mm) with 5° extension compared with the standard position. The rates of knees in which the dimension changed by greater than 2 mm were 43% (3° extension) and 96% (5° extension) (Fig. 5). The dimension was decreased by 1.5 ± 0.6 mm (range, 0.1–3.5 mm) with 3° flexion and by 2.6 ± 0.6 mm (range, 1.2–4.2 mm) with 5° flexion compared with the standard position. The rates of knees in which the dimension changed by greater than 2 mm were 18% (3° flexion) and 83% (5° flexion) (Fig. 6). We observed a difference ($p < 0.001$) in the AP diameter of the distal femoral component between knees with standard position and knees with 3° or 5° of extended cutting or with 3° or 5° of flexed cutting (Table 1).

The rates of knees in which the femoral components increased in size were 2% (3° extension) and 57% (5° extension). The rates of knees in which the femoral components decreased in size were 2% (3° flexion) and 31% (5° flexion).

Discussion

AU: Please do not delete query boxes or remove line numbers; ensure you address each query in the query box. You may modify text within selected text or outside the selected text (as appropriate) without deleting the query.

Correct sizing of implants is an important factor in the long-term survival rate and function of a TKA [3, 7]. Preoperative planning is an important aspect of the surgical procedure. The technical goals of preoperative planning for TKA are to achieve optimal alignment and sizing of the prostheses [9]. Although two-dimensional and 3D templating systems have been developed for TKA, it is difficult to predict the intraoperative size of the component accurately even if a 3D method is used. We therefore addressed the following questions: (1) Does the AP dimension of the prepared distal femur increase if the distal femur is cut in extension and does the dimension decrease if it is cut in flexion? (2) Are these changes large enough to result in the need for a different size implant if the distal femur is cut in flexed and extended positions of 3° and 5°?

Readers should be aware of the limitations of our study. First, the ideal position of the femoral component in the sagittal plane is controversial. If the femoral component is aligned perpendicular to the mechanical axis in the sagittal plane, the femoral component would be placed in extension to the anatomic axis in a patient with anterior femoral bowing. Since we refer to the distal anatomic axis to align the femoral

AU: Please do not delete query boxes or remove line numbers; ensure you address each query in the query box. You may modify text within selected text or outside the selected text (as appropriate) without deleting the query.

component, the influence of femoral bowing does not affect our results. We believe the cutting error of the distal femur would similarly influence the AP dimension even when preoperative planning indicates perpendicular alignment to the mechanical axis.

Second, we aligned the femoral component parallel to the surgical epicondylar axis in the axial plane. If the femoral component is aligned in reference to the other axis, the AP dimensions of the distal femur might change. Third, the bisurface knee system has an open internal femoral component geometry. If other prostheses such as those having closed or parallel internal geometry are used, variance of femoral AP dimensions might differ from those in our study.

Our data suggest inaccurate sagittal bone cutting changes the AP dimension of the cutting surface and the AP position of the component. Cutting errors can be caused by the entry point on the distal femur with the use of femoral intramedullary guides, space between the distal femoral cutting guide and the bone saw, mobility of the cutting guide during osteotomy, and flexure of the bone saw edge [13, 14, 15]. We previously reported that 70% of the distal femurs tended to be cut in extension with respect to the targeted alignment even if the distal femoral cutting guide was aligned in the desired

AU: Please do not delete query boxes or remove line numbers; ensure you address each query in the query box. You may modify text within selected text or outside the selected text (as appropriate) without deleting the query.

position [12]. The AP dimension of the distal femur was increased with 3° and 5° extension and decreased with 3° and 5° flexion compared with the standard position. This is because the position was determined by anterior referencing to avoid anterior notching or gap formation between the anterior flange and the anterior cortex. Changing the AP distal femur would result in selecting a femoral component size different from the planned size. In most total knee systems, the AP dimension of the femoral component increases 2 to 4 mm for each size. In our study, the rate of knees in which the dimension changed by greater than 2 mm was 43% if the distal femur was cut in 3° extension and 18% if the distal femur was cut in 3° flexion. These observations suggest femoral component upsizing or downsizing can occur if the distal femoral osteotomy is performed in at least 3° extension or flexion compared with the distal femoral anatomic axis. Femoral AP and mediolateral sizing mismatches are frequent problems. Hitt et al. [6] reported that undersizing of either component could leave cancellous bone exposed, which could be a source of increased bleeding in the knee and may permit increased osteolysis from wear debris. Mahoney and Kinsey [11] reported the presence of femoral component overhang of 3 mm or greater in at least

AU: Please do not delete query boxes or remove line numbers; ensure you address each query in the query box. You may modify text within selected text or outside the selected text (as appropriate) without deleting the query.

one zone was associated with a 90% increase in the odds of knee pain 2 years after surgery. AP and lateral prosthetic dimensions have been designed from the average morphologic features of the human knee. Narrow femoral components have been introduced to avoid overhang, especially for small or for female patients [4, 5]. Overall, many TKA prostheses have increased size variations to achieve better fit. Although shape and size of the components have been modified, as our study shows, even a few degrees of cutting error can increase the risk of component overhang or underhang. With this in mind, it is important to know how to verify accuracy in distal femur cutting. The use of a navigation system is the best way to evaluate alignment of the cutting surface [2]. With the conventional technique, the distal femur tended to be cut in extension with respect to the targeted alignment even if the distal femoral cutting guide was aligned in the desired position [12]. Alignment of the cutting surface should be checked repeatedly so that it is parallel to the slot of the cutting guide and to confirm whether the intraoperative femoral component size is same as the one chosen during preoperative planning.

We found the AP dimension of the distal femoral cutting surface increased when the

AU: Please do not delete query boxes or remove line numbers; ensure you address each query in the query box. You may modify text within selected text or outside the selected text (as appropriate) without deleting the query.

distal femur was cut in extension and decreased when it was cut in flexion, compared with the standard position being aligned perpendicular to the distal femoral anatomic axis in the sagittal plane. Upsizing or downsizing of the femoral component can occur if the femoral osteotomy is performed in at least 3° flexion or extension.

AU: Please do not delete query boxes or remove line numbers; ensure you address each query in the query box. You may modify text within selected text or outside the selected text (as appropriate) without deleting the query.

Acknowledgments

We thank Shinya Kawahara MD and Shigetoshi Okamoto MD for assistance with the interobserver trial.

AU: Please do not delete query boxes or remove line numbers; ensure you address each query in the query box. You may modify text within selected text or outside the selected text (as appropriate) without deleting the query.

References

1. Aslam N, Lo S, Nagarajah K, Pasapula C, Akmal M. Reliability of preoperative templating in total knee arthroplasty. *Acta Orthop Belg.* 2004;70:560-564.
2. Catani F, Biasca N, Ensini A, Leardini A, Bianchi L, Digennaro V, Giannini S. Alignment deviation between bone resection and final implant positioning in computer-navigated total knee arthroplasty. *J Bone Joint Surg Am.* 2008;90:765-771.
3. Daluga D, Lombardi AV Jr, Mallory TH, Vaughn BK. Knee manipulation following total knee arthroplasty: analysis of prognostic variables. *J Arthroplasty.* 1991;6:119-128.
4. Greene KA. Gender-specific design in total knee arthroplasty. *J Arthroplasty.* 2007;22(7 suppl 3):27-31.
5. Harwin SF, Greene KA, Hitt K. Early experience with a new total knee implant: maximizing range of motion and function with gender-specific sizing. *Surg Technol Int.* 2007;16:199-205.

AU: Please do not delete query boxes or remove line numbers; ensure you address each query in the query box. You may modify text within selected text or outside the selected text (as appropriate) without deleting the query.

6. Hitt K, Shurman JR 2nd, Greene K, McCarthy J, Moskal J, Hoeman T, Mont MA. Anthropometric measurements of the human knee: correlation to the sizing of current knee arthroplasty systems. *J Bone Joint Surg Am.* 2003;85(suppl 4):115-122.
7. Insall JN, Dorr LD, Scott RD, Scott WN. Rationale of the Knee Society clinical rating system. *Clin Orthop Relat Res.* 1989;248:13-14.
8. Kawahara S, Matsuda S, Fukagawa S, Mitsuyasu H, Nakahara H, Higaki H, Shimoto T, Iwamoto Y. Upsizing the femoral component increases patellofemoral contact force in total knee replacement. *J Bone Joint Surg Br.* 2012;94:56-61.
9. Krackow KA. Total knee arthroplasty: technical planning and surgical aspects. *Instr Course Lect.* 1986;35:272-282.
10. Laskin RS. The Genesis total knee prosthesis: a 10-year followup study. *Clin Orthop Relat Res.* 2001;388:95-102.
11. Mahoney OM, Kinsey T. Overhang of the femoral component in total knee arthroplasty: risk factors and clinical consequences. *J Bone Joint Surg Am.* 2010;92:1115-1121.

AU: Please do not delete query boxes or remove line numbers; ensure you address each query in the query box. You may modify text within selected text or outside the selected text (as appropriate) without deleting the query.

12. Nakahara H, Matsuda S, Moro-Oka TA, Okazaki K, Tashiro Y, Iwamoto Y. Cutting error of the distal femur in total knee arthroplasty by use of a navigation system. *J Arthroplasty*. 2011 Oct 20. [Epub ahead of print]
13. Otani T, Whiteside LA, White SE. Cutting errors in preparation of femoral components in total knee arthroplasty. *J Arthroplasty*. 1993;8:503-510.
14. Plaskos C, Hodgson AJ, Inkpen K, McGraw RW. Bone cutting errors in total knee arthroplasty. *J Arthroplasty*. 2002;17:698-705.
15. Reed SC, Gollish J. The accuracy of femoral intramedullary guides in total knee arthroplasty. *J Arthroplasty*. 1997;12:677-682.
16. Rodriguez JA, Bhende H, Ranawat CS. Total condylar knee replacement: a 20-year followup study. *Clin Orthop Relat Res*. 2001;388:10-17.
17. Scott WN, Rubinstein M, Scuderi G. Results after knee replacement with a posterior cruciate-substituting prosthesis. *J Bone Joint Surg Am*. 1988;70:1163-1173.
18. The B, Diercks RL, van Ooijen PM, van Horn JR. Comparison of analog and digital preoperative planning in total hip and knee arthroplasties: a prospective study of 173 hips and 65 total knees. *Acta Orthop*. 2005;76:78-84.

AU: Please do not delete query boxes or remove line numbers; ensure you address each query in the query box. You may modify text within selected text or outside the selected text (as appropriate) without deleting the query.

Legends

Fig. 1A-B The femoral component was aligned (A) perpendicular to the mechanical axis in the coronal plane and (B) parallel to the surgical epicondylar axis in the axial plane.

Fig. 2 The anatomic axis was defined as a line connecting the middle point of the femoral axis 15 cm proximal from the femoral intercondylar fossa (A) and the middle point of the femoral axis 5 cm proximal from the femoral intercondylar fossa (B).

Fig. 3 Measurement of the AP dimension of the distal femur in standard planning is shown. The distance from the anterior cortex to the most posterior point of the lateral posterior condyle of the bone is measured.

Fig. 4A-B (A) The increment of the AP dimension of the distal femur in 5° flexion is shown. The measurement is drawn parallel to the distal cutting surface. (B) The decrement of the AP dimension of the distal femur in 5° extension is shown.

Fig. 5A-B The graphs show the number of knees with differences in AP dimension of the distal femur in (A) 3° or (B) 5° extension.

AU: Please do not delete query boxes or remove line numbers; ensure you address each query in the query box. You may modify text within selected text or outside the selected text (as appropriate) without deleting the query.

Fig. 6A–B The graphs show the number of knees with differences in AP dimension of the distal femur in (A) 3° or (B) 5° flexion.

AU: Please do not delete query boxes or remove line numbers; ensure you address each query in the query box. You may modify text within selected text or outside the selected text (as appropriate) without deleting the query.

Table 1. AP dimensions for different cutting angles of the distal femur in the sagittal plane

Femoral cutting angle	AP dimension (mm)	
	Mean \pm SD	Range
Standard	52.6 \pm 3.2	46.1–62.5
3° extension	54.4 \pm 3.2	47.4–64.5
5° extension	55.7 \pm 3.3	49.0–65.3
3° flexion	51.2 \pm 3.0	45.2–60.1
5° flexion	50.0 \pm 2.9	44.3–58.9

*p < 0.05.

AU: Please do not delete query boxes or remove line numbers; ensure you address each query in the query box. You may modify text within selected text or outside the selected text (as appropriate) without deleting the query.

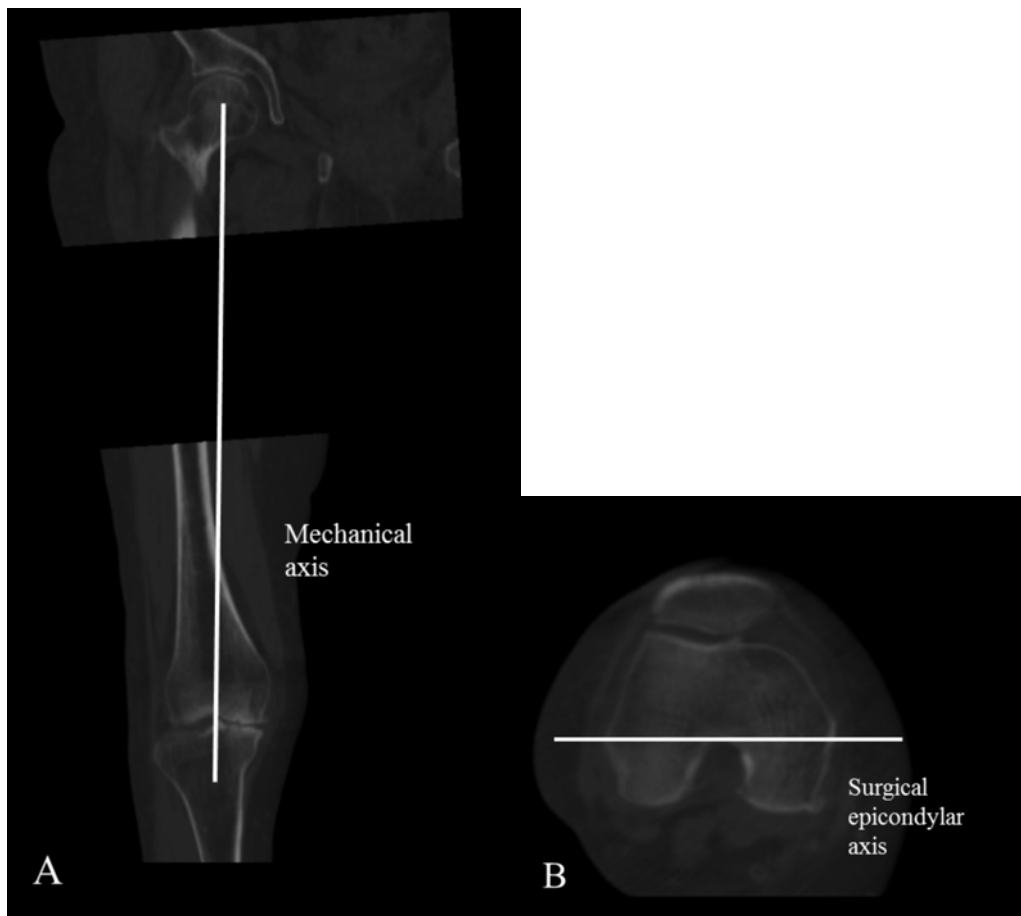


Fig. 1A-B

AU: Please do not delete query boxes or remove line numbers; ensure you address each query in the query box. You may modify text within selected text or outside the selected text (as appropriate) without deleting the query.

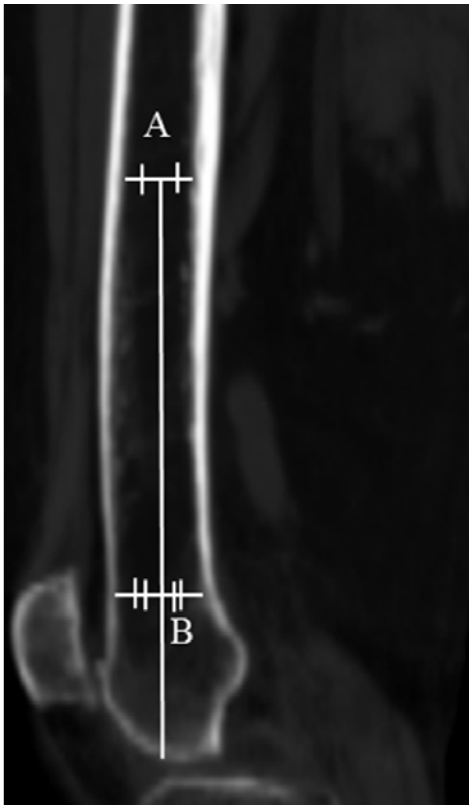


Fig. 2

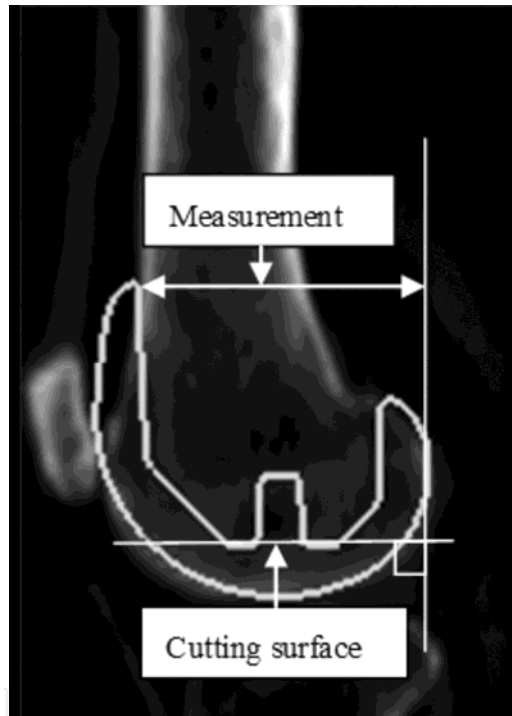


Fig. 3

AU: Please do not delete query boxes or remove line numbers; ensure you address each query in the query box. You may modify text within selected text or outside the selected text (as appropriate) without deleting the query.

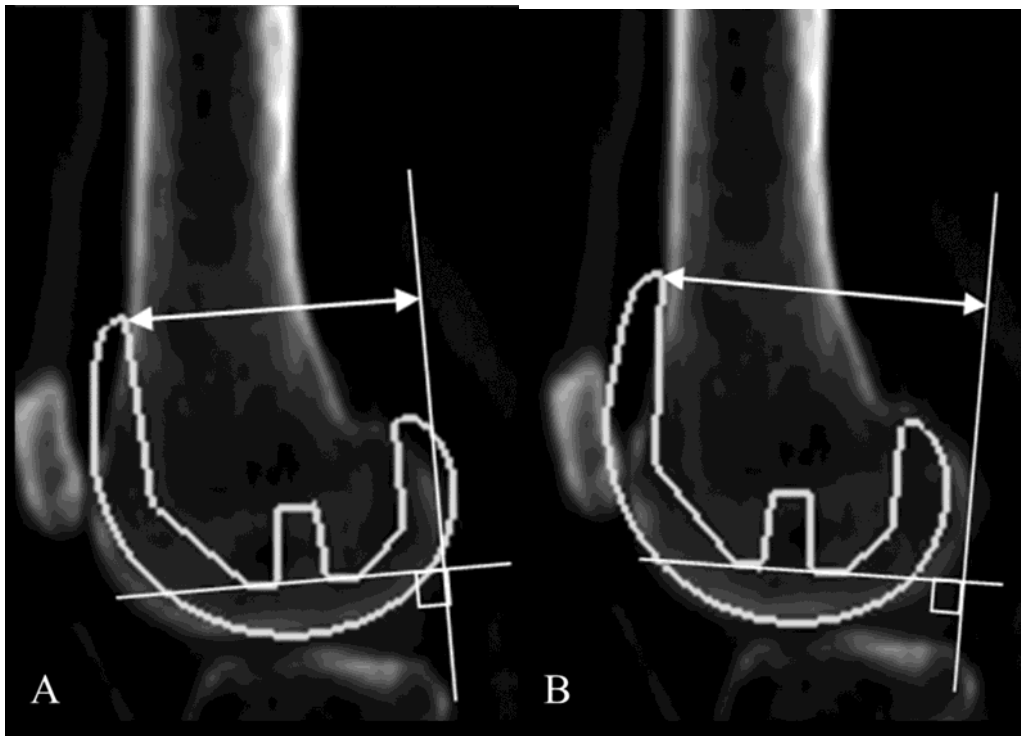


Fig. 4A-B

AU: Please do not delete query boxes or remove line numbers; ensure you address each query in the query box. You may modify text within selected text or outside the selected text (as appropriate) without deleting the query.

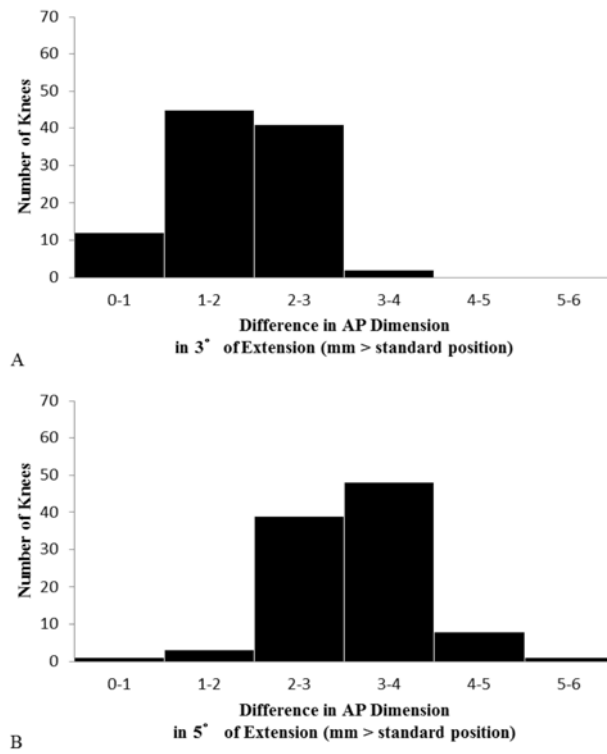


Fig. 5A-B

AU: Please do not delete query boxes or remove line numbers; ensure you address each query in the query box. You may modify text within selected text or outside the selected text (as appropriate) without deleting the query.

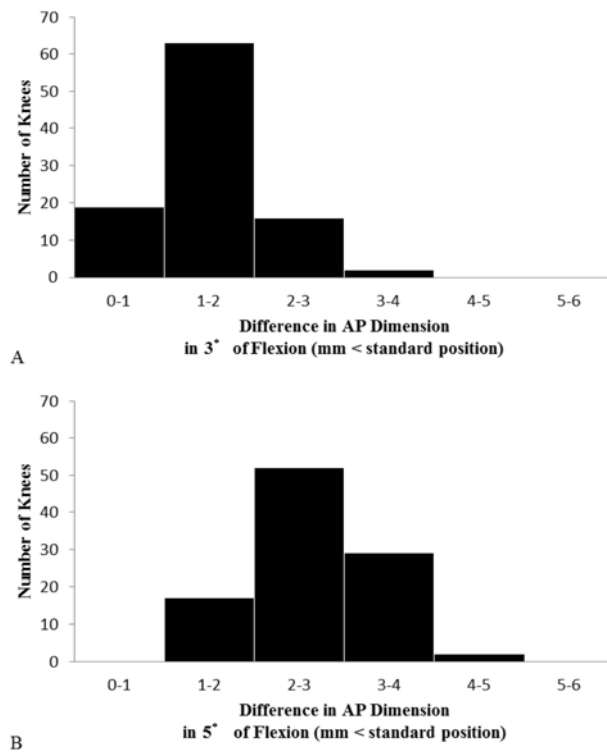


Fig. 6A-B

AU: Please do not delete query boxes or remove line numbers; ensure you address each query in the query box. You may modify text within selected text or outside the selected text (as appropriate) without deleting the query.

AU: Please do not delete query boxes or remove line numbers; ensure you address each query in the query box. You may modify text within selected text or outside the selected text (as appropriate) without deleting the query.