Successful Surgical Management for Duodenum Obstruction in a 66 Year-Old Woman Previously Undiagnosed Intestinal Malrotation

Motomura, Takashi
Department of Surgery, Matsuyama Red Cross Hospital | Department of Surgery and Science, Graduate School of Medical Sciences, Kyushu University

Takahashi, Ikuo
Department of Surgery, Matsuyama Red Cross Hospital

Noguchi, Shinichi
Department of Pediatric Surgery, Matsuyama Red Cross Hospital

Ochi, Tomohiro
Department of Surgery, Matsuyama Red Cross Hospital

他

https://doi.org/10.15017/1440937

出版情報：福岡醫學雜誌. 104 (12), pp.569-574, 2013-12-25. 福岡医学会
バージョン：
権利関係：

Successful Surgical Management for Duodenum Obstruction in a 66 Year-Old Woman Previously Undiagnosed Intestinal Malrotation

Takashi Motomura[1)3)], Ikuo Takahashi[1)], Shinichi Noguchi[2)], Tomohiro Ochi[1)], Yuichiro Kajiwara[1)], Yohei Mano[1)], Ryota Nakanishi[1)], Yoshihiko Fujinaka[1)], Kojiro Nishida[1)], Yo-ichi Yamashita[3)], Hiroshi Saeki[3)], Hirofumi Kawanaka[3)], Masaru Morita[3)], Tetsuo Ikeda[3)], Yuji Soejima[1)], Takashi Nishizaki[1)] and Yoshihiko Maehara[3)]

[1)]*Department of Surgery, Matsuyama Red Cross Hospital, Ehime, Japan*
[2)]*Department of Pediatric Surgery, Matsuyama Red Cross Hospital, Ehime, Japan*
[3)]*Department of Surgery and Science, Graduate School of Medical Sciences, Kyushu University, Fukuoka, Japan*

Abstract
Intestinal malrotation is a congenital abnormality and is rarely seen in the adulthood. Most adult cases would be classified to the non-rotation type with Ladd's band and Ladd procedure is the treatment of choice. A 66 year-old woman admitted to our hospital due to duodenum obstruction. Several tests revealed that she had intestinal malrotation previously undiagnosed. Operative findings showed the fusion of duodenum with jejunum by the incomplete Treitz ligament. There was no Ladd's band and the right colon was unfixed. Dissection of the fusion completely released her symptom and she discharged without any complication. This is the first report of untypically intestinal malrotation in the adulthood without Ladd's band.

Key words : Intestinal malrotation・Adult・Ladd's band

Introduction

Intestinal malrotation is a congenital abnormality usually diagnosed in childhood, especially under the age of one year. It has been estimated to occur in one in 500 live births[1)]. Approximately 85% of malrotation is diagnosed within the first two weeks of life[2)]. Most patients present bilious vomiting due to duodenal obstruction or midgut volvulus. Typically, this obstruction occurs by the abnormal ligament, the cause of fusion between the duodenum and the unfixed cecum, what is called "Ladd's band" [3)]. The standard treatment for intestinal malrotation is division of this Ladd's band and appendectomy, which was originally described by Ladd in 1936. In contrast to infant cases, however, intestinal malrotation often shows vague and intermittent abdominal symptoms in adult cases, which is often difficult to diagnose[4)].

In this article, we present a 66 year-old female patient of duodenum obstruction with previously undiagnosed intestinal malrotation.

A Case Report

A 66-year-old Japanese female was referred to our hospital complaining of vomiting after meal. She had history of chronic nephritis for the past 20 years but had no renal disorder. She had no history of previous laparotomy. Her symptom first appeared at her age of 64, but gastrointestin-

Abbreviations : GI ; gastrointestinal, CT ; computed tomography, POD ; post operative day

All correspondence and reprint requests to : Takashi Motomura, MD. Ph.D.
Department of Surgery, Matsuyama Red Cross Hospital, Ehime, 790-8524, Japan
Tel : +81-89-924-1111 Fax : +81-89-922-6892
E-mail : t-moto@surg2. med. kyushu-u. ac. jp

al (GI) endoscopic test showed no peptic ulcer or other gastric mucosal lesion, and the symptom disappeared in a few days after an observation. The second attack came upon her the next year. GI contrast study and computed tomography (CT) scan revealed that her whole colons were deviated to the left side of her abdomen, which suggested that she had intestinal malrotation. However, there was no finding of stenosis and only an oral intake of some enterokinetic drugs improved her symptom. Therefore, she was thought not to have an indication of any surgical treatment at that time. Three months later, she came again to our hospital with vomiting after meal and she could not eat anymore. She admitted to the department of gastroenterology on that day.

On admission, her vital signs were all within normal with body height of 136.4 cm and weight of 47.1 kg. Her blood cell count were ; white blood cell 6500/mm^3, hemoglobin 11.8 g/dl, and platelet count 172x10^3 /mm^3. Serum biochemistory test revealed that she was slightly dehydrated but had no liver function disorder nor renal dysfunction. CT scan at the time of this admission revealed duodenal obstruction and GI contrast study showed abnormal curvature at third portion of duodenum (Fig. 1A, B). A naso-gastric tube was inserted for decompression and she was transferred to our department of surgery.

Under satisfactory general anesthesia in a spine position, approximately 10 cm of midline skin incision was made for laparotomy. There was no finding of bowel necrosis. Ascending colon with cecum was not fixed at all and whole segments of colon were in the left side of the patients. In contrast, entire ileum was laid in the right side without any distension. Treitz ligament could not be found. The curvature between the second and the third portion of duodenum was abnormally flexed with some fibrous cord-like structure, and the upper side of her duodenum was distended (Fig. 2A, B). There was no Ladd's ligament because the cecum was completely free and placed around the left lower abdomen. The fusion of duodenum and the cord-like structure were dissected sharply. Then, the duodenum was placed in a linear fashion and fixed with retroperitoneum using 3-0 silk strings (Fig. 3A). Finally, the appendix was removed. Because the free ascending colon was not the cause of obstruction, ascending colon was not fixed as many previous reports had described. There was little bleeding during the operation. The abdominal wall was closed in layers and no drainage tube was placed. Operative time was 98 minutes.

Postoperative course was uneventful. She started to drink any liquid the next day of the operation and to eat meal on post-operative day (POD) 2. She never complained abdominal distention or vomiting even after meal. GI contrast study was performed on POD 7 and good outflow

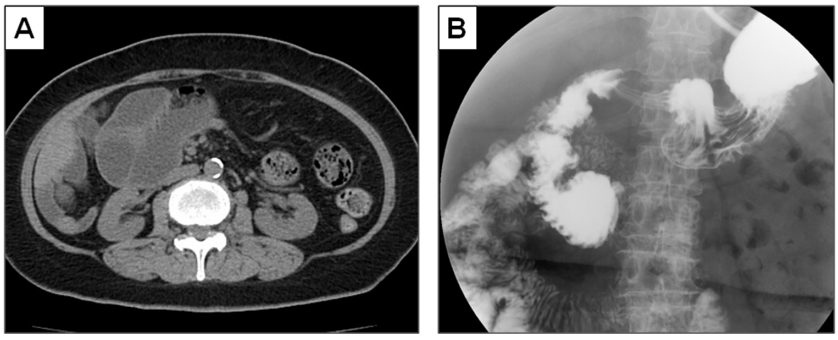

Fig. 1 Preoperative images suggested the duodenum obstruction and intestinal malrotation. (A) CT scan showed the significant dilatation of the duodenum and its sharp narrowing at the third portion. (B) GI contrast test revealed the right deviation of the whole small intestine.

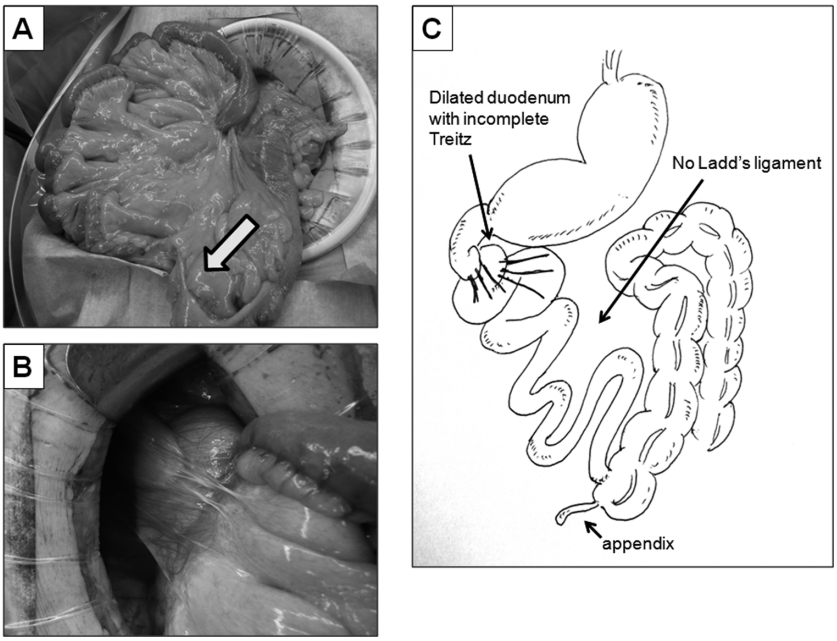

Fig. 2 Operative findings suggested the intestinal malrotation with unfixed right colon and incomplete Treitz ligament. (A) The whole small intestine was deviated to the right side. Instead, right colon was unfixed and the appendix was in the left lower quadrant (arrow). (B) Duodenum was surrounded with cord-like structures and bending. (C) Scheme of her abdomen.

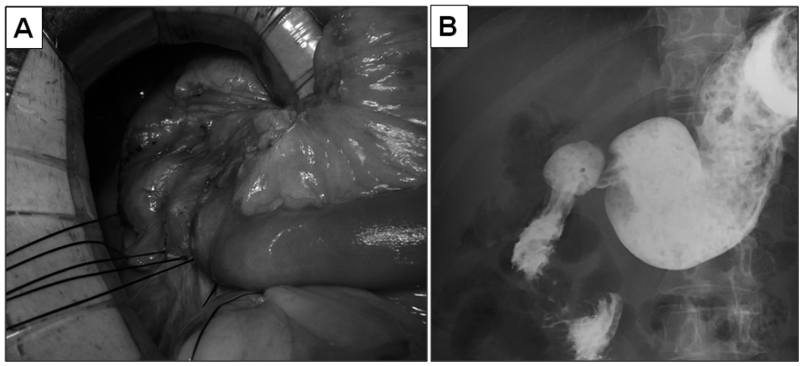

Fig. 3 The duodenum obstruction was open after operation. (A) Straightened and fixed duodenum with no obstruction. (B) GI contrast test on 7POD revealed linear duodenum and smooth flow of the contrast dye.

of the contrast dye from the duodenum was confirmed. She discharged on POD 11 without any complication.

Discussion

Intestinal malrotation in adults is a rare disease with incidence of between 0.00001% and 0.19% of population[3)5)]. In a literature review, only 40 cases were presented over the 70 years[3)]. More recently, 170 malrotation cases were surveyed from infancy through adulthood[4)], the mean age of which was 25 years old. The present case of a 66 year-old woman is really rare. The low incidence of the disease is one of the reasons that make the diagnosis difficult. However, the true incidence is uncertain because a part of the adult patients shows no symptom. Autopsy studies showed that some form of intestinal malrotation could be found even in 0.5% to 1% of population[6)]. It is probable that the disease will be more common with future developments in diagnostic imaging. Therefore, surgeons should be well-informed about this

congenital malformation.

Intestinal malrotation is defined as any deviation from the normal 270 degrees countercrockwise rotation of the midgut during the 6th to 12th weeks of embryologic development. Malrotation can be classified into "non-rotation" and "incomplete rotation" [7]. Of these, most cases in older population show non-rotation type, which includes malfixation of the mesentery[1]. Peritoneal bands that would normally extend to the right colon from the right paracolic gutter, persist in the right upper quadrant and transverse between duodenum and ileocecal junction, which is called "Ladd's band". This band tightens the duodenum and thus, is the cause of duodenum obstruction. In the present case, however, Ladd's band could not be found and right colon was completely unfixed with deviation to the left lower quadrant. Instead, incomplete Treitz ligament went across the descending portion of duodenum and jejunum. This abnormal cord-like structure was the cause of duodenum obstruction. To our knowledge, these abnormalities have never been reported so far.

Surgical intervention is undoubtedly the only choice for treatment of intestinal malrotation, although the management for asymptomatic cases still remains controversial[8]. In the present case, the symptom once recovered at the initial visit without any treatment and therefore, surgical intervention was not introduced at that time. Considering the operative findings, the cord-like structure did not obstruct the duodenum directly, but obstruction seemed to occur when the duodenum curled around this cord with the bowel peristalsis. That was thought to be the reason why she had been asymptomatic till the age of sixty-six. In the end, however, non-operative management did not remove her symptom completely but surgical intervention did. In addition, because her ileocecal junction was not fixed, making the diagnosis would be so difficult if she suffers appendicitis in future. We added prophylactic appendectomy in the same way as Ladd's procedure.

Recently, not a few reports showed laparoscopic repair for intestinal malrotation[9][10]. Laparoscopic surgery appears to be effective and feasible as open procedure for typical intestinal malrotation with Ladd's band. However, this case showed unusual clinical course and the cause of obstruction was not detected clearly, so that midline incision was chosen.

In conclusion, this is absolutely the rare case of intestinal malrotation in the adulthood without Ladd's band. General surgeons, not just the pediatric surgeons, should be well-informed about this problem and immediate surgical intervention will save the patients.

Acknowledgements

The authors of this manuscript have no funding source regards to this report.

References

1) Pickhardt PJ and Bhalla S : Intestinal malrotation in adolescents and adults : spectrum of clinical and imaging features. AJR Am J Roentgenol. 179 : 1429-1435, 2002.
2) Gamblin TC, Stephens RE Jr, Johnson RK and Rothwell M : Adult malrotation : a case report and review of the literature. Curr Surg. 60 : 517-520, 2003.
3) von Flüe M, Herzog U, Ackermann C, Tondelli P and Harder F : Acute and chronic presentation of intestinal nonrotation in adults. Dis Colon Rectum. 37 : 192-198, 1994.
4) Nehra D and Goldstein AM : Intestinal malrotation : varied clinical presentation from infancy through adulthood. Surgery. 149 : 386-393, 2011.
5) Wang CA and Welch CE : Anomalies of intestinal rotation in adolescents and adults. Surgery. 54 : 839-855, 1963.
6) Kapfer SA and Rappold JF : Intestinal malrotation-not just the pediatric surgeon's problem. J Am Coll Surg. 199 : 628-635, 2004.
7) Maxson RT, Franklin PA and Wagner CW : Malrotation in the older child : surgical management, treatment, and outcome. Am Surg. 61 : 135-138, 1995.
8) Emanuwa OF, Ayantunde AA and Davies TW : Midgut malrotation first presenting as acute

bowel obstruction in adulthood : a case report and literature review. World J Emerg Surg. 6 : 22, 2011.

9) Nakajima Y, Sakata H, Yamaguchi T, Yoshie N, Yamada T, Osako T, Terashima M, Mambo N, Saka R, Nose S, Sasaki T, Okuyama H, Nakao A and Kotani J : Successful treatment of a 14-year-old patient with intestinal malrotation with laparoscopic Ladd procedure : case report and literature review. World J Emerg Surg. 8 : 19, 2013.

10) Mazziotti MV, Stasberg SM and Langer JC : Intestinal rotation abnormalities without volvulusthe role of laparoscopy. J Am Coll Surg. 185 : 172-176, 1997.

(Received for publication October 21, 2013)

（和文抄録）

腸回転異常に伴う成人期初発の十二指腸閉塞の１例

[1)]松山赤十字病院　外科
[2)]松山赤十字病院　小児外科
[3)]九州大学大学院　消化器・総合外科

本村貴志[1)3)]，高橋郁雄[1)]，野口伸一[2)]，越智友洋[1)]，梶原勇一郎[1)]，間野洋平[1)]，中西良太[1)]，藤中良彦[1)]，西田康二郎[1)]，山下洋市[3)]，佐伯浩司[3)]，川中博文[3)]，森田　勝[3)]，池田哲夫[3)]，副島雄二[1)]，西﨑　隆[1)]，前原喜彦[3)]

【背景】腸回転異常は胎生期の先天性疾患であり，十二指腸閉塞や中腸軸捻転を契機に９割が乳児期に診断され，成人での発症は極めて稀である．また多くの場合十二指腸と回盲部がLadd靭帯と呼ばれる索状構造物によって癒着しており，これを切離する手術が標準治療となる．今回我々は，成人期に初めて診断された，Ladd靭帯を伴わない腸回転異常症に手術施行した１例を経験したので報告する．

【症例】66歳女性．食後の嘔吐を主訴に来院した．上部消化管内視鏡にて異常なく，CTにて十二指腸の拡張と水平脚での急峻な狭小化を認めた．消化管造影検査にて小腸の右側偏位を認め，腸回転異常が疑われた．保存的加療にて改善無く，手術の方針となった．腹部正中切開で開腹，十二指腸下降脚が索状物によって癒着し，同部位での十二指腸閉塞を認めた．Treitz靭帯を認めず，水平脚をほとんど形成せずに小腸は全て右方に偏位していた．また上行結腸は固定されておらず，回盲部を左側に認めた．癒着を剥離し，十二指腸を直線化した状態で後腹膜に固定した．予防的に虫垂切除して手術を終了した．術翌日より経口摂取開始したが，嘔気嘔吐なく，術後７日目での消化管造影検査でも，十二指腸からの良好な造影剤の流出を認めた．特に問題なく術後10日で退院となった．

【考案】極めて稀な腸回転異常の成人例を経験した．本症例ではTreitz靭帯の形成不全による癒着が原因で，腸蠕動によって索状物に十二指腸が陥入して初めて腸閉塞症状を発症したことが，発症の遅れにつながったと考えられる．腸回転異常の根治は手術以外になく，十二指腸閉塞症状を来した症例では本疾患を念頭に診断を進める事が，早期に患者のQOL改善につながると考えられる．