

Large Simple Hepatic Cysts Leading to Gastric Fundal Varices in a Noncirrhotic Patient

Kinjo, Nao
Department of Surgery, Steel Memorial Yahata Hospital

Yano, Hiroko
Department of Surgery, Steel Memorial Yahata Hospital

Sugimachi, Keishi
Department of Surgery, Steel Memorial Yahata Hospital | Department of Surgery, Kyushu University Beppu Hospital

Tanaka, Junko
Department of Surgery, Steel Memorial Yahata Hospital

他

<https://doi.org/10.15017/1430779>

出版情報：福岡醫學雜誌. 104 (11), pp.449-455, 2013-11-25. 福岡医学会
バージョン：
権利関係：

Large Simple Hepatic Cysts Leading to Gastric Fundal Varices in a Noncirrhotic Patient

Nao KINJO¹⁾, Hiroko YANO¹⁾, Keishi SUGIMACHI¹⁾²⁾, Junko TANAKA¹⁾, Kiyoshi TANAKA¹⁾, Hiroshi SAEKI³⁾, Shuichi TSUKAMOTO¹⁾, Koshi MIMORI²⁾, Hirofumi KAWANAKA³⁾, Masahiko IKEBE¹⁾, Masaru MORITA³⁾, Tetsuo IKEDA³⁾, Shinsuke MII¹⁾, Hidefumi HIGASHI¹⁾ and Yoshihiko MAEHARA³⁾

¹⁾Department of Surgery, Steel Memorial Yahata Hospital, Kitakyushu, Fukuoka

²⁾Department of Surgery, Kyushu University Beppu Hospital, Beppu, Oita and

³⁾Department of Surgery and Science, Graduate School of Medical Sciences, Kyushu University, Fukuoka, Fukuoka

Abstract

A 74-year-old noncirrhotic woman presented with abdominal distension and pain in the right hypochondrium. Contrast-enhanced computed tomography (CT) demonstrated multiple large simple liver cysts occupying the right lobe of the liver, the largest of which was 19 cm in diameter. Gastric varices were enhanced in the fundus of the stomach. The patient underwent surgery to derooft the hepatic cysts with ablation using argon beam coagulation. Esophagogastroduodenoscopy (EGD) showed that the portal hypertensive gastropathy was ameliorated after the operation; however, the fundal varices were only slightly decreased. After the operation, we observed that the hepatic vein waveform gradually changed from a gently curved pattern to a normal triphasic pattern. We treated the fundal varices with balloon-occluded retrograde transvenous obliteration 3 months after the initial operation. We describe our successful treatment of this rare case and discuss the utility of hepatic vein waveform analysis in the study of portal hypertension.

Key words : Liver cyst · Gastric varices · Hepatic vein waveform · Noncirrhotic

Introduction

Simple hepatic cysts are a common and typically benign disease. Most simple hepatic cysts are asymptomatic and do not require intervention. Only about 16% of cysts are symptomatic¹⁾, with symptoms relating to the size and location of the cyst; abdominal pain or distension are the most frequent complaints, present in more than 50% of symptomatic patients²⁾. In giant congenital liver cysts, there may be compression of adjacent structures, resulting in jaundice, portal hypertension, gallstones, biliary stones, or more serious complications such as esophageal varices, ascites, or liver failure³⁾. However, these complications are rare in

actuality.

We present a rare case of multiple large simple hepatic cysts leading to gastric fundal varices in a noncirrhotic patient; we surgically deroofted the hepatic cysts and performed balloon-occluded retrograde transvenous obliteration with good results. In addition, we report the utility of hepatic vein waveform analysis in the study of portal hypertension.

Case

A 74-year-old woman presented with abdominal distension and pain in the right hypochondrium in January 2012. She had previously been ultrasonographically diagnosed with multiple simple hepatic cysts not associated with any symptoms.

Corresponding Author : Nao KINJO, M.D., Ph.D.

Department of Surgery, Steel Memorial Yahata Hospital, 1-1-1, Harunomachi, Yahata-higashi-ku, Kitakyushu, Fukuoka, 805-8508, Japan

Tel : (office) 81-93-672-3176 Fax : (office) 81-93-671-9605

E-mail : kinjokun@ga2.so-net.ne.jp

On presentation, contrast-enhanced computed tomography (CT) demonstrated multiple large simple liver cysts occupying the right lobe of the liver, the largest of which was 19 cm in diameter (Fig. 1A); of the hepatic parenchyma in the right lobe, only segment 6 remained. The right portal branch, right hepatic vein, and middle hepatic vein were not recognizable on CT because of the huge liver cysts. The left hepatic vein was narrowed by the cysts at the confluence into the inferior vena cava (Fig. 1B, 1C). Gastric fundal varices were enhanced in the stomach.

Esophagogastroduodenoscopy (EGD) showed tumorous gastric varices at the gastric fundus with a snakeskin appearance of the gastric mucosa (Fig. 2A, 2B, 2C). Serum albumin was 3.8 g/dl, total bilirubin was 1.3 mg/dl, prothrombin time (PT-INR) was 1.12, and the platelet count was $158.0 \times 10^3/\text{ul}$. Aspartate aminotransferase

(AST) and alanine aminotransferase (ALT) were within the normal range. Neither hepatitis B nor hepatitis C virus was detected in the serum.

Duplex Doppler ultrasonography showed a regular hepatopetal waveform of the left portal branch; however, the waveform of the left hepatic vein showed a gently curved pattern in harmony with the expiratory and inspiratory phases of respiration. This waveform pattern differed from the typical hepatic vein waveform patterns classified by Bolondi et al.⁴⁾ and Ohta et al.⁵⁾

At this time, the cysts were causing abdominal pain and necessitated surgical treatment. In February 2012, the patient underwent surgical deroofting of the hepatic cysts with ablation using argon beam coagulation. The gastric fundal varices were not treated in this first operation. The patient's postoperative clinical course was uneventful, and she was discharged on the 14th

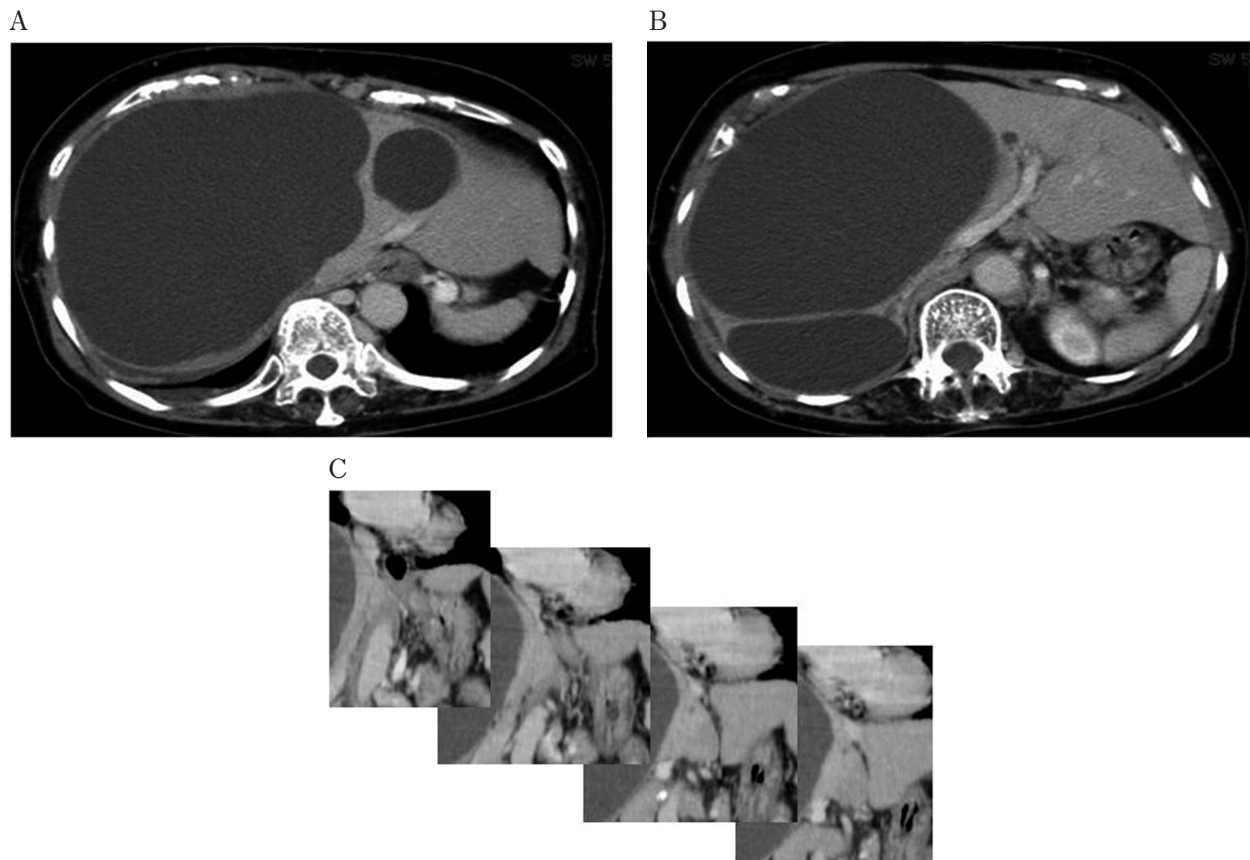


Fig. 1 Contrast-enhanced computed tomography demonstrates large hepatic cysts occupying the right lobe of the liver, the largest of which was 19 cm in diameter (Fig. 1A). Of the hepatic parenchyma in the right lobe, only segment 6 remained. The right portal branch, right hepatic vein, and middle hepatic vein were not recognizable because of the hepatic cysts.

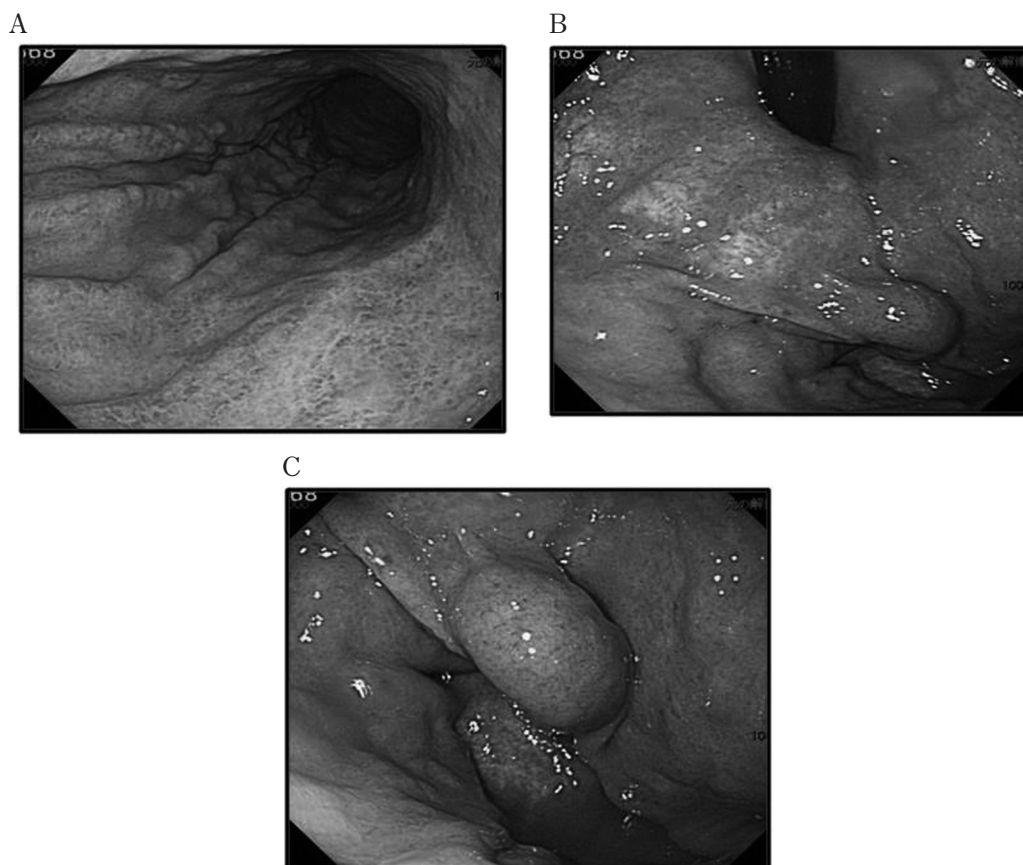


Fig. 2 Esophagogastroduodenoscopy (EGD) images show tumorous gastric varices at the gastric fundus with a snakeskin appearance of the gastric mucosa (Fig. 2).

postoperative day. Histopathological examination did not demonstrate fibrosis, dilatation of the sinusoids, or venous congestion in the pieces of liver tissue obtained during the operation.

After the operation, the hepatic vein waveform changed from the preoperative gently curved pattern (Fig. 3A) to a monophasic pattern (3 days after the operation, Fig. 3B), then to a biphasic pattern (7 days after the operation, Fig. 3C), and finally to a normal triphasic pattern (1 month after the operation, Fig. 3D).

At 2 months after the operation, CT showed that the volume of hepatic parenchyma had increased after removal of the liver cysts. The left and right branches of the portal vein as well as the left hepatic vein were clearly recognizable and without narrowing. We had performed EGD monthly after the surgery. EGD demonstrated disappearance of the snakeskin appearance of the gastric mucosa and amelioration of the portal

hypertensive gastropathy (Fig. 4A). However, the gastric fundal varices had been only slightly decreased in size without its tension (Fig. 4B).

Balloon-occluded retrograde transvenous obliteration (B-RTO) was performed prophylactically in May 2012 for the varices because of its potential fatal bleeding. Shunt occlusion was achieved by inflation of the balloon. After a test injection of iopamidol, 20 cc of 50% glucose and 18 cc of 5% ethanolamine oleate iopamidol (EOI) were injected to obliterate the gastric varices and their drainage vessels. The varices were completely obliterated without any complications and did not recur during a follow-up period of 9 months.

Discussion

Simple hepatic cysts represent a type of congenital liver disease affecting 2.5-7% of the population^(6,7). Polycystic liver disease and Calori disease, diseases involving hepatic cysts accompa-

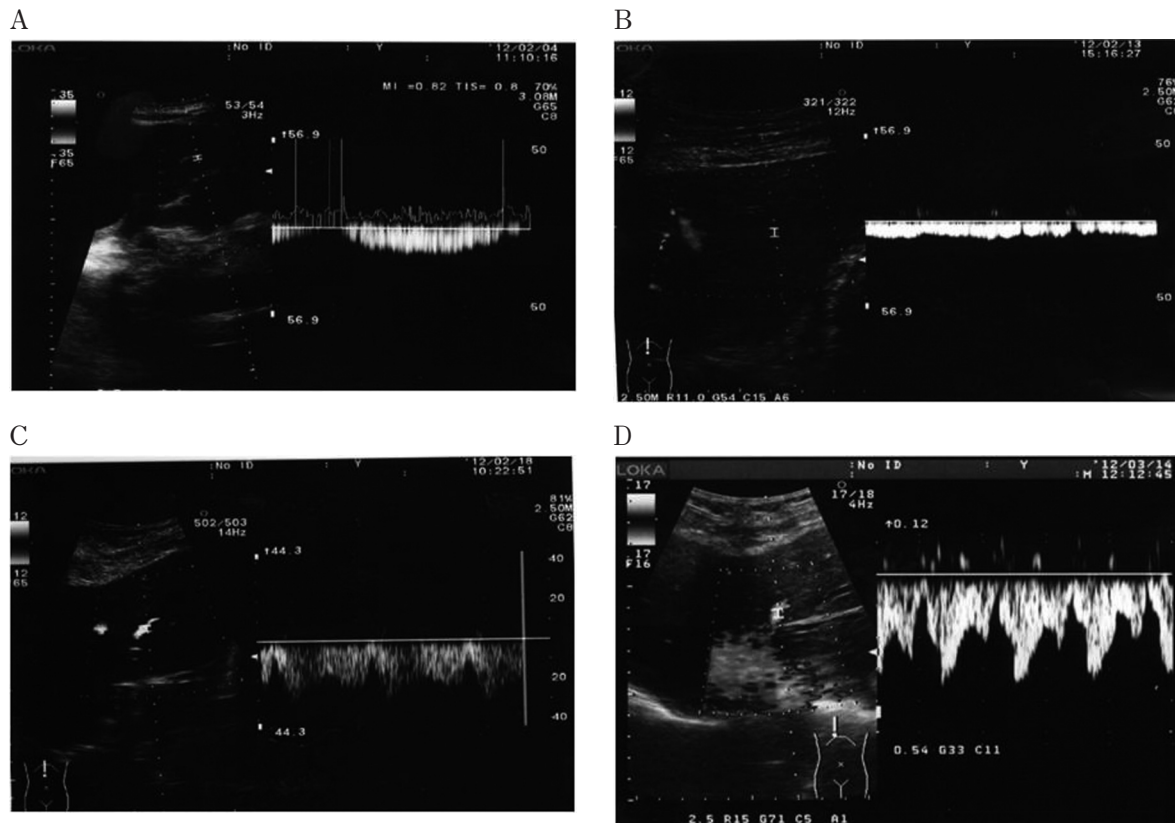


Fig. 3 The hepatic vein waveform changed from a gently curved pattern (pre-operation, Fig. 3A) to a monophasic pattern (3 days after the operation, Fig. 3B), then to a biphasic pattern (7 days after the operation, Fig. 3C), and finally to a normal triphasic pattern (1 month after the operation, Fig. 3D).

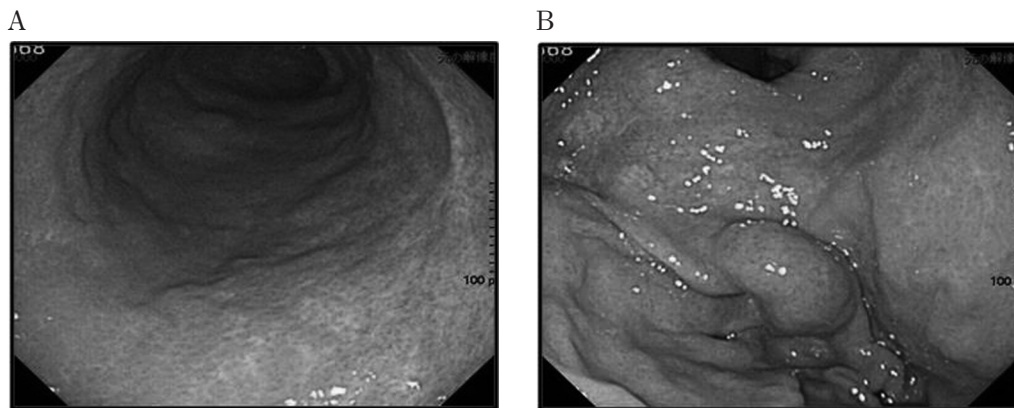


Fig. 4 EGD images demonstrate disappearance of the snakeskin appearance and amelioration of the portal hypertensive gastropathy (Fig. 4A); however, the gastric varices were not significantly altered in size (Fig. 4B).

nied by liver fibrosis, can occasionally cause hepatic failure or clinical complications of portal hypertension⁸⁾⁹⁾. Previous reports have demonstrated that portal hypertension and jaundice in hepatic cyst-associated diseases result not only from the size and location of the cyst but also from hepatic fibrosis, which increases intrahepatic resistance, leading to portal hypertension and

complications such as esophagogastric varices. However, in cases of simple hepatic cysts, hepatic fibrosis is rare. Our case is unusual in that multiple large simple hepatic cysts caused intrahepatic and extrahepatic resistance in this patient, resulting in portal hypertension and esophagogastric varices.

Hepatic vein waveform (HVWF) analysis has

been reported to be a non-invasive method of assessing of liver impairment⁴⁾⁵⁾¹⁰⁾. In healthy patients, the hepatic vein Doppler waveform is a triphasic waveform (two negative waves and one positive wave). This waveform mirrors the cardiac cycle, as the hepatic blood flow is directed toward the heart during atrial and ventricular diastole and is then briefly reversed during atrial systole. The hepatic vein Doppler waveform has been documented to change in relation to the severity of cirrhosis : the pulsatility of the hepatic vein decreases and eventually becomes a flat wave in proportion to the severity of cirrhosis¹⁰⁾¹¹⁾. Ohta et al. demonstrated that the hepatic vein waveform is indicative of outflow block of the hepatic vein in liver transplant patients and patients with Budd Chiari syndrome⁵⁾. Hepatic vein waveform type IV, a flat waveform with fluttering, is evident in cases of advanced liver cirrhosis or stricture of the hepatic vein.

It has been suggested that huge hepatic cysts might themselves obstruct hepatic blood flow in accordance with respiration. In this case, Doppler ultrasound demonstrated that the left hepatic vein waveform was a gently curved pattern in harmony with the expiratory and inspiratory phases of respiration. This waveform pattern differs from the hepatic vein waveform pattern typically observed in cirrhotic patients⁴⁾⁵⁾. Computed tomography demonstrated that our patient's right and middle hepatic veins were not recognizable before the operation and that the cysts were causing obstructions both at the confluence of the inferior vena cava and at the left hepatic vein itself. Therefore, it is possible that this case might represent a type of Budd Chiari syndrome.

The portal hypertension in this case was suspected to be caused not only by extrahepatic obstruction, but also by increased intrahepatic resistance due to decreased hepatic parenchyma and the replacement of the intrahepatic vascular bed by the huge hepatic cysts. The regenerated

liver volume and increased intrahepatic vascular bed after the cyst removal operation may have been responsible for ameliorating the intrahepatic resistance.

In this case, we did not treat the gastric varices in the first operation for two reasons. First, we considered it possible that liver regeneration after derooftment of the huge hepatic cysts might reduce or eradicate the gastric fundal varices. Some reports have demonstrated esophageal varices to be reduced in size or eradicated after liver transplantation in cirrhotic patients because intrahepatic resistance decreased after replacement by normal liver, increasing hepatopetal blood flow in the portal vein and decreasing blood flow via collateral vessels¹²⁾¹³⁾. We expected that if the hepatic cysts were causing the majority of the increased intrahepatic and extrahepatic resistance (leading to portal hypertension), deroofting the cysts and allowing the liver to regenerate could decrease this intrahepatic and extrahepatic resistance ; potentially, gastric varices could be reduced or eradicated in the same manner as in the post-liver transplant cirrhotic patients. However, although portal hypertension appeared to improve to the point of causing the snakeskin appearance of the gastric mucosa to resolve after cyst removal, the gastric fundal varices only slightly decreased in size, necessitating eventual treatment with B-RTO.

Our second reason for not addressing the gastric varices in the first operation was that they had a simple drainage vessel that we could use for subsequent balloon-occluded retrograde transvenous obliteration (B-RTO) via the right femoral vein. This enabled us to perform B-RTO at a later time without any complications.

In conclusion, we treated a rare case of gastric fundal varices due to large simple hepatic cysts in an otherwise normal liver. Hepatic vein waveform analysis was useful for understanding blood flow dynamics in this case and is a feasible, applicable, and valuable modality in the study of portal hypertension.

References

- 1) Caremani M, Vincenti A, Benci A, Sassoli S and Tacconi D : Ecographic epidemiology of non-parasitic hepatic cysts. *J Clin Ultrasound.* ; 21 : 115-118, 1993.
- 2) Klotz HP, Schlumpf R, Weder W and Largiadèr F : Minimal invasive surgery for treatment of enlarged symptomatic liver cysts. *Surg Laparosc Endosc.* ; 3 : 351-353, 1993.
- 3) Hodgson WJ, Kuczabski GK and Malhotra R : Laparoscopic management of cystic disease of the liver. *Surg Endosc.* ; 12 : 46-49, 1998.
- 4) Bolondi L, Li Bassi S, Gaiani S, Zironi G, Benzi G, Santi V and Barbara L : Liver cirrhosis : changes of Doppler waveform of hepatic veins. *Radiology.* 1991 178 : 513-516. Erratum in : *Radiology* ; 100 : 586, 1991.
- 5) Ohta M, Hashizume M, Kawanaka H, Akazawa K, Tomikawa M, Higashi H, Kishihara F, Tanoue K and Sugimachi K : Prognostic significance of hepatic vein waveform by Doppler ultrasonography in cirrhotic patients with portal hypertension. *Am J Gastroenterol.* ; 90 : 1853-1857, 1995.
- 6) Cowles RA and Mulholland MW : Solitary hepatic cysts. *J Am Coll Surg.* ; 191 : 311-321, 2000.
- 7) Gamblin TC, Holloway SE, Heckman JT and Geller DA : Laparoscopic resection of benign hepatic cysts : a new standard. *J Am Coll Surg.* ; 207 : 731-736, 2008.
- 8) Bistriz L, Tamboli C, Bigam D and Bain VG : Polycystic liver disease : experience at a teaching hospital. *Am J Gastroenterol.* ; 100 : 2212-2217, 2005.
- 9) Brancatelli G, Federle MP, Vilgrain V, Vullierme MP, Marin D and Lagalla R. : Fibropolycystic liver disease : CT and MR imaging findings. *Radiographics.* ; 25 : 659-670, 2005.
- 10) Kawanaka H, Kinjo N, Anegawa G, Yoshida D, Migoh S, Konishi K, Ohta M, Yamaguchi S, Tomikawa M, Hashizume M and Maehara Y : Abnormality of the hepatic vein waveforms in cirrhotic patients with portal hypertension and its prognostic implications. *J Gastroenterol Hepatol.* ; 23 (7 Pt 2) : e129-136, 2008.
- 11) Baik SK, Kim JW, Kim HS, Kwon SO, Kim YJ, Park JW, Kim SH, Chang SJ, Lee DK, Han KH, Um SH and Lee SS : Recent variceal bleeding : Doppler US hepatic vein waveform in assessment of severity of portal hypertension and vasoactive drug response. *Radiology.* ; 240 : 574-580, 2006.
- 12) Kawaoka T, Takahashi S, Aikata H, Azakami T, Saneto H, Takaki S, Jeong SC, Asahara T, Ito K and Chayama K : Beneficial effects of living-donor liver transplantation on esophageal varices. *J Gastroenterol.* ; 43 : 982-989, 2008.
- 13) Jiang SM, Zhang QS, Zhou GW, Huang SF, Lu HM and Peng CH : Differences in portal hemodynamics between whole liver transplantation and living donor liver transplantation. *Liver Transpl.* ; 16 : 1236-1241, 2010.

(Received for publication October 2, 2013)

(和文抄録)

巨大肝嚢胞が原因と思われた正常肝における胃静脈瘤の1例

¹⁾製鉄記念八幡病院外科

²⁾九州大学病院別府病院外科

³⁾九州大学消化器・総合外科

金城 直¹⁾, 矢野博子¹⁾, 杉町圭史¹⁾²⁾, 田中 旬子¹⁾, 田中 潔¹⁾, 佐伯浩司³⁾,
塚本修一¹⁾, 三森功士²⁾, 川中博文³⁾, 池部正彦¹⁾, 森田 勝³⁾, 池田哲夫³⁾,
三井信介¹⁾, 東 秀史¹⁾, 前原喜彦³⁾

患者は、74歳女性で、右側部痛を主訴に来院、腹部造影CTにて、巨大な多発肝嚢胞（最大径19cm）を認め、肝右葉の大部分を占めていた。また同時に胃静脈瘤（穹窿部）を認めた。肝嚢胞に対して、開窓術+APCによる焼灼術を施行した。上部消化管内視鏡検査では、門脈圧亢進症性胃症の改善は認めるものの、胃静脈瘤の形態的な縮小は軽度であった。肝静脈波型は、吸気呼気に一致したなだらかなカーブパターンから、I型まで変化し、正常化した。最終的には胃静脈瘤に対して、B-RTOを施行し、胃静脈瘤は消失した。非肝硬変患者の多発する巨大肝嚢胞による胃静脈瘤の1治療例を報告し、同時に門脈圧亢進症研究における肝静脈波型の有用性に関して、報告する。